

# Reconstruction of cranial defect with patient-specific implants: Four different cost-effective techniques

### ABSTRACT

Cranial defects secondary to trauma, surgery or pathological causes, result in large cranial imperfection, which affects the appearance of the patient as well as results in sinking flap syndrome. Rehabilitation of such a defect can be done using prosthetic options like custom-made polymethyl methacrylate (PMMA) cranial prosthesis or surgical options like outer table calvarial graft segments. It is usually observed that the conventional moulage impression of the defective site is the most difficult task. The accuracy of the prosthesis is affected by conventional moulage impression, a moulage cast of the defect and techniques of fabricating wax pattern. Orthodox method is to mark the tentative outline of the defect and make a conventional moulage impression of the site. However, this is an arbitrary method which offers challenges to accurate replication of the borders of the defect. Recently, medical imaging and digital modeling in dentistry have paved the way for digital dental practice and additive manufacturing replacing most manual or subtractive procedures. The use of computerized tomography scan to obtain a 3 D digital image of cranial defect for fabricating a replica with rapid prototyping has markedly improved the accuracy at the margin of the defect/prosthesis interface, resulting in a better fit and optimal contour lending itself to the improved esthetic outcome. It is a more reliable method of fabricating a cranial implant prosthesis, which requires minimum adjustment when the patient is on the OT table. These case reports compare rehabilitation of cranial defect with custom-made PMMA cranial prosthesis using the conventional methods as well as rapid prototyping technique. It is seen that the rapid prototyping method is expensive but accurate and gives a better esthetic outcome.

**Keywords:** Conventional, cranioplasty, polymethyl methacrylate, rapid prototyping, rehabilitation

### INTRODUCTION

Defects involving the maxillofacial structures are always a challenge for the patient and the doctor.<sup>[1]</sup> Surgeons struggle to minimize the defect to reduce physical and esthetic effects of the surgery and the Prosthodontist pursues to rehabilitate the defect with the prosthetic options.

Cranial defects may occur secondary to surgery usually to correct a pathology, infection, or due to trauma.<sup>[2-4]</sup> This usually results in a large defect in the cranial vault when more than one bone of the vault is involved. Such defects transform the closed cranial vault into an open compartment and a series of changes follow. Atmospheric pressure and gravity directly affect the intracranial contents resulting in neurological, cognitive, sensorimotor, and neurological symptoms, which are collectively called sinking skin flap syndrome.<sup>[4-6]</sup> Moreover, the large osseous defects cause an unesthetic appearance which eventually affects patient's


quality of life.<sup>[7]</sup> Hence, the prosthetic aim of rehabilitation is restoring the protective barrier for the underlying cerebral tissue, restore cerebral blood flow and improve the esthetic appearance.<sup>[8]</sup> Since 3000BC, cranioplasty was part of neurosurgical procedures and various materials were tried and tested for the same, which included coconut shells,

**DUSHYANT CHAUHAN, PROBODH KUMAR CHATTOPADHYAY<sup>1</sup>,  
ASHISH THAKUR**

Departments of Prosthodontic and Crown and Bridge and  
<sup>1</sup>Oral and Maxillofacial Surgery, Army Dental Center R and R,  
Delhi Cantt, New Delhi, India

**Address for correspondence:** Dr. Dushyant Chauhan,  
Department of Prosthodontic and Crown and Bridge, Army  
Dental Center R and R Delhi Cantt - 110 010, New Delhi, India.  
E-mail: dushyant.chauhan16@gmail.com

**Received:** 20 September 2020, **Revised:** 24 December 2020,  
**Accepted:** 04 April 2021, **Published:** 20 April 2022

Access this article online	
<b>Website:</b> www.njms.in	<b>Quick Response Code</b> 
<b>DOI:</b> 10.4103/njms.NJMS_200_20	

This is an open access journal, and articles are distributed under the terms of the Creative Commons Attribution-NonCommercial-ShareAlike 4.0 License, which allows others to remix, tweak, and build upon the work non-commercially, as long as appropriate credit is given and the new creations are licensed under the identical terms.

**For reprints contact:** WKHLRPMedknow\_reprints@wolterskluwer.com

**How to cite this article:** Chauhan D, Chattopadhyay PK, Thakur A. Reconstruction of cranial defect with patient-specific implants: Four different cost-effective techniques. *Natl J Maxillofac Surg* 2022;13:136-42.

bone grafts, metals, and biosynthetic materials.<sup>[9,10]</sup> In recent times two most commonly used alloplastic materials include titanium and polymethyl methacrylate (PMMA). However, fabricating a customized alloplastic graft is a challenge due to the cruciality of the site and the complexity of the defect site. Hence, preoperative fabrication of graft has numerous advantages and benefits.

The biggest challenges in fabricating a cranial graft are the identification of bony borders of the defect. Conventionally, moulage impression of the defect site is made to acquire a moulage cast of the defect, which is comparatively inaccurate as the defect is marked by direct palpation of the defect's edge and recorded from the surface. In recent times, computerized tomography (CT) scans have been used to create a 3D replica of the defect. The present case series includes four cases, in which rehabilitation of large craniofacial defect was performed. The cranial prosthesis used to rehabilitate these defects were fabricated using different techniques and a combination of materials. All the cases showed excellent esthetic outcomes and subsequently favorable neurological results.

## CASE REPORT

### Case 1

A 37-year-old male patient was referred from the Department of Neurosurgery for fabrication of cranial prosthesis for fronto-parito-temporo-occipital defect of the left side [Figure 1]. History revealed that the patient had a fall and craniotomy was performed 14 months before the initial consultation. This case was managed following a conventional technique. The patient was asked to shave his head so that the complete extent of the defect could be visualized. Then the bony margins of the defect were gently palpated and marked using indelible pencil (APSARA Violet/Lilac indelible pencil). First, the inner margin of the defect was marked and then the outer margin was marked. The area in between the marks represented the extent to which the bevel of the final prosthesis could extend. For the conventional moulage impression, a cardboard was cut out to fit the vault to limit the flow of impression material. Then conventional moulage impression was made using irreversible hydrocolloid with altered water powder ratio to have a more fluid mix (50% more water than for intra-oral impression). Conventional moulage impression was poured and dental stone cast obtained which had marking of the defect. Scoring of the margins was done within the boundaries of the two markings and additional plaster added to restore the contour of the vault [Figure 2]. Then, multi-utility wax was adapted and contoured keeping

the unilateral side as reference. The thickness of the wax pattern was kept at approx. 3 mm and when near-perfect contour was achieved, a wax trial was done to evaluate future esthetics [Figure 3]. The wax pattern was invested in a special flask in a conventional way. Dewaxing was done and clear heat cure PMMA was packed and cured in conventional manner. Polymerized clear PMMA prosthesis was retrieved, finished, and polished. Holes were drilled at 2 mm distance from each other and prosthesis was sterilized. The prosthesis was surgically secured at the defect site using mini plates and screws [Figure 4]. Prosthesis rehabilitated the near-original contour of the vault and thus restored the esthetics of the patient [Figure 5].

### Case 2

A 25-year-old male patient was referred from the Department of Neurosurgery with defect in the fronto-parito-temporal region secondary to trauma that happened 01 year before being seen for a consultation. Since the patient was young and the defect was in the frontal region, it was planned to reinforce the PMMA cranial prosthesis. The patient was asked to shave his head and the bony margins of the defect were marked and the conventional moulage impression was made in irreversible hydrocolloid reinforced with plaster [Figure 6]. Cast was poured in dental stone and scored. Then, wax pattern was fabricated as per the contralateral contour and tried. Then to reinforce the prosthesis, prefabricated titanium mesh was contoured to the shape of wax pattern. Wax pattern was invested and dewaxed conventionally. Then, once the mold was available for packing, auto polymerizing clear PMMA was used to stabilize the contoured titanium mesh. Heat polymerizing clear acrylic was packed in the rest of the mold and processed conventionally. The polymerized prosthesis was finished, polished and then holes were drilled into the finished cranial prosthesis [Figure 7]. It was sterilized and screwed in placed

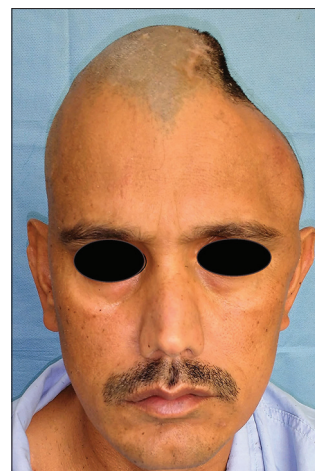


Figure 1: Preoperative frontal view of the defect

with mini-screws and plate surgically. The patient was seen 6 months postoperative and was noted to have an acceptable rehabilitation of the defect [Figure 8]. However, the only drawback was the scar mark on the forehead.

**Case 3**

A 18-year-old female patient was referred from the Department of Neurosurgery for fabrication of cranial prosthesis. The patient was diagnosed with eosinophilic granuloma of the frontal bone of the left side 4 years before the consultation and operated for the same. Reconstruction

of the defect was done with Biopore or (High-Density Porous Polyethylene) at the time of initial surgery. Since the Biopore has shape memory, the graft was ill-contoured, it affected the appearance of the patient. Since the graft obscured the margins of the defect, hence it was not possible to make

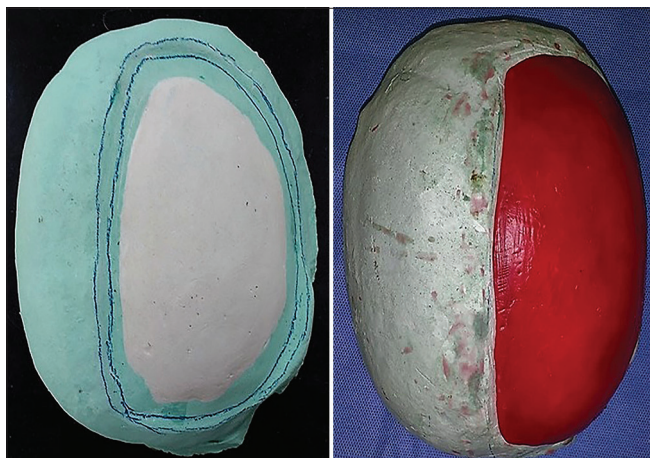

Figure 2: Final cast and wax pattern

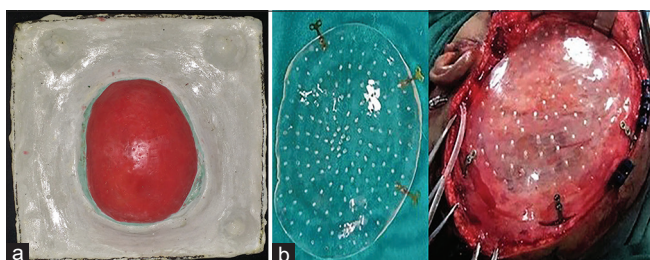


Figure 4: (a) Processing of polymethyl methacrylate prosthesis conventionally. (b) Finished prosthesis and surgical placement of prosthesis

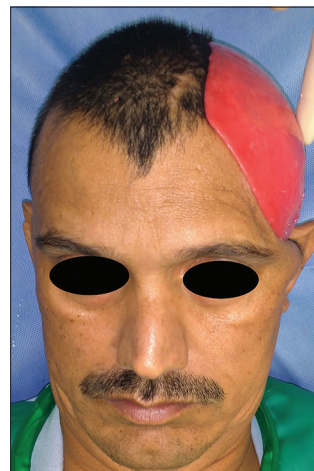

Figure 3: Wax patter trial

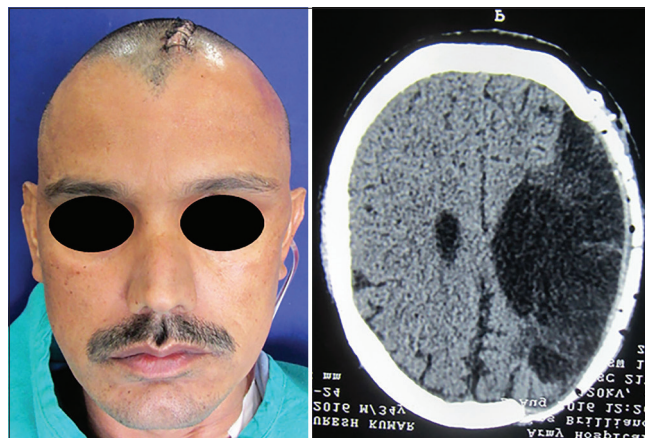

Figure 5: Final result after 3 weeks

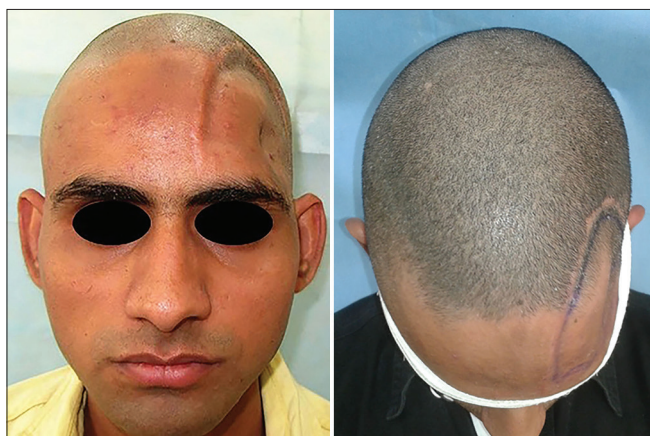

Figure 6: Preoperative view of case II

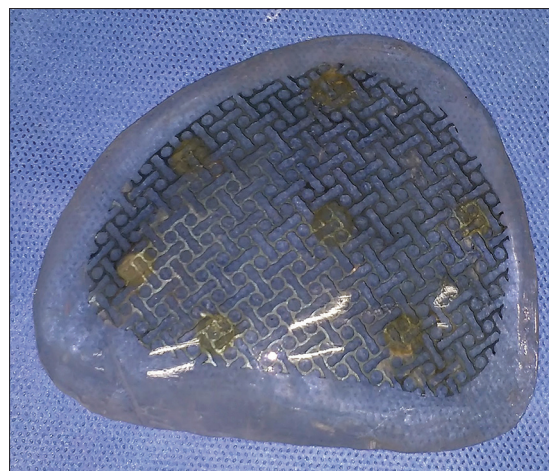

Figure 7: Final prosthesis with titanium mesh incorporated

conventional moulage impression of the defect [Figure 9]. To overcome the limitation, it was planned to fabricate a 3D replica of the defect. A CT scan of the defect was obtained with slice thickness of 1 mm and it was used to reconstruct a 3D image of the defect. Then, the dicom data was converted to STL format and 3D printing was done [Figure 10]. The complete vault was printed in polylactic acid. Using this 3D printed model, wax pattern was fabricated as per the contralateral side. Since the pattern was fabricated on the 3D model, hence it did not require a trial. The wax pattern was invested and processed in a conventional way. The graft made in clear heat cure PMMA was finished and polished before drilling holes into it. During the surgical phase, the existing Biopore graft was removed and PMMA graft screwed in place with mini plates and screws [Figure 11]. The patient was reviewed after 3 wks to observe a favorable profile of graft and an esthetic outcome of the case [Figure 12].

#### Case 4

A 74-year-old bedridden female patient was referred from the Department of Neurosurgery for the fabrication of the

cranial plate. The patient was operated for decompression craniotomy 6 months before initial consultation and had severe edema of the affected side. On examination, the defect was fronto temporo parieto occipital. On palpation, there was edematous swelling on the site obscuring the bony margins. Since the margins could not be clearly defined and the patient was bedridden, hence a conventional moulage impression technique of the defect could not be carried out. A 3D printed model was planned for the case and CT scan of the defect was performed with slice thickness of 1 mm. The data was used to fabricate a 3D digital replica of the defect [Figure 13]. The data were then used to fabricate a model using stereolithographic technique using polylactic acid. A digital model of restoration of the defect was also attempted using the digital mirroring technique of the contralateral side. This restoration was then 3D printed using the same technique [Figure 14]. The model and reconstruction of the defect were then combined to observe the contour of the complete vault. Needed modification required were then carried using multi-utility wax. The pattern was invested directly and processed

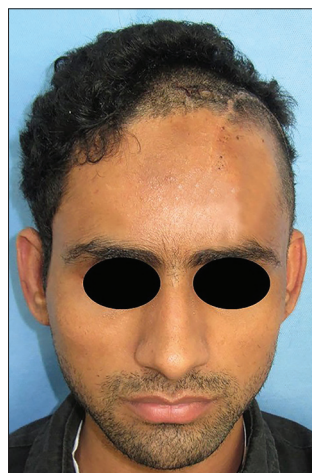

Figure 8: Final result after 6 months

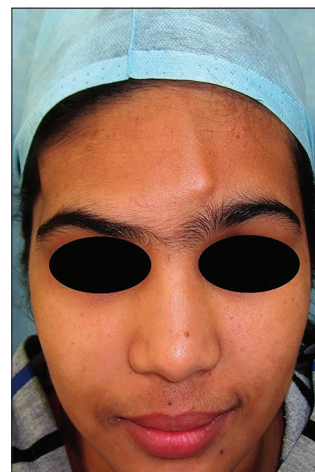

Figure 9: Preoperative frontal view of defect with disfigure implants

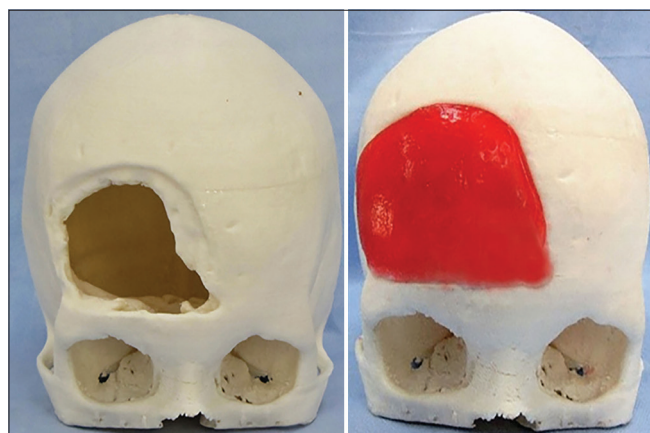


Figure 10: 3D Model with defect and Wax pattern fabricated on 3D model

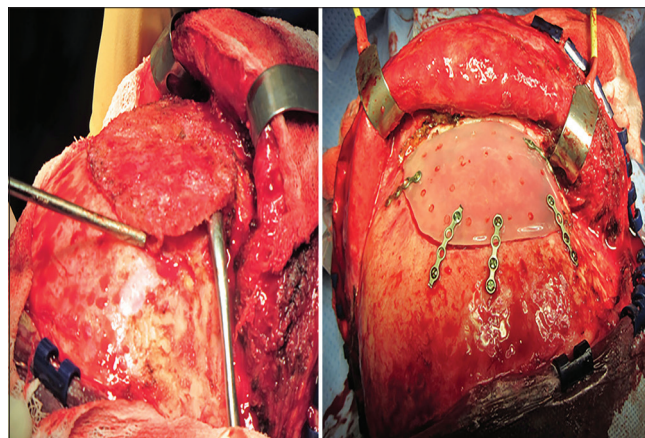


Figure 11: Intra operative view (Biopore implant removed and polymethyl methacrylate implant secured in place)

conventionally in heat-cured clear PMMA. PMMA graft was retrieved from mold, finished, and polished before drilling of holes in it. The graft was surgically screwed in place using titanium plates and mini-screws. The patient was evaluated after 3 wks for a favorable outcome of the graft and esthetic contour of the vault. The patient was reviewed after 6 months to find improvement of motor functions and the patient was able to walk with support.

## DISCUSSION

### Material for cranial graft

Cranioplasty as a procedure, dates back to as far back as 3000BC, where Incan civilization showed evidence of

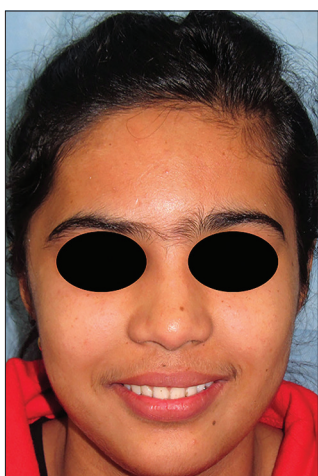

Figure 12: Postoperative frontal view

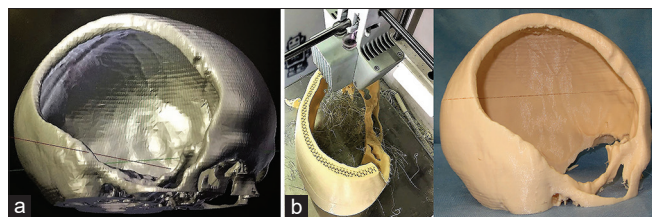


Figure 13: (a) Digital reconstruction of defect from computerized tomography scan data. (b) 3D printing of model and model with defect

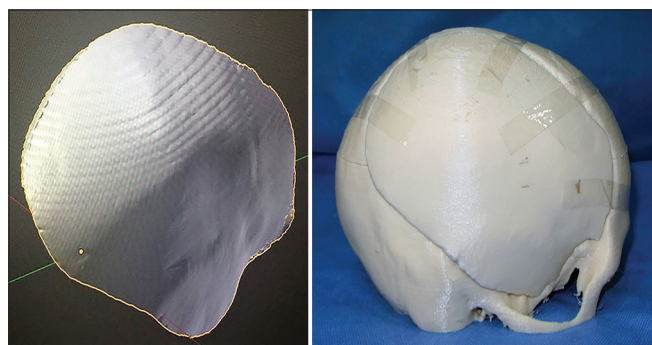


Figure 14: Digital model of restoration of the defect and 3D printer model of restoration

this procedure using metals, shells, and other inorganic materials.<sup>[11]</sup> Since then many materials and techniques have been employed, tried and developed to effectively perform this procedure. Causes of cranial defects may vary from tumor surgeries to decompression craniotomy. The full-thickness flap that is removed is kept in the abdominal pocket to preserve it but many times, it is either infected or not preserved properly.<sup>[12]</sup> In such cases, a need for cranioplasty with grafts other than the original bone flap arises. For such conditions, there are various materials and methods to perform cranioplasty, which include allografts and alloplasts. Alloplasts commonly used for cranial implant include titanium and polymethylmethacrylate.<sup>[13-17]</sup> Both these popularly used materials in cranioplasty procedures have advantages and disadvantages. PMMA has been used in cranioplasty since World War II when the sudden need of cranioplasty increased. Acrylic as the material is easier to shape, has poor thermal conduction and is lightweight with excellent plasticity and radiolucency making it the material of choice. Moreover, PMMA can also be modified easily at the time of surgery and hence has shown to have better esthetic outcomes.<sup>[18,19]</sup> Titanium on the other hand, as a material for cranioplasty has also shown considerable advantages, like it being lightweight, exceptionally strong, cover large defects, and inert. However, titanium comes with few inherent disadvantages as it is costly, interferes with MRI/radiographic evaluation and difficult to adjust intraoperatively.<sup>[20-22]</sup> Another option is to use a customized PMMA implant impregnated with titanium mesh which imparts rigidity and stability to it. In addition, the titanium mesh is malleable, thin, biocompatible and does not interfere in MRI due to its non-ferromagnetic property thus making long-term follow-up of the patient easy. However, it increases the cost of the graft as compared to using PMMA alone.<sup>[23]</sup>

With details of commonly used alloplastic materials being discussed an important question that remains is which material is ideal to use. Various studies describing the use of titanium, PMMA, Polyether Ether Ketone, etc., showed that PMMA has similar complications as others.<sup>[24]</sup> Stating this PMMA when compared retrospectively showed that PMMA as implant materials is as justifiable as autogenous grafts and it is a readily available, cost-effective material.<sup>[25]</sup> Moreover, PMMA grafts have shown favorable esthetic results even for large cranial defects.<sup>[26]</sup> In addition, the use of 3D printing for making prefabricated patient-specific PMMA implants has minimized human errors and reducing the chairside time resulting in fewer complications and better esthetic outcomes.

### Method of fabrication

PMMA cranial grafts have gained popularity due to the various

advantages and ease of fabrication. However, initially, the PMMA grafts were conventionally fabricated over the models obtained by making a conventional moulage impression of the defect. In this technique, conventional moulage impressions were made by arbitrarily marking the margins of the defect over the scalp and recorded using appropriate impression material. However, due to unavoidable procedural errors involved, the outcome is not very reliable. Recently, a more accurate method of prefabricating cranial plates directly or through models has been followed which includes 3D printing.<sup>[27,28]</sup> This procedure has markedly improved the accuracy as well as reduced the surgery cost and time. Studies prove that cranioplasty carried out using 3D procedures reduces surgical time by 85% and gives a better fit of the implant.<sup>[18]</sup>

## CONCLUSION

Cranial defects have always been associated with challenges and unanticipated results. Autografts and allografts have been tried extensively with success, but alloplasts have been proven to be less complicated and an easy way of rehabilitating the defect. PMMA cranioplasty has shown to have lesser infections and are easier to fabricate. Reinforcing with titanium is also an effective way of improving properties at the same time keeping the procedure simple. Conventional moulage impression making of the defect is a cost-effective way of fabricating a moulage cast of the defect but a 3D printed model is both more accurate and easier to work on. A well-fabricated prosthesis which requires minimum adjustment during the surgery and made of material with is both bioinert and well accepted by the body is a road map to successful rehabilitation. As a maxillofacial Prosthodontist, cranioplasty is a challenge but recently medical imaging and modeling and digital advances have increased the accuracy and made the task comparatively easy.

### Finally to sum up

- A high-resolution CT scan with the minimum slice thickness possible should be used to visualize the defect on a digital interface more accurately.
- It is beneficial to use digital designing and 3D printing to directly fabricate patient-specific implant.
- When digital designing is not possible (large defect, bilateral defects) a 3D printed model of defect made using CT scan should be used for accuracy.
- PMMA with its limitation still proves to be a more cost-effective and feasible option for a patient specific implant.
- Following these simple guidelines precious intraoperative time can be saved as well as a definitive esthetic outcome of cranial reconstruction can be obtained.

### Declaration of patient consent

The authors certify that they have obtained all appropriate patient consent forms. In the form, the legal guardian has given his consent for images and other clinical information to be reported in the journal. The guardian understands that names and initials will not be published and due efforts will be made to conceal identity, but anonymity cannot be guaranteed.

### Financial support and sponsorship

Nil.

### Conflicts of interest

There are no conflicts of interest.

## REFERENCES

- Dumbrigue HB, Arcuri MR, LaVelle WE, Ceynar KJ. Fabrication procedure for cranial prostheses. *J Prosthet Dent* 1998;79:229-31.
- Haug RH, Adams JM, Conforti PJ, Likavec MJ. Cranial fractures associated with facial fractures: A review of mechanism, type, and severity of injury. *J Oral Maxillofac Surg* 1994;52:729-33.
- Bandyopadhyay TK, Thapliyal GK, Dubey AK. Reconstruction of cranial defects in armed forces personnel - Our experience. *Med J Armed Forces India* 2005;61:36-40.
- Eppley BL, Kilgo M, Coleman JJ 3<sup>rd</sup>. Cranial reconstruction with computer-generated hard-tissue replacement patient-matched implants: Indications, surgical technique, and long-term follow-up. *Plast Reconstr Surg* 2002;109:864-71.
- Stiver SI. Complications of decompressive craniectomy for traumatic brain injury. *Neurosurg Focus* 2009;26:E7.
- Stiver SL, Wintermark M, Manley GT. Motor trephine syndrome: A mechanistic hypothesis. *Acta Neurochir Suppl* 2008;102:273-7.
- Liang W, Xiaofeng Y, Weiguo L, Gang S, Xuesheng Z, Fei C, *et al.* Cranioplasty of large cranial defect at an early stage after decompressive craniectomy performed for severe head trauma. *J Craniofac Surg* 2007;18:526-32.
- Beumer J 3<sup>rd</sup>, Firtell DN, Curtis TA. Current concepts in cranioplasty. *J Prosthet Dent* 1979;42:67-77.
- Pietrzak WS. Musculoskeletal tissue regeneration: Biological materials and methods. In: *Musculoskeletal and Wound Treatment through Ages: A Brief Historical Tour*. Ch. 1. Totowa, USA: Springer Humana Press Publishers; 2008. p. 3-18.
- Abdulai A, Idrissu M, Dakurah T. Cranioplasty using polymethyl methacrylate implant constructed from an alginate impression and wax elimination technique. *Ghana Med J* 2006;40:18-21.
- Feroze AH, Walmsley GG, Choudhri O, Lorenz HP, Grant GA, Edwards MS. Evolution of cranioplasty techniques in neurosurgery: Historical review, pediatric considerations, and current trends. *J Neurosurg* 2015;123:1098-107.
- Kirkpatrick P. Operative neurosurgical techniques. Indications, methods and results. *J Neurol Neurosurg Psychiatry* 1996;60:467.
- Durham SR, McComb JG, Levy ML. Correction of large (>25 cm(2)) cranial defects with "reinforced" hydroxyapatite cement: Technique and complications. *Neurosurgery* 2003;52:842-5.
- Chiarini L, Figurelli S, Pollastri G, Torcia E, Ferrari F, Albanese M, *et al.* Cranioplasty using acrylic material: A new technical procedure. *J Craniomaxillofac Surg* 2004;32:5-9.
- Martin MP, Olson S. Post-operative complications with titanium mesh. *J Clin Neurosci* 2009;16:1080-1.
- Cabraja M, Klein M, Lehmann TN. Long-term results following titanium

- cranioplasty of large skull defects. *Neurosurg Focus* 2009;26:E10.
17. Azmi A, Latiff AZ, Johari A. Methyl methacrylate cranioplasty. *Med J Malaysia* 2004;59:418-21.
  18. Al-Tamimi YZ, Sinha P, Trivedi M, Robson C, Al-Musawi TA, Hossain N, *et al.* Comparison of acrylic and titanium cranioplasty. *Br J Neurosurg* 2012;26:510-3.
  19. Aydin S, Kucukyuruk B, Abuzayed B, Aydin S, Sanus GZ. Cranioplasty: Review of materials and techniques. *J Neurosci Rural Pract* 2011;2:162-7.
  20. Bhargava D, Bartlett P, Russell J, Liddington M, Tyagi A, Chumas P. Construction of titanium cranioplasty plate using craniectomy bone flap as template. *Acta Neurochir (Wien)* 2010;152:173-6.
  21. Joffe J, Harris M, Kahugu F, Nicoll S, Linney A, Richards R. A prospective study of computer-aided design and manufacture of titanium plate for cranioplasty and its clinical outcome. *Br J Neurosurg* 1999;13:576-80.
  22. Kuttenger JJ, Hardt N. Long-term results following reconstruction of craniofacial defects with titanium micro-mesh systems. *J Craniomaxillofac Surg* 2001;29:75-81.
  23. Sane VD, Kadam P, Jadhav A, Saddiwal R, Merchant Y. Multidisciplinary approach for reconstruction of cranial defect with polymethyl methacrylate resin reinforced with titanium mesh. *J Indian Prosthodont Soc* 2016;16:294-7.
  24. Oliver JD, Banuelos J, Abu-Ghname A, Vyas KS, Sharaf B. Alloplastic cranioplasty reconstruction: A systematic review comparing outcomes with titanium mesh, polymethyl methacrylate, polyether ether ketone, and norian implants in 3591 adult patients. *Ann Plast Surg* 2019;82:S289-94.
  25. Vince GH, Kraschl J, Rauter H, Stein M, Grossauer S, Uhl E. Comparison between autologous bone grafts and acrylic (PMMA) implants – A retrospective analysis of 286 cranioplasty procedures. *J Clin Neurosci* 2019;61:205-9.
  26. Jaber J, Gambrell K, Tiwana P, Madden C, Finn R. Long-term clinical outcome analysis of poly-methyl-methacrylate cranioplasty for large skull defects. *J Oral Maxillofac Surg* 2013;71:e81-8.
  27. Eplogle RE, Lanzino G, Francel P, Henson S, Lin K, Jane JA. Acrylic cranioplasty using miniplate struts. *Neurosurgery* 1996;39:747-9.
  28. Chrzan R, Urbanik A, Karbowski K, Moskała M, Polak J, Pyrich M. Cranioplasty prosthesis manufacturing based on reverse engineering technology. *Med Sci Monit* 2012;18:MT1-6.