

Original Paper

Human Cystic Echinococcosis in the Nalut District of Western Libya: A Clinico-epidemiological Study

Rabie M. Mohamed¹, Ekhlas H. Abdel-Hafeez¹, Usama S. Belal¹, Kazumi Norose² and Fumie Aosai^{3*}

Received 19 June, 2014 Accepted 7 September, 2014 Published online 17 September, 2014

Abstract: Human cystic echinococcosis (CE) is an endemic disease in the Mediterranean area that has not yet been fully documented in western Libya. The present study describes the clinico-epidemiologic profile of CE in western Libya's Nalut district. From April 2008 to July 2011, 36 cases of CE were confirmed following surgical removal of cysts. The cysts were most frequently found in the liver (61.1%), followed by the lungs (19.4%), kidneys (11.1%), peritoneal cavity (11.1%), and spleen (5.6%). Among the 36 patients, 6 possessed plural cysts and 3 had cysts in 2 organs. Blood samples from this group were examined for the presence of serum anti-hydatid IgG antibodies, which revealed positivity in 25 patients (69.4%). An additional 300 blood samples were collected randomly from the inpatient and outpatient clinics at Nalut Hospital. Twenty-seven samples (9%) were found to be positive for the anti-hydatid IgG antibody among which the prevalence of infection tended to be higher in men (12%) than in women (6%). This study demonstrates that CE is a major parasitic infectious disease of public health significance in Libya, notably in the western part of the country, and that disease awareness needs to be raised nationwide.

Key words: Human cystic echinococcosis (CE), Nalut district, Libya, Prevalence of CE

INTRODUCTION

Cystic echinococcosis/hydatidosis (CE) is one of the most prominent types of zoonotic helminthiasis in sheep-rearing areas worldwide [1]. High parasite prevalence is particularly widespread in the Middle East and in Arabic North Africa [2, 3]. The World Health Organization (WHO) estimates that cystic hydatid disease results in the loss of 1–3 million disability-adjusted lives per annum. CE transmission typically occurs from dogs to humans and not directly between humans [4, 5].

CE is a serious public health and livestock-related economic problem in Libya, with an incidence of more than 1 per 100,000 individuals within the Libyan population according to surveys from 1970 to 2006 [6]. The frequency of surgically confirmed CE in the Benghazi area, which is located in northeastern Libya approximately 1,325 km east of Nalut, was estimated to be at least 4.2 per 100,000 individuals [7]. Whereas *E. granulosus* is the only species of the genus *Echinococcus* found in Libya [8, 9], *E. multicularis* is exclusively autochthonic in other areas

worldwide, including Hokkaido in Japan [10]. Most sheep and goat herders in Libya keep dogs and livestock together. As the domestic dog serves as the only known reservoir for the adult tapeworm of *E. granulosus* in Libya, dogs play a confirmed role in CE as the main source of infection and a cause of both public health and veterinary problems [11].

Although CE is reported to be endemic in Libya [12, 13], the analysis of this disease has been limited to the past 10 years [6, 14]. Furthermore, no studies have been conducted on CE in the Nalut district to date. We therefore examined the clinico-epidemiological profile of human CE in the Nalut district in western Libya, near the border with Tunisia. The population of this rural area is suspected to be at high risk for CE infection because many inhabitants have flocks of sheep or goats that are kept around dogs for protection.

¹ Department of Parasitology, Faculty of Medicine, Minia University, Minia, 61519, Egypt

² Department of Infection and Host Defense, Graduate School of Medicine, Chiba University, 1-8-1 Inohana Chuo-ku, Chiba 260-8670, Japan

³ Department of Infection and Host Defense, Graduate School of Medicine, Shinshu University, 3-1-1 Asahi, Matsumoto 390-8621, Japan

*Corresponding author:

Tel: 81-263-37-2625

Fax: 81-263-37-2626

E-mail: faosai@shinshu-u.ac.jp

METHODS

Subjects

This prospective study included 36 cases of CE that were diagnosed and treated surgically at Nalut Hospital in the Libyan Arab Jamahiriya between April 2008 and July 2011. An additional 300 blood samples were collected randomly from the inpatient and outpatient clinics at Nalut Hospital, situated approximately 270 km southwest of the Libyan capital, Tripoli. The Nalut region has an area of 67,191 km² and a population of 93,224 (Fig. 1).

The patients were divided into 2 groups, as follows:

Group 1: Thirty-six cases of surgically confirmed CE initially diagnosed by clinical and imaging (X-ray, ultrasound [US], and/or computerized tomography [CT]) findings. Aspiration of the cystic fluid for parasitological examination was also done for disease confirmation.

Group 2: Three hundred cases randomly selected from the inpatient and outpatient clinics at Nalut Hospital.

All of the subjects in Groups 1 and 2 provided in-

formed consent and were subjected to the following:

- 1) Questionnaire and full clinical examination that included history and physical findings, with special emphasis on geographic location (i.e., residence in endemic region and history of visits to any known endemic region), family history of CE, and association with dogs, sheep, or animal slaughtering at home.
- 2) Imaging studies: Plain radiographs and abdominal US and CT images were obtained for Group 1.
- 3) Routine laboratory examinations: Urine, stool, and complete blood profiling especially for eosinophilia.

Serum samples

Blood samples were collected from all subjects and 3–4 drops of whole blood were placed onto filter paper strips, as described previously [15]. Briefly, the blood drops were left at room temperature until dry, and then the dried paper strips were stored at –20°C until use. As negative controls, 20 blood samples were obtained from non-CE cases, i.e., 10 healthy subjects and 10 patients with other parasitic infections (4 with ascariasis, 3 with taeniasis saginata, and 3 with toxoplasmosis) at Nalut Hospital.

Preparation of somatic antigen

Hydatid cysts of *E. granulosus* were collected from the lungs and liver of sheep and goats slaughtered in Nalut province. Afterwards, protoscolices were isolated from the cysts by aseptic cyst puncture, washed with phosphate-buffered saline (PBS), and stored at –20°C with proteolytic enzyme inhibitors (2 mM PMSF and 5 mM EDTA). The protoscolices were thawed, sonicated (10 cycles of 12 s at 60 Hz), freeze-thawed once more, and centrifuged for 35 min at 2,300 × g at 4°C. After centrifugation, the supernatants were aliquotted and stored at –20°C [16–18] for use as somatic antigens (S-Ag).

Enzyme-linked immunosorbent assay (ELISA)

ELISA was carried out as previously described [18–20]. The optimal antigen concentration of S-Ag was 7.5 µg/ml. Microtitre plates (Maxisorp, Nunc, Roskilde, Denmark) were coated with S-Ag diluted in PBS (100 µl/well) and incubated overnight at 4°C. After removal of the S-Ag, blocking was performed using PBS containing 1% bovine serum albumin (BSA; 200 µl/well) for 1 h at 37°C. Blood sample spots of 5 mm in diameter were punched from filter papers using a paper puncher and placed into 1.5-ml micro-tubes containing 250 µl (final serum dilution: approximately 1:100) PBS/0.05% Tween 20 (TPBS) with 5% (v/v) skimmed milk. The tubes were placed on a flask shaker set at full speed for 20 min at 37°C. Tube contents were allowed to settle for 10 min prior to loading onto

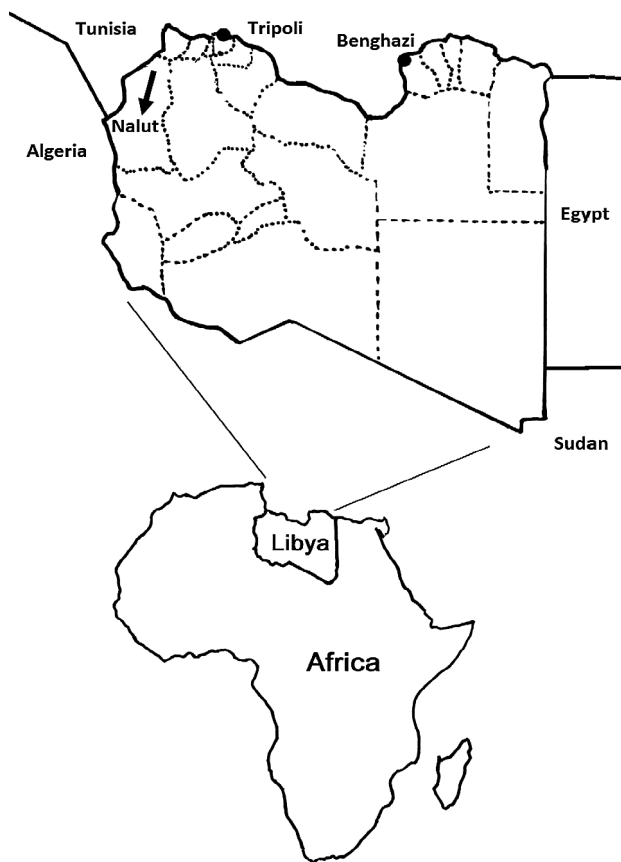


Fig. 1. Map of the Nalut District, Libya. The Nalut district lies approximately 270 km southwest of the Libyan capital, Tripoli. It has an area of 67,191 km² and a population of 93,224.

micro-titer plate wells. The serum (100 μ l/well) in the tubes was tested in duplicate using serial dilutions ranging from 1:100 to 1:200. The plates were incubated for 1 h at 37°C. Peroxidase-conjugated rabbit anti-human IgGs (Sigma-Aldrich, Dorset, UK) were used at a 1:1000 dilution in TPBS for 1 h at 37°C. Binding was visualized with 5-aminosalicylic acid. The reaction was stopped by adding 25 μ l/well 1N NaOH, and absorbance was measured at 450 nm with an ELISA reader (STAT-FAX-2100, Ohio, USA). Serologic results were considered to be reactive when the serum dilution showed an optical density (OD) of absorbance of equal to or higher than the cut-off point, which was calculated using the mean OD value plus three standard deviations of negative control serum [20].

Examination of cyst fertility

Cyst fertility was determined as earlier described [21]. Briefly, gross cyst samples were examined for degeneration, and then the cyst wall was penetrated using a needle and cut with scalpel and scissors. The contents of the cyst were collected in a sterile container. The cysts were classified as fertile (containing fluid with protoscolices) or sterile (containing fluid absent of protoscolices).

Classification of the abdominal cysts by US

Abdominal cysts were visualized by US (Fukuda Denchi, Co, Ltd., Japan) and classified according to the criteria proposed by the WHO [22] into three clinical groups. The first group is active fertile cysts containing viable protoscolices, the second group is in a transitional stage, i.e., cysts have started to degenerate but usually still contain viable protoscolices, and the third group is inactive cysts that have lost their fertility, or are degenerated or partially or totally calcified.

Statistical analysis

Fisher's exact probability test was adopted for evaluation of age and gender distribution as well as for seroprevalence as determined by ELISA among the 36 CE patients in Group 1. The MxN χ^2 test was used to compare the variables of affected organ and gender distribution in Group 1 and seroprevalence among the 300 samples in Group 2. The χ^2 test was used to analyze the independency of gender and seroprevalence in Group 2. A *P* value of < 0.05 was considered to be statistically significant.

RESULTS

The 36 patients of Group 1 who were treated surgically for CE at Nalut Hospital are summarized in Table 1. All patients were residents of the Nalut district or surrounding

areas. Five patients had family members also afflicted by CE. Peripheral blood eosinophilia ranged from 7 to 15% in this group. Seroprevalence was higher in women (20/36 cases, 55.6%) than in men (16/36 cases, 44.4%), albeit not significantly.

In terms of location, cysts were found most frequently in the liver (22/36 cases, 61.1%), followed by the lungs (7/36 cases, 19.4%), kidneys (4/36 cases, 11.1%), peritoneal cavity (4/36 cases, 11.1%), and spleen (2/36, 5.6%). No cysts were detected in the brain or other organs.

Three patients (case 9, 14, and 30) possessed cysts in 2 organs. All of them had cyst(s) in the liver, with an additional cyst either in the peritoneal cavity (case 14 and 30) or kidney (case 9) (Table 1). There were 4 patients who exhibited 2 cysts in a single organ: 3 patients (case 18, 25, and 30) had 2 cysts in the liver and 1 patient (case 13) had 2 cysts in the lung (Table 1). No significant relationship was found between gender and cyst location. The average size of the cysts was 8 \times 6 cm, as depicted in Figs. 2A and 2B, with a range of 3 to 18 cm.

Apart from the 8 lung cysts found in 7 patients, 35 abdominal cysts from the liver, kidney, peritoneum, and spleen of 29 patients were clinically classified according to the guidelines proposed by WHO based on US findings. The cysts were classified as belonging to the 1st, 2nd and 3rd clinical group, with an incidence of 20/35 (57%), 7/35 (20%), and 8/35 (23%) respectively (Table 1). Thus, active cysts containing viable protoscolices were the most common among CE patients.

Cyst fluid was aspirated and observed by light microscopy for all cases. Hooklets and protoscolices in the aspirates are shown in Fig. 3. Twenty-two patients (22/36 cases, 61%) had fertile cysts with the presence of protoscolices, while the remaining patients (14/36 cases, 39%) had sterile cysts (Table 1). The 1st, 2nd and 3rd clinical classification of the 24 cysts of 18 patients with fertile abdominal cysts was 16/24 (67%), 5/24 (21%), and 3/24 (12%), respectively, and was 4/11 (36%), 2/11 (18%), and 5/11 (45%), respectively, among the 11 patients with sterile abdominal cysts.

Among the serum samples collected from Group 1 that were subjected to indirect ELISA, 25/36 cases (69.4%) were found to be positive for the anti-hydatid IgG antibody. On the other hand, 11/36 cases (30.6%) were negative for the anti-hydatid IgG antibody despite the presence of cysts (7 cases of cysts in the liver, 3 in the lung, and 1 in the kidney) (Table 1). Among the negative controls, 2/20 cases (10%) were positive for the anti-hydatid IgG antibody. Thus, the sensitivity and specificity of our ELISA were shown to be 69.4% (25/36 cases) and 90% ([20-2]/20 cases), respectively.

Table 1. Characteristics of the 36 surgically treated patients with cystic echinococcosis in Group 1

Case number	Sex	Age	R/U* ¹	FH* ²	AC* ³	Eo* ⁴ (%)	Ab* ⁵ in serum	Cyst number in organs* ^{7,8}					Total cyst number
								Liver	Lung	Kidney	Spleen	PC* ⁶	
1	M	31	R	-	-	12	+	1 ^{2nd, F}					1
2	M	66	R	-	-	11	+	1 ^{1st, F}					1
3	F	35	R	-	+	9	-	1 ^{3rd, S}					1
4	M	33	R	-	+	9	+			1 ^{2nd, F}			1
5	M	28	U	-	+	12	+				1 ^{1st, S}		1
6	F	24	U	-	+	11	-		1 ^S				1
7	F	44	R	+	-	9	+	1 ^{1st, F}					1
8	M	29	R	-	+	7	+		1 ^F				1
9	F	61	R	-	-	15	+	1 ^{1st, F}		1 ^{1st, F}			2
10	F	63	R	+	+	8	-	1 ^{3rd, F}					1
11	M	42	R	-	+	9	+	1 ^{1st, F}					1
12	F	52	U	-	+	7	-	1 ^{3rd, S}					1
13	F	38	U	-	-	14	+		2 ^F				2
14	F	48	R	-	+	13	+	1 ^{1st, F}				1 ^{3rd, F}	2
15	M	46	R	+	+	9	-	1 ^{3rd, S}					1
16	M	51	R	-	+	11	+	1 ^{1st, S}					1
17	F	49	R	-	+	10	+		1 ^S				1
18	F	45	U	-	-	15	+	2 ^{1st, F}					2
19	M	51	U	-	+	8	+			1 ^{1st, F}			1
20	F	53	R	-	+	9	+	1 ^{3rd, F}					1
21	F	46	R	+	+	7	+					1 ^{2nd, F}	1
22	M	46	R	-	+	14	-		1 ^F				1
23	M	56	R	-	+	9	-			1 ^{3rd, S}			1
24	F	41	U	-	+	13	+	1 ^{2nd, S}					1
25	F	46	U	+	+	11	+	2 ^{1st, F}					2
26	F	52	R	-	+	10	+		1 ^S				1
27	M	60	R	-	-	8	+	1 ^{3rd, S}					1
28	M	47	R	-	+	9	+				1 ^{2nd, F}		1
29	F	55	R	-	+	7	-	1 ^{2nd, S}					1
30	M	53	U	-	-	14	+	2 ^{1st, F}				1 ^{1st, F}	3
31	F	61	R	-	+	9	+					1 ^{1st, F}	1
32	F	53	U	-	+	13	+	1 ^{1st, S}					1
33	M	64	R	-	-	11	-		1 ^F				1
34	M	58	R	-	+	10	-	1 ^{2nd, F}					1
35	F	60	U	-	+	7	-	1 ^{1st, S}					1
36	F	49	R	-	+	8	+	1 ^{1st, F}					1

*¹ R: rural residence, U: urban residence, *² Family history, *³ Animal contact, *⁴ Eosinophilia (%), *⁵ Anti-CE antibody in serum, *⁶ Peritoneal cavity, *⁷ F: fertile cyst, S: sterile cyst, *⁸ WHO clinical classification of abdominal cysts into 1st, 2nd, or 3rd group

Abdominal cysts in seropositive cases were classified as belonging to the 1st, 2nd and 3rd clinical group at an incidence of 19/27 (70%), 5/27 (19%) and 3/27 (11%), respectively. In contrast, abdominal cysts in seronegative cases were classified as belonging to the 1st, 2nd and 3rd clinical group at a frequency of 1/8 (12.5%), 2/8 (25%), and 5/8 (62.5%), respectively (Table 1). Seropositive and seronegative patients who had fertile cysts were 19/23

(83%) and 4/23 (17%), respectively, while those who had sterile cysts were 6/13 (46%) and 7/13 (54%) respectively. Thus, antibody response and cyst activity were closely related.

The prevalence of seropositivity was similar between women (14/20) and men (11/16).

The 300 serum samples collected from Group 2 were also subjected to ELISA examination. Among them,

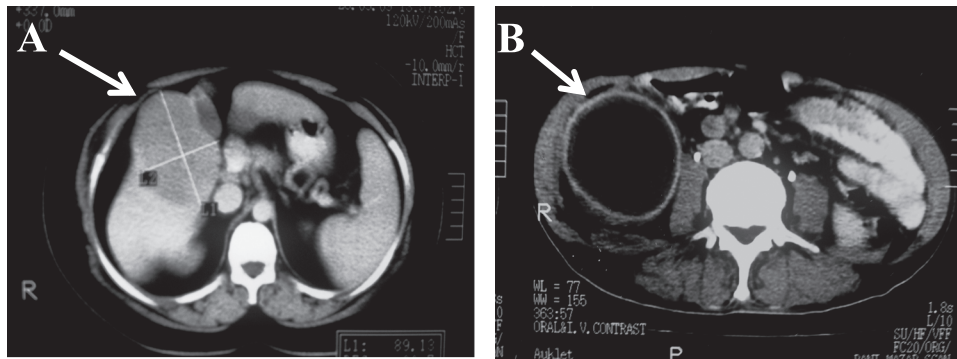


Fig. 2. CT scan of a hydatid cyst. (A) Hydatid cyst in the liver of case 5. A mass with homogeneous density (white arrow) is depicted in the right lobe. (B) Hydatid cyst in the peritoneum of case 21. The white arrow indicates a round lesion.

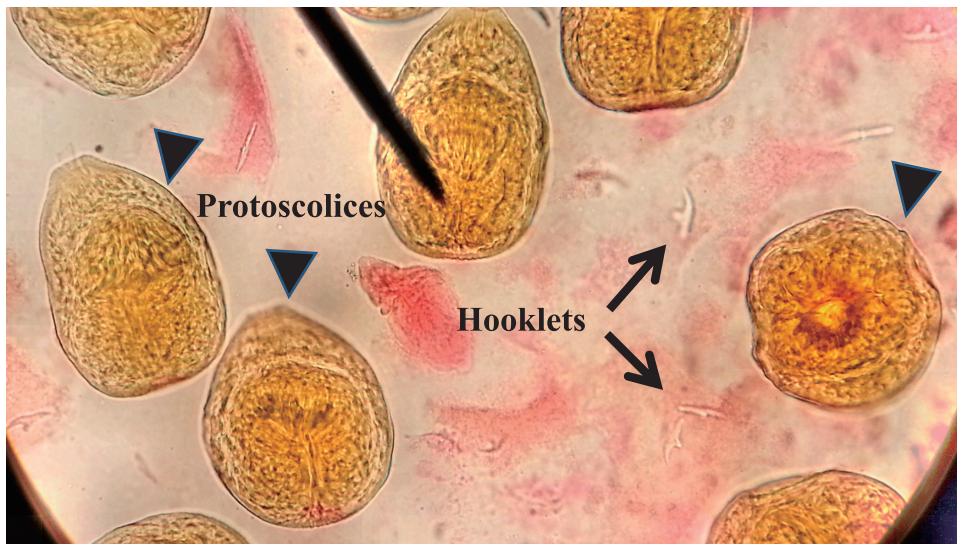


Fig. 3. Hydatid sand under light microscopic examination. Hydatid sand from the cyst aspirate of case 21 contained hooklets (black arrows) and protoscolices (black arrowheads) of *Echinococcus granulosus* (eosin staining, $\times 10$ magnification).

Table 2. Seroprevalence of cystic echinococcosis among 300 samples in Group 2

Sex	Age (years)	No. of seropositive cases/ total cases	%
Male	0–20	3/50	6%
	21–40	6/50	12%
	41–70	9/50	18%
	Total	18/150	12%
Female	0–20	1/50	2%
	21–40	2/50	4%
	41–70	6/50	12%
	Total	9/150	6%
Total		27/300	9%

27/300 samples (9%) were found to be positive for the anti-hydatid IgG antibody. The 41–70 year age group showed the highest seroprevalence in both sexes compared with other age groups despite the statistical independency between age and seroprevalence. With regard to gender, the prevalence of infection tended to be higher in men (18/150 cases, 12%) than in women (9/150 cases, 6%) ($p = 0.069$) (Table 2).

DISCUSSION

Echinococcosis is a lethal worldwide zoonosis caused by adult or larval stages of tapeworms of the genus *Echinococcus*. Transmission of echinococcosis relies on carnivores as definitive hosts and various animals as intermediate hosts. Humans and intermediate hosts are infected with echinococcosis by ingesting eggs of *Echino-*

coccus spp. in materials directly or indirectly contaminated with the feces of infected carnivores [23].

In this study, CE was detected more frequently in the liver (61.1%) than in the lungs (19.4%), a finding consistent with other studies [24–26] reporting that cystic larvae develop mainly in the liver (67–89%) and pulmonary regions (10–15%) and that 10% of cysts can occur almost anywhere else in the body. This may be attributable to the fact that the liver and lungs possess greater capillary fields that allow these organs to preferentially filter the ingested oncospheres. In addition, the liver is responsible for the primary filtration of blood from portal veins, followed by pulmonary filtering before other organ involvement; only those oncospheres that are transferred via the blood reach the systemic circulation and other tissues [1].

In Group 1, 25 cases (69.4%) of surgically confirmed CE were seropositive for the anti-hydatid IgG antibody and the remaining 11 cases (30.6%) were seronegative. This result is consistent with that of Eckert and Deplazes [1], who reported that approximately 10 to 20% of patients with hepatic cysts and roughly 40% of patients with pulmonary cysts do not produce detectable specific serum IgG antibodies and therefore give false-negative results. The production of IgG antibodies mainly depends on the number, size, topography, and condition of hydatid cysts [27]; antibody production is low or absent in cases of small cysts, intact cysts, and highly calcified cysts. Furthermore, ELISA is not considered to be 100% sensitive or specific since results vary depending on the kit and, more specifically, the antigen used. Although antigens derived from larvae with humans as the intermediate host are recommended for the serodiagnosis of human CE, those of *E. granulosus* protoscolices obtained from hydatid cysts have been successfully adopted in the past [17–19, 29, 30]. A wide range of sensitivities (31–96%) and specificities (40–100%) has been reported among ELISA kits [31, 32]. The sensitivities of recombinant antigen B (AgB) or AgB peptides and the hydatid fluid (HF) in the diagnosis of human CE were shown to be comparable at 26–89% and 50–98%, respectively [31]. According to the most recent report by Reiterová et al. [33], purified AgB-ELISA had a 96.4% sensitivity and 97.2% specificity and was more specific, but less sensitive, than HF-ELISA. They recommended AgB-ELISA for seroconfirmation of acute CE diagnosis over HF-ELISA since antibody responses to AgB were undetectable in the sera of CE patients more than 3 months after treatment, whereas those to HF were still positive [33].

Although ELISA testing provided only 69.4% sensitivity in the present study, two previous reports using protoscolices for serodiagnosis showed high diagnostic

sensitivities of 83% [29] and 90% [18]. The same antigen has also been used for the immunodiagnosis [19, 30] and serological follow-up of young patients after surgical treatment for CE [34]. The low sensitivity in our study might be due to the fact that 23% of the surgically removed abdominal cysts were in the 3rd clinical group and thus calcified. It is noteworthy that the antibody response and cyst activity were closely related the clinical classification in this study. Additional immunodiagnostic methods for CE, such as Western blotting, combinations of several defined antigens, detection of circulating antigen(s), and DNA analyses are recommended to improve the detection of CE [32, 35].

Although we could not analyze the genotype of *E. granulosus* in surgically removed cysts from the Nalut district in western Libya, it has been proposed to be similar to that reported in the eastern part of Libya [35] and bordering Tunisia [36, 37]. These studies revealed the genotype of the *E. granulosus* to be *E. granulosus sensu stricto* [36–38].

A high level of CE seropositivity (9%) in the general Nalut district population was revealed by the study of Group 2. This result was consistent with another seroepidemiologic study of 250 school children in northwest Libya (Benghazi area), which showed that 10% of the children were seropositive for antibodies to CE by ELISA [39]. The incidence of surgically confirmed CE in eastern Libya is estimated to be approximately 4.2/100,000 individuals with a significant female predominance [7]. Meanwhile, US and serological examinations have revealed that up to 4.5% of people living in northern Libya are afflicted by the disease [13].

The high prevalence of CE in this study may be attributable to the following risk factors proposed by Altintas [40] and Seimenis [41]: 1) people are generally poorly educated about CE and there is a lack of health awareness of the disease; 2) the majority of the population lives in rural areas and works in agriculture or sheep or goat herding amid the widespread presence of dogs; 3) most of the population believes in Islam. Once a year during a sacrificial festival, tens of thousands of sheep and goats are slaughtered, thus providing stray dogs with the remains of infected intermediate hosts; 4) a large number of infected stray and free-roaming dogs are present; 5) livestock are slaughtered for daily meat requirements, which further facilitates the life cycle of the parasite; and 6) the disposal of infected organs is frequently not done properly [40, 41]. Improper disposal of animal carcasses that are left unburied or exposed to scavenging carnivores also creates favorable conditions for environmental contamination [42]. Among these risk factors, two major ele-

ments were of particular note in our study: 1) Bedouin Arabic populations eat meat daily, especially that of sheep and goats which are slaughtered at the home, with the practice of feeding dogs offal from ruminant livestock; and 2) ignorance and a decline in veterinary public health services as shown by the fact that even slaughter houses leave infected organs for dogs.

Although illness usually occurs approximately 5–10 years after infection, CE may present in individuals younger than 1 year of age and older than 75 years [43]. The age of our CE-positive patients ranged from 24 to 86 years, with a mean of 58.3 years, suggesting that increased opportunities for exposure to parasitic ova over a long period of time raises the possibility of acquiring an infection. This finding is consistent with the multivariate analysis conducted by Fotiou *et al.* [44], who revealed that an age of 65 and above was significantly associated with seropositivity. They pointed out that the likelihood of acquiring antibodies against CE increases with age, even without necessarily developing the illness. With regard to gender, seropositive males (12%) were more frequent than seropositive females (6%) in the present study. This may be attributable to the greater number of outdoor activities performed by men in the Nalut district and increased contact with sources of infection, such as dogs and soil. A study similar to ours was conducted and arrived at a comparable conclusion [45]. A report from Italy also remarked that men were more likely to be exposed to echinococcal infection than women [46]. On the other hand, several studies have shown a minimal difference regarding gender distribution [47, 48] while others have reported just the opposite [13, 49, 50]. The disparity is likely due to differences in culture, socio-economic status, and tradition among countries and areas.

To our knowledge, this is the first report describing the seroprevalence of CE infection in the general population of the Nalut district in western Libya. Our results indicate that CE is a major parasitic infection with great public health significance, especially in the western areas of the country. Clinicians and health authorities are advised to pay much greater attention to CE and make additional efforts to eliminate this disease as quick as possible.

REFERENCES

- Eckert J, Deplazes P. Biological, epidemiological, and clinical aspects of echinococcosis, a zoonosis of increasing concern. *Clin Microbiol Rev* 2004; 17: 107–135.
- Battelli G, Mantovani A, Seimenis A. Cystic echinococcosis and the Mediterranean Region: a long-lasting association. *Parassitologia* 2002; 44: 43–57.
- Romig T. Epidemiology of echinococcosis. *Langenbecks Arch Surg* 2003; 388: 209–217.
- Wahlers K, Menezes CN, Wong ML, *et al.* Cystic echinococcosis in sub-Saharan Africa. *Lancet Infect Dis* 2012; 12: 871–880.
- Wahlers K, Menezes CN, Romig T, *et al.* Cystic echinococcosis in South Africa: the worst yet to come? *Acta Trop* 2013; 128: 1–6.
- Kassem HH. Hydatidosis-echinococcosis in Libya (review article). *J Egypt Soc Parasitol* 2006; 36: 21–26.
- Tashani OA, Zhang LH, Boufana B, *et al.* Epidemiology and strain characteristics of *Echinococcus granulosus* in the Benghazi area of eastern Libya. *Ann Trop Med Parasitol* 2002; 96: 369–381.
- Moro P, Schantz PM. Echinococcosis: a review. *Int J Infect Dis* 2009; 13: 125–133.
- Lahmar S, Kilani M, Torgerson PR. Frequency distributions of *Echinococcus granulosus* and other helminths in stray dogs in Tunisia. *Ann Trop Med Parasitol* 2001; 95: 69–76.
- Nonaka N, Kamiya M, Oku Y. Towards the control of *Echinococcus multilocularis* in the definitive host in Japan. *Parasitol Int* 2006; 55: S263–266.
- Aboudaya MA. Prevalence of human hydatidosis in Tripoli region of Libya. *Int J Zoonoses* 1985; 12: 304–307.
- Khan AH, Elsageyer MM, Kidwai SA. Seroprevalence study of human hydatid disease in Libya using finger prick blood samples. *Ann Trop Med Parasitol* 1990; 84: 537–539.
- Shambesh MA, Craig PS, Macpherson CN, *et al.* An extensive ultrasound and serologic study to investigate the prevalence of human cystic echinococcosis in northern Libya. *Am J Trop Med Hyg* 1999; 60: 462–468.
- Abushhewa MH, Abushhiwa MH, Nolan MJ, *et al.* Genetic classification of *Echinococcus granulosus* cysts from humans, cattle and camels in Libya using mutation scanning-based analysis of mitochondrial loci. *Mol Cell Probes* 2010; 24: 346–351.
- Kumar N, Sehgal R, Goyal K, *et al.* Evaluation of dried blood spots collected on filter paper for serodiagnosis of human hydatidosis by enzyme-linked immunosorbent assay. *Trop Parasitol* 2012; 2: 119–123.
- Carmena D, Benito A, Martínez J, *et al.* Preliminary study of the presence of antibodies against excretory-secretory antigens from protoscoleces of *Echinococcus granulosus* in dogs with intestinal echinococcosis. *Mem Inst Oswaldo Cruz* 2005; 100: 311–317.
- Fotoohi S, Hashemi Tabar GR, *et al.* Serodiagnosis of human hydatidosis with an ELISA developed based on antigens derived from sheep hydatid cysts and comparison with a commercial human ELISA kit. *Asian Pac J Trop Med* 2013; 6: 723–727.
- Rafiei A, Craig PS. The immunodiagnostic potential of protoscoleces antigens in human cystic echinococcosis and the possible influence of parasite strain. *Ann Trop Med Parasitol* 2002; 96: 383–389.
- Nasrieh MA, Abdel-Hafez SK. *Echinococcus granulosus* in Jordan: assessment of various antigenic preparations

- for use in the serodiagnosis of surgically confirmed cases using enzyme assays and the indirect haemagglutination test. *Diagn Microbiol Infect Dis* 2004; 48: 117–123.
20. Yang YR, Craig PS, Vuitton DA, et al. Serological prevalence of echinococcosis and risk factors for infection among children in rural communities of southern Ningxia, China. *Trop Med Int Health* 2008; 13: 1086–1094.
 21. Daryani A, Sharif M, Amouei A, et al. Fertility and viability rates of hydatid cysts in slaughtered animals in the Mazandaran Province, Northern Iran. *Trop Anim Health Prod* 2009; 41: 1701–1705.
 22. World Health Organization (WHO) Informal Working Group. International classification of ultrasound images in cystic echinococcosis for application in clinical and field epidemiological settings. *Acta Trop* 2003; 85: 253–261.
 23. Wang Z, Wang X, Liu X. Echinococcosis in China, a review of the epidemiology of *Echinococcus* spp. *Ecohealth* 2008; 5: 115–126.
 24. Macpherson CN, Bartholomot B, Frider B. Application of ultrasound in diagnosis, treatment, epidemiology, public health and control of *Echinococcus granulosus* and *E. multilocularis*. *Parasitology* 2003; 127: S21–35.
 25. Jenkins DJ, Romig T, Thompson RC. Emergence/re-emergence of *Echinococcus* spp.—a global update. *Int J Parasitol* 2005; 35: 1205–1219.
 26. Rogan MT, Hai WY, Richardson R, et al. Hydatid cysts: does every picture tell a story? *Trends Parasitol* 2006; 22: 431–438.
 27. Moro P, Schantz PM. Echinococcosis: a review. *Int J Infect Dis* 2009; 13: 125–133.
 28. Gavidia CM, Gonzalez AE, Zhang W, et al. Diagnosis of cystic echinococcosis, central Peruvian Highlands. *Emerg Infect Dis* 2008; 14: 260–266.
 29. Ersfeld K, Gasser RB, Craig PS. The immunodiagnostic potential of *Echinococcus granulosus* adult-worm antigens in human cystic echinococcosis. *Parasitol Res* 1997; 83: 90–92.
 30. Carmena D, Martinez J, Benito A, et al. Characterization of excretory-secretory products from protoscoleces of *Echinococcus granulosus* and evaluation of their potential for immunodiagnosis of human cystic echinococcosis. *Parasitology* 2004; 129: 371–378.
 31. Carmena D, Benito A, Eraso E. Antigens for the immunodiagnosis of *Echinococcus granulosus* infection: An update. *Acta Trop* 2006; 98: 74–86.
 32. Zhang W, Li J, McManus DP. Concepts in immunology and diagnosis of hydatid disease. *Clin Microbiol Rev* 2003; 16: 18–36.
 33. Reiterová K, Auer H, Altintaš N, et al. Evaluation of purified antigen fraction in the immunodiagnosis of cystic echinococcosis. *Parasitol Res* 2014; 113: 2861–2867.
 34. Ben Nouir N, Nuñez S, Gianinazzi C, et al. Assessment of *echinococcus granulosus* somatic protoscolex antigens for serological follow-up of young patients surgically treated for cystic echinococcosis. *J Clin Microbiol* 2008; 46: 1631–1640.
 35. Zhang W, Wen H, Li J, et al. Immunology and immunodiagnosis of cystic echinococcosis: an update. *Clin Dev Immunol* 2012; 2012: 101895.
 36. Abushhewa MH, Abushhiwa MH, Nolan MJ, et al. Genetic classification of *Echinococcus granulosus* cysts from humans, cattle and camels in Libya using mutation scanning-based analysis of mitochondrial loci. *Mol Cell Probes* 2010; 24: 346–351.
 37. Boubaker G, Macchiaroli N, Prada L, et al. A Multiplex PCR for the Simultaneous Detection and Genotyping of the *Echinococcus granulosus* Complex. *PLoS Negl Trop Dis* 2013; 7: e2017.
 38. Lahmar S, Rebaï W, Boufana BS, et al. Cystic echinococcosis in Tunisia: analysis of hydatid cysts that have been surgically removed from patients. *Ann Trop Med Parasitol* 2009; 103: 593–604.
 39. Gebreel AO, Gilles HM, Prescott JE. Studies on the sero-epidemiology of endemic diseases in Libya. I. Echinococcosis in Libya. *Ann Trop Med Parasitol* 1983; 77: 391–397.
 40. Altintas N. Past to present: echinococcosis in Turkey. *Acta Trop* 2003; 85: 105–112.
 41. Seimenis A. Overview of the epidemiological situation on echinococcosis in the Mediterranean region. *Acta Trop* 2003; 85: 191–195.
 42. Kebede W, Hagos A, Girma Z, et al. Echinococcosis/hydatidosis: its prevalence, economic and public health significance in Tigray region, North Ethiopia. *Trop Anim Health Prod* 2009; 41: 865–871.
 43. McManus DP, Zhang W, Li J, et al. Echinococcosis. *Lancet* 2003; 362: 1295–1304.
 44. Fotiou V, Malissiova E, Minas A, et al. Seroprevalence of IgG antibodies against *Echinococcus granulosus* in the population of the region of Thessaly, Central Greece. *PLoS One* 2012; 7: e37112.
 45. Torgerson PR, Karaeva RR, Corkeri N, et al. Human cystic echinococcosis in Kyrgyzstan: an epidemiological study. *Acta Trop* 2003; 85: 51–61.
 46. Conchedda M, Antonelli A, Caddori A, et al. A retrospective analysis of human cystic echinococcosis in Sardinia (Italy), an endemic Mediterranean region, from 2001 to 2005. *Parasitol Int* 2010; 59: 454–459.
 47. Perdomo R, Alvarez C, Monti J, et al. Principles of the surgical approach in human liver cystic echinococcosis. *Acta Trop* 1997; 64: 109–122.
 48. Cohen H, Paolillo E, Bonifacino R, et al. Human cystic echinococcosis in a Uruguayan community: a sonographic, serologic, and epidemiologic study. *Am J Trop Med Hyg* 1998; 59: 620–627.
 49. Alghoury A, El-Hamshary E, Azazy A, et al. Hydatid Disease in Yemeni Patients attending Public and Private Hospitals in Sana'a City, Yemen. *Oman Med J* 2010; 25: 88–90.
 50. Vlad DC, Neghina AM, Dumitrascu V, et al. Cystic echinococcosis in children and adults: a seven-year comparative study in western Romania. *Foodborne Pathog Dis* 2013; 10: 189–195.