

# The Efficacy of Resin Infiltrant and Casein Phosphopeptide–amorphous Calcium Fluoride Phosphate in Treatment of White Spot Lesions (Comparative Study)

Hussain A. Baafif, Ibrahim F. Alibrahim, Sami H. Alotaibi, Hatem G. Alharbi, Meshal N. Shubaily, Wahdan M. A. Elkhwatehy<sup>1</sup>

Faculty of Dentistry,  
Umm AlQura University,  
<sup>1</sup>Dental Public Health  
and Preventive Dentistry,  
Faculty of Dentistry, Umm  
Al-Qura University, KSA  
and Faculty of Dentistry,  
Mansoura University,  
Egypt

Received : 06-12-19  
Revised : 08-01-20  
Accepted : 09-01-20  
Published : 06-08-20

## ABSTRACT

**Background:** White spot lesions (WSLs) are considered as the first sign of the progression of dental caries that can be reversed. Casein phosphopeptide–amorphous calcium fluoride phosphate (CPP-ACFP) varnish can promote remineralization process of the demineralized tooth structure. Also, WSLs can be managed by using caries infiltrant (ICON), which infiltrates etched enamel surface of the WSLs. **Objectives:** The main aim was to evaluate and compare the efficacy of ICON versus CPP-ACFP varnish to treat WSLs in the same oral environments. **Materials and Methods:** A total of 30 participants aged 20–40 years with at least two WSLs have participated in this trial. Split-mouth technique has been used in this trial where WSLs on the left side have been treated with ICON, whereas WSLs on the right side have been treated with CPP-ACFP varnish. Clinical evaluation using DIAGNOdent was carried out at baseline, 1 week, 1, 3, 6, and 12 months after application to determine the effectiveness of these materials in treating WSLs. **Results:** Significant differences were observed between all follow-up DIAGNOdent scores compared to baseline readings of both ICON and CPP-ACFP ( $P = 0.000$  for all comparisons). Statistically significant differences were observed between DIAGNOdent scores of ICON compared to CPP-ACFP at all follow-up intervals ( $P = 0.006, 0.008, 0.045, 0.036,$  and  $0.000$ ). **Conclusion:** Both ICON and CPP-ACFP were effective in the treatment of WSLs of smooth surfaces but the efficacy of CPP-ACFP was better than ICON.

**KEYWORDS:** Caries infiltrant, casein phosphopeptide–amorphous calcium fluoride phosphate varnish, remineralization, white spot lesions

## INTRODUCTION

At the early stages of dental caries process, the relationship between pathogenic and protective factors is dynamic and thoroughly reversible.<sup>[1]</sup> White spot lesions (WSLs) are considered the first sign of the progression of dental caries and being reversed, they are enamel demineralization without cavitation, these lesions are characterized by white chalky appearance.<sup>[2]</sup> The WSLs can be treated with resin infiltrant<sup>[3]</sup> or remineralizing agents.<sup>[4]</sup>

The caries infiltration product (ICON, DMG Dental Materials, Hamburg, Germany) was introduced in

Germany in 2009, it is widely used for the management of WSLs.<sup>[2,5]</sup> This infiltrant uses a special resin to fill, seal diseased enamel, and prevent the loss of healthy hard tissue by other invasive methods for caries removal, a low viscosity resin infiltrant is soaked into the porous lesion body replacing the lost mineral with resin.<sup>[6]</sup>

**Address for correspondence:** Prof. Wahdan Mohammed Abdelghany Elkhwatehy, Department of Pediatric, Dental Public Health and Preventive Dentistry, Faculty of Dentistry, Mansoura University, Mansoura, Egypt.  
E-mail: elkhwatehywahdan@gmail.com

This is an open access journal, and articles are distributed under the terms of the Creative Commons Attribution-NonCommercial-ShareAlike 4.0 License, which allows others to remix, tweak, and build upon the work non-commercially, as long as appropriate credit is given and the new creations are licensed under the identical terms.

**For reprints contact:** reprints@medknow.com

**How to cite this article:** Baafif HA, Alibrahim IF, Alotaibi SH, Alharbi HG, Shubaily MN, Elkhwatehy WM. The efficacy of resin infiltrant and casein phosphopeptide–amorphous calcium fluoride phosphate in treatment of white spot lesions (comparative study). J Int Soc Prevent Communit Dent 2020;10:438-44.

### Access this article online

#### Quick Response Code:



Website: [www.jispcd.org](http://www.jispcd.org)

DOI: 10.4103/jispcd.JISPCD\_483\_19

The low viscosity resin infiltrates etched enamel surface of the WSL, filling the porosities by penetrating the enamel surface of the WSL, arresting progression of the demineralized lesion, and enhancing the mechanical integrity of the enamel surface.<sup>[7]</sup>

Caries infiltrant has been used for the management of smooth surface lesions interproximally and facially,<sup>[8]</sup> scattered light of the WSL can be reduced by this procedure, thus enhancing the aesthetics and the surface roughness of the filled teeth at distinct treatment times.<sup>[9-13]</sup>

Casein phosphopeptide–amorphous calcium phosphate (CPP-ACP), obtained from milk protein, can promote remineralization process of the demineralized tooth structures.<sup>[14]</sup> The localized anticariogenic property of CPP-ACP is a result of its topical anticariogenic effects due to its capability to maintain the amorphous state of calcium and phosphate.<sup>[15]</sup> For maximally effective remineralization, calcium, phosphate, and fluoride all must be available at sufficient levels in a bioavailable form in the oral environment.<sup>[14,16]</sup>

CPP is a sticky protein that binds and stabilizes calcium and phosphate ions in an amorphous state. CPP-ACFP has been shown to be localized to tooth surfaces, and during acidogenic challenges, it may release calcium, phosphate, and fluoride, and maintain the supersaturation of calcium and phosphate ions in the vicinity of the tooth surface, and thereby depressing demineralization and enhancing remineralization.<sup>[17]</sup>

Different studies have shown that remineralization potential of CPP-ACP combined with fluoride has been more effective.<sup>[18-20]</sup> Combination of CPP-ACP with fluoride improves the surface microhardness of enamel, and its prolonged use decreases the caries incidence in children.<sup>[21,22]</sup> Recently, a combination of CPP-ACP with fluoride has been introduced as a dental varnish (MI Varnish, GC Corporation, Tokyo, Japan), which showed higher remineralization potential than fluoridated varnish.<sup>[23]</sup>

Very few studies have evaluated the efficacy of this recently introduced varnish, these studies were carried out *in vitro* and for short follow-up intervals, also, to the best of our knowledge, no studies were performed to compare the efficacy of CPP-ACFP and caries infiltrant (ICON) in the treatment of WSLs *in vivo* and for longer follow-up periods. Hence, this study was taken up to evaluate remineralization potential of varnish containing CPP-ACP and fluoride (MI Varnish) and to

compare its effectiveness in the treatment of WSLs on smooth surfaces with that of ICON.

## MATERIALS AND METHODS

### ETHICAL CONSIDERATION AND STUDY DESIGN

This was an *in vivo* comparative clinical study carried out using split-mouth technique. It was conducted at the dental clinic of the Dental Teaching Hospital in Umm Al-Qura University, Saudi Arabia, after obtaining the ethical approval (IRB number 115–18) from institutional ethics committee. The study purpose and procedures were explained to the participants at the beginning of the study, and their participation was voluntary.

### SAMPLE SIZE

The WSLs were the specific target of this study. The sample size was calculated at confidence level of 95% and expected percentages of caries prevention of 80%. The estimated sample was 27, which subsequently increased to 30 pairs of lesions.

### PARTICIPANT INCLUSION CRITERIA

- Adult patients aged 20–40 years, free from the systemic diseases that affect salivary pH
- Patients with fair oral hygiene (mild-to-moderate plaque accumulation)
- Patients with at least one pair of smooth surface WSL (one initial carious lesion in each side), visible with or without prolonged air drying as a distinct visual change in the enamel

### PARTICIPANT EXCLUSION CRITERIA

- Patient with other WSLs such as enamel opacity, enamel hypoplasia, or any developmental defects
- Patient received glass ionomer restorations or any remineralizing agent other than the regular toothpaste during the last 3 months

### SAMPLE SELECTION

All patients seeking dental treatment in the teaching dental hospital at Umm Alqura University were examined for smooth surface WSL. Consent forms, which explained the need for treatment of initial caries and the application procedure, were provided to 72 selected patients who fulfilled the selection criteria. Consent forms were signed with an agreement to participate in this study obtained from 30 male patients who formed the study group.

### MATERIALS

The following two different materials were used in this trial:

1. ICON, it is an infiltrant resin (DMG Dental Materials, Hamburg, Germany)
2. CPP-ACFP, it is a remineralizing agent (MI Varnish a product of GC Corporation, Tokyo, Japan)

#### DATA VALIDITY

Well-trained and calibrated examiner, who was blind to the study design and materials, performed DIAGNOdent scoring at baseline and at different follow-up periods. The stability of measurements was confirmed at the baseline and during different follow-up periods. The intra-examiner consistency of measurements was confirmed through training and calibration of the same evaluator. The consistency of measurements was tested by the  $\kappa$  test, the intra-examiner consistency was found to be 89%.

#### CLINICAL INTERVENTION

The DIAGNOdent baseline scores of WSLs were recorded at baseline. The participants were treated with ICON (on left side) and CPP-ACFP (on right side) according to manufacturer's instructions. After the application of both materials, the DIAGNOdent scores were recorded at different follow-up intervals (1 week, 1, 3, 6, and 12 months after application).

#### DIAGNODENT SCORING

The instrument was calibrated according to manufacturer's instructions. Under cotton roll isolation and after air drying with an air syringe, the DIAGNOdent probe was placed perpendicular to the test site and rotated along the lesion to scan the area completely, three measurements were taken and averaged to give the final test value.

#### ICON INFILTRANT APPLICATION

The targeted WSLs were treated with ICON caries infiltrant as the following: ICON usage involved application of ICON-etch syringe (15% HCl) for 2 min, followed by rinsing with water for 30 s and drying with oil-free and water-free air. The etched surface then desiccated using the ICON dry syringe (99% ethanol) for 30 s, followed by drying with oil-free and water-free air. ICON infiltrant syringe was placed on the targeted surface, and caries resin infiltrant was dispensed. After 3 min, excess infiltrant was wiped using a cotton roll,

and the surface was light cured (430–490 nm, 600 mW/cm<sup>2</sup>) for 40 s. Lastly, the infiltrant was reapplied for 1 min and light cured for 40 s.

#### CASEIN PHOSPHOPEPTIDE–AMORPHOUS CALCIUM FLUORIDE PHOSPHATE APPLICATION

The tooth surfaces containing WSLs were cleaned and dried before application of MI Varnish. Peel off the foil lid of the unit dose container of MI Varnish. Apply a thin, uniform layer of the varnish on teeth surfaces using a disposable brush. The varnish sets when in contact with water or saliva, and it should remain undisturbed on the teeth surfaces for 4 h. Instruct patients to avoid hard, hot, or sticky foods, toothbrushing and flossing, and products containing alcohol (oral rinses, beverages, etc.) during this time.

Every patient was educated and motivated about the importance of oral hygiene and toothbrushing. The DIAGNOdent was used to evaluate the effectiveness of those materials in the treatment of WSL at different follow-up intervals.

#### STATISTICAL ANALYSIS

The collected data were analyzed using a Statistical Package for the Social Sciences software program (IBM SPSS Statistics for Windows, version 21.0, IBM, Armonk, New York). The descriptive data analysis included the mean and standard deviation for baseline and follow-up scores of the DIAGNOdent.

One-way analysis of variance (ANOVA) test was used to evaluate the efficacy of each material by comparing the DIAGNOdent scores at different follow-up intervals. *Post hoc* Tukey test was used for multiple comparisons within each group and to compare between the two materials. The level of significance was considered statistically significant at  $P \leq 0.05$ .

#### RESULTS

The data were analyzed for 28 participants who attended all follow-up intervals. Both ICON and CPP-ACFP have a significant effect in the treatment of WSLs as significant differences were observed among DIAGNOdent baseline scores and different follow-up intervals ( $P = 0.000$  for both groups) [Table 1].

**Table 1: Efficacy of ICON and casein phosphopeptide–amorphous calcium fluoride phosphate in the treatment of white spot lesions**

| Groups   | Follow-up      |               |               |               |               |               | P     |
|----------|----------------|---------------|---------------|---------------|---------------|---------------|-------|
|          | Baseline       | 1 week        | 1 month       | 3 months      | 6 months      | 12 months     |       |
| ICON     | 12.214 ± 2.043 | 3.679 ± 2.539 | 3.429 ± 1.952 | 5.321 ± 1.945 | 6.643 ± 2.297 | 9.607 ± 2.283 | 0.000 |
| CPP-ACFP | 12.250 ± 2.066 | 5.786 ± 2.200 | 5.500 ± 1.347 | 4.357 ± 1.545 | 5.821 ± 1.294 | 5.893 ± 1.286 | 0.000 |

P = P value calculated by one-way analysis of variance (ANOVA) test

Regarding the efficacy of ICON, the DIAGNOdent scores were significantly decreased at all follow-up intervals compared to baseline scores ( $P = 0.000$  for all follow-up comparisons with baseline scores).

**Table 2: Multiple comparison among DIAGNOdent scores at different follow-up intervals**

| Comparison             | Groups           |                      |
|------------------------|------------------|----------------------|
|                        | ICON<br><i>P</i> | CPP-ACFP<br><i>P</i> |
| Baseline vs. 1 week    | 0.000*           | 0.000*               |
| Baseline vs. 1 month   | 0.000*           | 0.000*               |
| Baseline vs. 3 months  | 0.000*           | 0.000*               |
| Baseline vs. 6 months  | 0.000*           | 0.000*               |
| Baseline vs. 12 months | 0.000*           | 0.000*               |
| 1 week vs. 1 month     | 0.998            | 0.992                |
| 1 week vs. 3 months    | 0.061            | 0.064                |
| 1 week vs. 6 months    | 0.000*           | 1.000                |
| 1 week vs. 12 months   | 0.000*           | 1.000                |
| 1 month vs. 3 months   | 0.018*           | 0.189                |
| 1 month vs. 6 months   | 0.000*           | 0.986                |
| 1 month vs. 12 months  | 0.000*           | 0.967                |
| 3 months vs. 6 months  | 0.216            | 0.038*               |
| 3 months vs. 12 months | 0.000*           | 0.025*               |
| 6 months vs. 12 months | 0.000*           | 1.000                |

ICON *P* and CPP-ACFP *P* = *P* value calculated by *post hoc* Tukey test

\*denotes statistically significant value

Comparison between 1 week and other follow-up scores revealed that the DIAGNOdent scores were nearly similar at 1st week and 1 month ( $P = 0.998$ ), nonsignificantly increased at 3 month ( $P = 0.061$ ), and significantly increased at 6- and 12-month follow-up ( $P = 0.000$ ). Also, significant differences were observed between the 1-month scores compared to 3-, 6-, and 12-month scores ( $P = 0.000$ ,  $P = 0.000$ , and  $P = 0.018$ , respectively). Statistically nonsignificant difference was observed between 3- and 6-month scores ( $P = 0.216$ ), whereas the differences were significant between 3 and 6 months compared to 12-month scores ( $P = 0.000$  for both) [Tables 1 and 2].

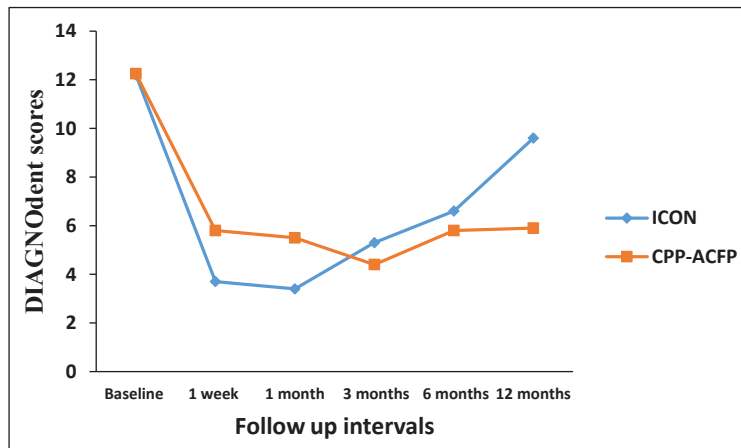
In relation to the efficacy of CPP-ACFP, the DIAGNOdent scores were significantly decreased at all follow-up intervals compared to baseline scores ( $P = 0.000$  for all comparisons). Comparison between 1 week and other follow-up scores revealed that the DIAGNOdent scores gradually decreased until 3 months, then slightly increased during 6- and 12-month follow-up [Table 1]. No significant differences were observed between 1-week follow-up score compared with 1-, 3-, 6-, and 12-month follow-up scores ( $P = 0.992$ ,  $P = 0.064$ ,  $P = 1.000$ , and  $P = 1.000$ , respectively). Also, no significant differences were observed between 1-month scores compared with 3-, 6-, and 12-month scores ( $P = 0.189$ ,  $P = 0.986$  and

**Table 3: Comparison between the efficacy of ICON and casein phosphopeptide–amorphous calcium fluoride phosphate in the treatment of white spot lesions**

| Groups   | Follow-up      |               |               |               |               |               |
|----------|----------------|---------------|---------------|---------------|---------------|---------------|
|          | Baseline       | 1 week        | 1 month       | 3 months      | 6 months      | 12 months     |
| ICON     | 12.214 ± 2.043 | 3.679 ± 2.539 | 3.429 ± 1.952 | 5.321 ± 1.945 | 6.643 ± 2.297 | 9.607 ± 2.283 |
| CPP-ACFP | 12.250 ± 2.066 | 5.786 ± 2.200 | 5.500 ± 1.347 | 4.357 ± 1.545 | 5.821 ± 1.294 | 5.893 ± 1.286 |
| <i>P</i> | 0.948          | 0.006*        | 0.008*        | 0.045*        | 0.036*        | 0.000*        |

*P* = *P* value calculated by *post hoc* Tukey test.

\*denotes statistically significant value.



**Graph 1: Efficacy of ICON and casein phosphopeptide–amorphous calcium fluoride phosphate in treatment of initial caries**

$P = 0.967$  respectively). Significant differences were reported between 3-month follow-up score compared with 6- and 12-month follow-up scores ( $P = 0.038$  and  $P = 0.025$ ), whereas no significant difference was observed between 6- and 12-month follow-up scores ( $P = 1.000$ ) [Table 1 and 2].

No significant difference was observed between ICON group and CPP-ACFP group at baseline readings ( $P = 0.948$ ). At 1-week and 1-month follow-up, DIAGNOdent scores of ICON group were significantly less than CPP-ACFP scores ( $P = 0.006$  and  $P = 0.008$ ). On the contrary, at 3-, 6-, and 12-months follow-up, DIAGNOdent scores of ICON group were significantly higher than CPP-ACFP scores ( $P = 0.045$ ,  $P = 0.036$ , and  $P = 0.000$ , respectively) [Table 3].

## DISCUSSION

Arresting dental caries in early stages is highly important, and there are different methods for the treatment of initial caries. In recent years, remineralization of the WSLs using topical products (such as CPP-ACFP varnish) and minimally invasive techniques (such as resin infiltration) has been introduced.<sup>[23,24]</sup> This study was carried out to evaluate and compare their effectiveness in clinical practice. In this study, every participant received ICON on one side and CPP-ACFP on the other side of the same patient to ensure equality in all factors, which may affect the results.

In this study, the DIAGNOdent device was used to evaluate the effectiveness of these materials because it is an objective accurate method of detecting initial carious lesions as compared to the visual and radiographic examination.<sup>[25]</sup> The DIAGNOdent laser fluorescence unit takes advantage of the fact that the light-reflecting and fluorescing properties of normal, healthy enamel differs from the characteristics of the enamel surfaces attacked by dental caries.<sup>[26]</sup>

The finding of this study indicated that the use of resin infiltration for treatment of WSLs is effective for 6-month period as significant differences were observed between baseline scores and all follow-up scores, these results are in consonance with the results of previous studies.<sup>[27,28]</sup>

Although significant differences were observed between baseline scores and all follow-up intervals scores, the results showed marked increase in DIAGNOdent scores at the 3-, 6-, and 12-month follow-up [Table 1], this may be due to degradation and dissolution of the infiltrant in oral fluids after long periods. The results of previous studies concluded that infiltrant showed a higher extent of oxygen inhibition, lower hardness, lower elastic

modulus, and higher plastic to elastic indentation energy. These inferior properties may reduce the sealing capacity, mechanical strength, and durability of the intraorally exposed part of the infiltrant coating.<sup>[29,30]</sup>

The results of this study indicated that CPP-ACFP varnish has highly potential remineralizing effect on WSLs of smooth surfaces [Table 1]. These results support the previous studies, which concluded that CPP-ACP when used in combination with fluoride has higher remineralization potential than when used alone.<sup>[31,32]</sup> The increased remineralization potential may be due to increased bioavailability of calcium, phosphate, and fluoride ions to the tooth surface, which promotes remineralization of carious lesions.<sup>[23]</sup>

The results of this study confirm the stable remineralizing effect of CPP-ACFP as the DIAGNOdent scores of CPP-ACFP group were somewhat near each other at the different follow-up intervals (no significant differences between 1 week and 1-, 3-, 6-, and 12-month follow-up scores [Table 2]) and significantly less than the baseline scores. This difference may be shown by the addition of fluoride to CPP-ACFP, which enhances remineralization and at the same time stabilizes the remineralized lesions for long periods due to formation of fluorapatite crystals, these results agreed with the results of the previous studies, which concluded that the addition of fluoride to CPP-ACFP leads to increased incorporation of ions into smooth subsurface enamel lesions and substantially increases remineralization of subsurface lesions compared to fluoride alone.<sup>[33,34]</sup>

In this study, single application on CPP-ACFP produces acceptable remineralizing effect for 12 months, and these findings support the results obtained by Savas *et al.*,<sup>[35]</sup> who observed that CPP-ACFP-containing fluoride varnish (MI Varnish) provides remineralization of incipient carious lesions after a single application and suggested that it may be suitable for clinical use.

The results of this study confirmed that CPP-ACFP varnish is highly effective than ICON in treatment of WSLs as the DIAGNOdent scores starts to markedly increased at the 3, 6 and 12 months follow-up in ICON group while start to increase gradually at the 6-month follow-up and remain somewhat constant till 12-month follow-up in CPP-ACFP group and the DIAGNOdent scores were significantly less than those of ICON at the last three follow-up intervals [Table 3]. These results suggested that the treatment of initial carious lesions with remineralizing agent (CPP-ACFP) is better than the treatment with caries infiltrant (ICON) as its effect

extended for long period and produced more stable remineralizing effect [Graph 1].

## CONCLUSION

Both agents were effective in treating WSLs but the CPP-ACFP varnish was more effective as its effect extended to longer period.

## RECOMMENDATIONS

CPP-ACFP varnish is highly recommended for the treatment of white spot carious lesions.

## ACKNOWLEDGEMENTS

Nil.

## FINANCIAL SUPPORT AND SPONSORSHIP

Nil.

## CONFLICTS OF INTEREST

There are no conflicts of interest.

## AUTHOR CONTRIBUTIONS

AlOtaibi S. carried out clinical examination and application of infiltrant and varnish, Alharbi H. perform DIAGNodent scoring at baseline and follow up, Baafif H. and Alibrahim A. performed the analysis and wrote the first draft of this paper, Shubaily M. collect previous studies and help in writing the first draft of the paper, Elkwehly W. revised and approved the final version. All authors have read and approved the final manuscript.

## ETHICAL POLICY AND INSTITUTIONAL REVIEW BOARD STATEMENT

The study was approved by the Institutional Review Board (IRB), College of Dentistry, Umm AlQura University. Registration Number: (115 – 18) in January, 2019 and all the procedures have been performed as per the ethical guidelines laid down by Declaration of Helsinki (2000).

## PATIENT DECLARATION OF CONSENT

The study purpose and procedures were explained to the participants at the beginning of the study and their participation was voluntary.

## DATA AVAILABILITY STATEMENT

Data used to support the findings of this study are available from the corresponding author upon request.

## REFERENCES

- Pitts NB, Zero DT, Marsh PD *et al.* Dental caries. *Nat Rev Dis Primers* 2017;3:17030.
- Paula AB, Fernandes AR, Coelho AS, Marto CM, Ferreira MM, Caramelo F, *et al.* Therapies for white spot lesions—A systematic review. *J Evid Based Dent Pract* 2017;17: 23-38.
- Paris S, Schwendicke F, Keltch J, Dörfer C, Meyer-Lueckel H. Masking of white spot lesions by resin infiltration *in vitro*. *J Dent* 2013;41:e28-34.
- Vashisht R, Indira R, Ramachandran S, Kumar A, Srinivasan MR. Role of casein phosphopeptide amorphous calcium phosphate in remineralization of white spot lesions and inhibition of *Streptococcus mutans*? *J Conserv Dent* 2013;16:342-6.
- Phark J, Duarte J, Meyer-Lueckel H, Paris S. Caries infiltration with resins: A novel treatment option for inter proximal caries. *Comp Cont Edu Dent* 2009;30:13-7.
- Paris S, Meyer-Lueckel H. Inhibition of caries progression by resin infiltration *in situ*. *Caries Res* 2010;44:47-54.
- Paris S, Schwendicke F, Seddig S, Müller WD, Dörfer C, Meyer-Lueckel H. Micro-hardness and mineral loss of enamel lesions after infiltration with various resins: Influence of infiltrant composition and application frequency *in vitro*. *J Dent* 2013;41:543-8.
- Ekstrand K, Martignon S, Bakhshandeh A, Ricketts DN. The non-operative resin treatment of proximal caries lesions. *Dent Update* 2012;39:614-6, 618-20, 622.
- Paris S, Meyer-Lueckel H. Masking of labial enamel white spot lesions by resin infiltration—A clinical report. *Quintessence Int* 2009;40:713-8.
- Rocha Gomes Torres C, Borges AB, Torres LM, Gomes IS, de Oliveira RS. Effect of caries infiltration technique and fluoride therapy on the colour masking of white spot lesions. *J Dent* 2011;39:202-7.
- Hallgren K, Akyalcin S, English J, Tufekci E, Paravina RD. Color properties of demineralized enamel surfaces treated with a resin infiltration system. *J Esthet Restor Dent* 2016;28:339-46.
- Abbas B, Marzouk E, Zaher A. Treatment of various degrees of white spot lesions using resin infiltration—*In vitro* study. *Progress Orthodont* 2018;19:19-27.
- Mohamed AM, Wong KH, Lee WJ, Marizan Nor M, Mohd Hussaini H, Rosli TI. *In vitro* study of white spot lesion: Maxilla and mandibular teeth. *Saudi Dent J* 2018;30:142-50.
- Reynolds EC. Casein phosphopeptide-amorphous calcium phosphate: The scientific evidence. *Adv Dent Res* 2009;21:25-9.
- Hegde M, Shetty S, Pardal D. Remineralization of enamel subsurface lesion using casein phosphopeptide amorphous calcium phosphate (CPP-ACP)—A quantitative energy dispersive X-ray analysis (EDAX). *J Cons Dent* 2007;10:19-25.
- ten Cate JM. Remineralization of deep enamel dentine caries lesions. *Aust Dent J* 2008;53:281-5.
- Walsh LJ. Evidence that demands a verdict: Latest developments in remineralization therapies. *Australas Dent Pract* 2009;24:48-59.
- Cochrane NJ, Saranathan S, Cai F, Cross KJ, Reynolds EC. Enamel subsurface lesion remineralisation with casein phosphopeptide stabilised solutions of calcium, phosphate and fluoride. *Caries Res* 2008;42:88-97.
- Srinivasan N, Kavitha M, Loganathan SC. Comparison of the remineralization potential of CPP-ACP and CPP-ACP with 900ppm fluoride on eroded human enamel: An *in situ* study. *Arch Oral Biol* 2010;55:541-4.
- Wu G, Liu X, Hou Y. Analysis of the effect of CPP-ACP tooth mousse on enamel remineralization by circularly polarized images. *Angle Orthod* 2010;80:933-8.
- Huang GJ, Roloff-Chiang B, Mills BE, Shalchi S, Spiekerman C, Korpak AM, *et al.* Effectiveness of MI paste plus and preventid fluoride varnish for treatment of white spot lesions: A randomized controlled trial. *Am J Orthod Dentofacial Orthop* 2013;143:31-41.
- Memarpour M, Fakhraei E, Dadaein S, Vossoughi M. Efficacy of fluoride varnish and casein phosphopeptide-amorphous calcium phosphate for remineralization of primary

- teeth: A randomized clinical trial. *Med Princ Pract* 2015;24:231-7.
23. Babu KL, Subramaniam P, Teleti S. Remineralization potential of varnish containing casein phosphopeptides-amorphous calcium phosphate with fluoride and varnish containing only fluoride: A comparative study. *Saudi J Oral Sci* 2018;5:35-40.
  24. Walsh LJ, Brostek AM. Minimum intervention dentistry principles and objectives. *Aust Dent J* 2013;58:3-16.
  25. Lussi A, Hibst R, Paulus R. DIAGNOdent: an optical method for caries detection. *J Dent Res* 2004;83:80-83.
  26. Moriyama CM, Rodrigues JA, Lussi A, Diniz MB. Effectiveness of fluorescence-based methods to detect *in situ* demineralization and remineralization on smooth surfaces. *Caries Res* 2014;48:507-14.
  27. Chatzimarkou S, Koletsi D, Kavvadia K. The effect of resin infiltration on proximal caries lesions in primary and permanent teeth. A systematic review and meta-analysis of clinical trials. *J Dent* 2018;77:8-17.
  28. Faghihian R, Shirani M, Tarrahi MJ, Zakizade M. Efficacy of the resin infiltration technique in preventing initial caries progression: A systematic review and meta-analysis. *Pediatr Dent* 2019;41:88-94.
  29. Paris S, Bitter K, Naumann M, Dörfer CE, Meyer-Lueckel H. Resin infiltration of proximal caries lesions differing in ICDAS codes. *Eur J Oral Sci* 2011;119:182-6.
  30. Rahiotis C, Zinelis S, Eliades G, Eliades T. Setting characteristics of a resin infiltration system for incipient caries treatment. *J Dent* 2015;43:715-9.
  31. Kumar VL, Itthagaran A, King NM. The effect of casein phosphopeptide-amorphous calcium phosphate on remineralization of artificial caries-like lesions: An *in vitro* study. *Aust Dent J* 2008;53:34-40.
  32. Mendes AC, Restrepo M, Bussaneli D, Zuanon AC. Use of casein amorphous calcium phosphate (CPP-ACP) on white-spot lesions: Randomised clinical trial. *Oral Health Prev Dent* 2018;16:27-31.
  33. Tyagi SP, Garg P, Sinha DJ, Singh UP. An update on remineralizing agents. *J Interdiscip Dent* 2013;3:151-5.
  34. Llana C, Leyda AM, Forner L. CPP-ACP and CPP-ACFP versus fluoride varnish in remineralisation of early caries lesions. A prospective study. *Eur J Paediatr Dent* 2015;16:181-6.
  35. Savas S, Kavrik F, Kucukyilmaz E. Evaluation of the remineralization capacity of CPP-ACP containing fluoride varnish by different quantitative methods. *J Appl Oral Sci* 2016;24:198-203.