

Reducing the Cleft Nose Deformity in Bilateral Cleft Lip Repair

Nicolas S. Dhooghe, MD*
David K. Chong, MBBS, FRACS†

Summary: Repair of a bilateral cleft lip and nose deformity remains a challenge. The nose remains the main persisting stigma for patients, deserving an equal amount of attention as the lip during the repair. We share 3 technical principles to help achieve the optimal nasolabial result and minimize cleft nose deformity after bilateral cleft lip repair. Firstly, cephalad rotation of C-flaps from the prolabium is used to define the nasolabial angle. Secondly, the nasal base and contour is set before the lip repair, as the vectors and tension of nasal repair differ from the vector and tension of the orbicularis oris muscle closure. Thirdly, different suspension and shaping stitches are used to define alar shape and position after lower lateral cartilage release, avoiding additional scars. (*Plast Reconstr Surg Glob Open* 2020;8:e3325; doi: [10.1097/GOX.0000000000003325](https://doi.org/10.1097/GOX.0000000000003325); Published online 17 December 2020.)

INTRODUCTION

Bilateral cleft lip repair remains one of the great challenges in cleft surgery. The deformity can present itself in a range of severities. The nose remains the main stigma for patients with complete bilateral cleft presentations. The main anatomical issues lie with the short columella, the protruding premaxilla, and the splayed alars.

Surgeons differ in opinion regarding the amount of intervention at primary lip repair. Some will do minimal work on the nose at the time of lip repair, preferring to defer surgery to later in life when the cartilages are more developed. Others are more aggressive, attempting to delineate the lower lateral cartilages through various incisions and shape the diminutive cartilages with direct suture fixation techniques.¹

This technique paper aims to share principles to help achieve a good three-dimensional nasolabial repair, minimizing the cleft nose deformity. (See figure, **Supplemental Digital Content 1**, which displays front and sideview pictures of a bilateral cleft lip repair using the techniques described in this paper. <http://links.lww.com/PRSGO/B567>.) The technical principles presented are not necessarily new, though the discussion of the techniques,

together with the order of the surgery, may be of benefit to the cleft surgeon and their patients.

SURGICAL TECHNIQUE

We address the cleft nose deformity at the time of lip repair, avoiding external nasal incisions and damage that may complicate later interventions. Firstly, we note that the labial-columellar angle is often obtuse following most bilateral lip repairs, with little break between the columellar and philtral column subunits. We use the cephalad rotation of the c-flaps to assist us in better defining this angle.

We mark 2 semi-circular C-flaps on each side of the philtral tie. These flaps will be rotated between 90 and 150 degrees into the nostril and create a more acute angle between the lip and the columella. This creates excess skin in the nostril sill which can either be tucked into the nostril during the repair or trimmed as necessary (Fig. 1). We also attempt to use this tissue to resemble the medial footplate splay of the base of the columella.

Secondly, we note that the position of alar bases following traditional bilateral lip repairs are often displaced. The alar bases move in a cephalad direction with approximation of the orbicularis muscle. The tension of the orbicularis repair alone is insufficient to cinch the nose to its correct relationship. In short, the vector and tension of alar base closure differs from the vector and tension of the orbicularis muscle closure (Fig. 2).

To achieve the optimal correction of the cleft nasal deformity, the nasal base and contour should be set before orbicularis closure. One achieves this with the use

From the *Department of Plastic, Reconstructive and Aesthetic Surgery, Ghent University Hospital, Ghent, Belgium; and †Plastic and Maxillofacial Surgery Department, Royal Children's Hospital, Melbourne, Australia.

Received for publication September 30, 2020; accepted October 28, 2020.

Copyright © 2020 The Authors. Published by Wolters Kluwer Health, Inc. on behalf of The American Society of Plastic Surgeons. All rights reserved. This is an open-access article distributed under the terms of the [Creative Commons Attribution-Non Commercial-No Derivatives License 4.0 \(CCBY-NC-ND\)](https://creativecommons.org/licenses/by-nc-nd/4.0/), where it is permissible to download and share the work provided it is properly cited. The work cannot be changed in any way or used commercially without permission from the journal.

DOI: [10.1097/GOX.0000000000003325](https://doi.org/10.1097/GOX.0000000000003325)

Disclosure: The authors have no financial interest to declare in relation to the content of this article. This study did not receive any financial support.

Related Digital Media are available in the full-text version of the article on www.PRSGlobalOpen.com.

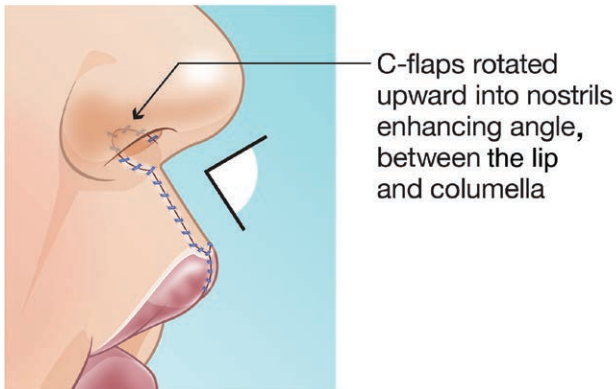


Fig. 1. Cephalad rotation of C-flaps helps to enhance the angle between the lip and columella.

of a cinching suture and is a most important maneuver to achieve before any attempt to close the lip. This recognizes that the alar base must be set such that subsequent orbicularis closure will not distort the alar base position. Often the vector to set the alar base closure requires a caudal movement and subsequent setting of the bases. A cinching suture involves suturing the nasalis muscle at the base of each alar and bringing them towards each other. If a still more caudal vector is required, one can fixate the alar by suturing it to the premaxilla. We do this by suturing the soft tissue at the base of the alar to the periosteum of the premaxilla with a slow resorbable suture. If this more caudal vector is required, the prolabial vermilion flap (creating the sulcus) may have to be taken down or delayed to allow access to the periosteum over the premaxilla (Fig. 2).

Finally, we use a largely closed approach to nasal shaping. We agree that the cartilages are too delicate to attempt to do significant dissection and to influence the shape. When one looks at the precise techniques required in alar cartilages in definitive rhinoplasty at growth completion, it seems difficult to us to expect that manipulation of infantile cartilage will not have deleterious effects.

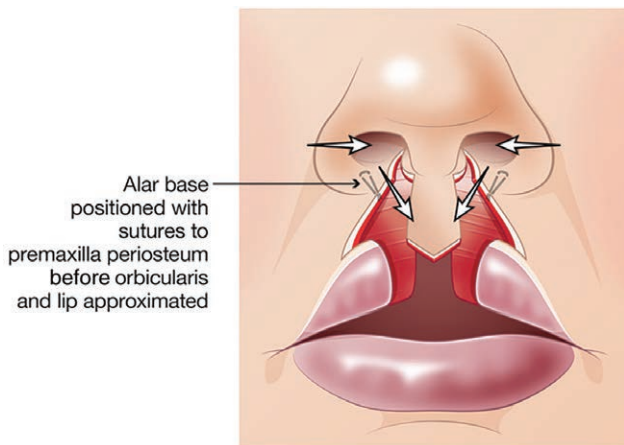


Fig. 2. Setting the position of the alar bases with sutures to the periosteum of the premaxilla or with a cinch stitch, before closure of the lip elements. The vectors for nasal repair are different from the vectors of orbicularis and lip closure.

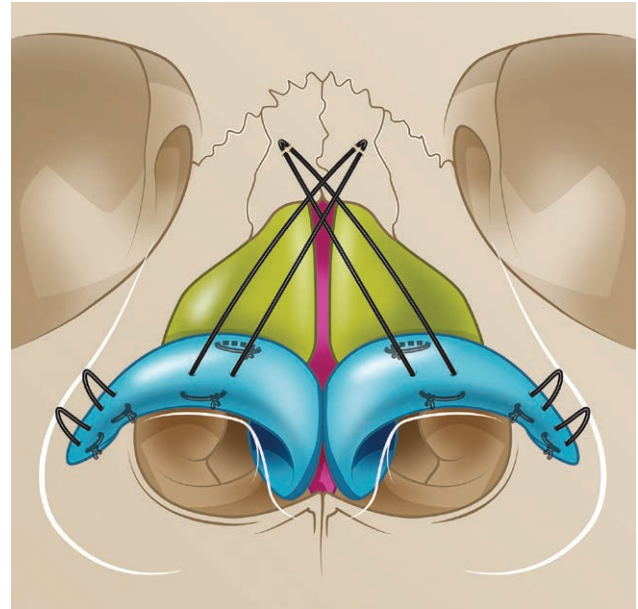


Fig. 3. Different sutures used for shaping and suspension of the nasal cartilage.

Our cartilaginous manipulations consists of release of the lower lateral nasal cartilage from the piriform aperture, and closed dissection between the skin and cartilage, based on the influence of Drs. McComb and Salzer.^{2,3} The nose is then shaped with stitches (Fig. 3).

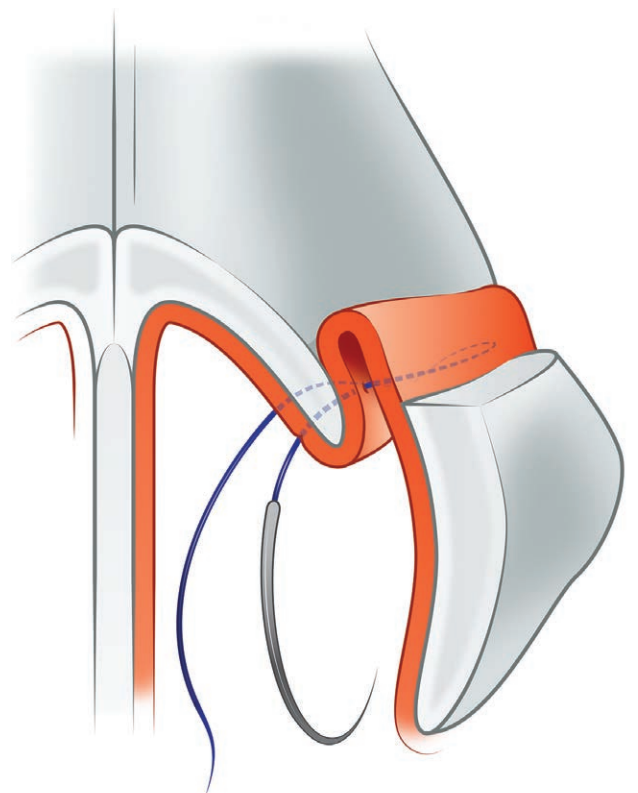


Fig. 4. Raising the lower lateral cartilage by suspension suture of the mucosa to the upper lateral cartilage.

The first suture elevates the lower lateral cartilage in relation to the upper lateral. The suture is placed through the nasal mucosa as a horizontal mattress suture. The Lower lateral is elevated in relation to the upper lateral and then a suture is placed within the groove between the upper and lower lateral so as to indirectly raise the lateral crus of the lower lateral in a cephalic direction. Please note that the lower lateral itself is not directly sutured (Fig. 4).

We then place 2 suspension stitches, suspending the lower laterals to the periosteum of the nasal bone and creating projection of the nasal tip. We use a 23-G hypodermic needle we curve to create the right contour, such that the first pass of the needle passes through the skin of the upper third of the nose, collects the nasal bone periosteum or upper lateral cartilage, before passing through the lower lateral cartilage. We then pass a 4-0 PDS suture through the needle. The needle is then withdrawn almost out of the skin at its entry point, and then redirected to pass through the lower lateral again and, when tied, will create a more normal nostril contour. This creates a suspension suture which is more robust than sutures tied over a pledget, or suspended to dermis. Finally, the alar rims are refined by placing sutures to eliminate dead space and define alar contour (Fig. 3). Nasal stents are placed in the

nostrils to keep them in the desired shape during the healing process.

CONCLUSIONS

Reconstruction of the bilateral cleft nose remains one of the great challenges of cleft surgery. We share simple techniques to change the paradigm of the nasal repair by defining the labial-columellar angle with upward rotating C-flaps from the prolabium, setting the position of the alar bases before orbicularis closure and performing cartilage release in combination with shaping and suspension stitches to define alar shape.

David K. Chong, MBBS, FRACS

50 Flemington Rd, Parkville
VIC 3052, Australia

E-mail: davidkchong@gmail.com

REFERENCES

1. Henry C, Samson T, Mackay D. Evidence-based medicine: the cleft lip nasal deformity. *Plast Reconstr Surg*. 2014;133:1276–1288.
2. Salyer KE. Primary correction of the unilateral cleft lip nose: a 15-year experience. *Plast Reconstr Surg*. 1986;77:558–568.
3. McComb H. Primary repair of the bilateral cleft lip nose: a 15-year review and a new treatment plan. *Plast Reconstr Surg*. 1990;86:882–889.