

Sudden endotracheal tube block in a patient of Achalasia Cardia

Ajit Gupta, Kishor, Vinit Kumar Thakur, Arvind Kumar

Department of Anesthesiology and Critical Care, Indira Gandhi Institute of Medical Sciences, Patna, Bihar, India

Abstract

Endotracheal tube block due to various mechanical causes such as mucous, blood clot, denture, and ampoules have been reported. A patient of achalasia cardia with chronic passive aspiration pneumonitis developed mucoid mass in the respiratory passage which dislodged during the surgical procedure. The episode occurred almost an hour after induction of anesthesia and the dislodged mucoid mass blocked the lumen of endotracheal tube, leading to hypoxia and impending cardiac arrest. However, the patient was salvaged by replacing the tube.

Key words: Achalasia cardia, aspiration, endotracheal tube, passive, pneumonitis

Introduction

Achalasia cardia may cause chronic passive aspiration and varying degree of respiratory tract inflammation/pathology. Associated dehydration, malnutrition, and poor bronchial ciliary movement may lead to formation of tenacious mucous secretions that can block endotracheal tube (ETT) perioperatively.^[1] Blockage of the endotracheal or tracheostomy tube lumen can jeopardize ventilation and can be fatal.^[2,3] In children, ETTs have narrow lumen and are more prone to obstruction.

Case Report

A 10-kg 7-year-boy, a diagnosed case of Achalasia Cardia, was scheduled for Heller's myotomy. The patient was cachectic, dehydrated, and had past history of frequent chest infection and fever. On hospitalization, he was treated with antibiotics,

cough expectorants, steam inhalation, and chest physiotherapy. Complete blood counts and biochemistry were within normal. Barium Swallow was suggestive of Achalasia Cardia [Figure 1]. Two days prior to surgery a nasogastric tube was passed to evacuate and lavage the dilated esophagus. The patient was adequately hydrated with intravenous (IV) fluids.

Anesthesia was induced with IV fentanyl, propofol, and atracurium. The trachea was intubated with a 5.5-mm ID cuffed ETT. Lungs were ventilated with oxygen only and no nitrous oxide or inhalational anesthetic agent was used. The bag-mask ventilation was easy and no difficulty was encountered. Bilateral chest auscultation after endotracheal intubation revealed bilateral uniform ventilation without evidence of secretions. Anesthesia was maintained with

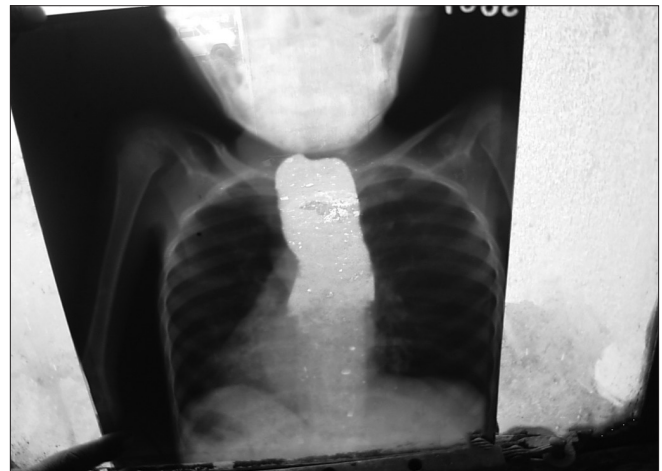


Figure 1: Chest X-ray showing achalasia cardia

Address for correspondence: Dr. Ajit Gupta,
Department of Anesthesiology and Critical Care, Indira Gandhi
Institute of Medical Sciences, Patna – 800 023, Bihar, India.
E-mail: ajpta_igims@yahoo.co.uk

Access this article online

Quick Response Code:



Website:
www.joacp.org

DOI:
10.4103/0970-9185.98353

oxygen, nitrous oxide, and halothane, by manual ventilation, using nonrebreathing circuit.

The surgical procedure was conducted via a left subcostal abdominal approach. Monitoring of electrocardiogram (ECG), peripheral oxygen saturation (SpO₂), capnograph, and noninvasive blood pressure was done. The procedure continued uneventfully for an hour. Thereafter, suddenly during manual ventilation the reservoir bag was difficult to press, and consequently, there was no air entry in the lungs. A quick check was made to find the cause. No twist at the neck of bag, no kinking of ETT, blockage or foreign body impaction in the ventilating circuit, or fault in anesthesia machine could be identified. SpO₂ dropped to 23% and the capnograph showed flat tracing and this was followed by bradycardia. Suspecting a blockage of the ETT, passing a suction catheter down ETT was attempted, but the desired length could not be passed. Examination of the ETT confirmed the blockage. The ETT was removed and lungs were ventilated with bag/mask. A thick tenacious sheet like structure was found to be blocking Murphy's eye and lower 2 cm of the ETT [Figure 2]. SpO₂ returned to normal and cyanosis disappeared. ECG returned back to normal. After a careful oral suctioning, trachea was reintubated with the same-sized ETT. Surgery was continued and was completed in an hour. Neuromuscular blockade was reversed with neostigmine and glycopyrrolate and trachea extubated. Patient had an uneventful recovery and was discharged home on the 9th postoperative day.

Discussion

ETT block has been reported due to number reasons. Tight bag situation due to impaction resulting from inspissated mucous within the airway causing oxygen desaturation was reported earlier.^[4] Foreign bodies such as teeth, pieces of adenoid, bite on ETT, blood clots, pieces of ampoule, and occlusion of lumen of soft tube due to inflated cuff^[5] are reported causes. The sudden ETT block is difficult to anticipate or predict and may lead to panic. Partial or complete obliteration of lumen may occur, in patients having ETT in position for long, needing a change of ETT to maintain the airway. A mucous plug can get dislodged during induction of anesthesia and mechanical ventilation, and thus, the anesthesia team should be prepared to take care of sudden airway blockade during the conduct of anesthesia.

Achalasia Cardia sometimes presents as prolonged cough and diagnosis is often delayed due to the atypical presentation. It can be a potential cause of recurrent chest infection.^[6,7] In

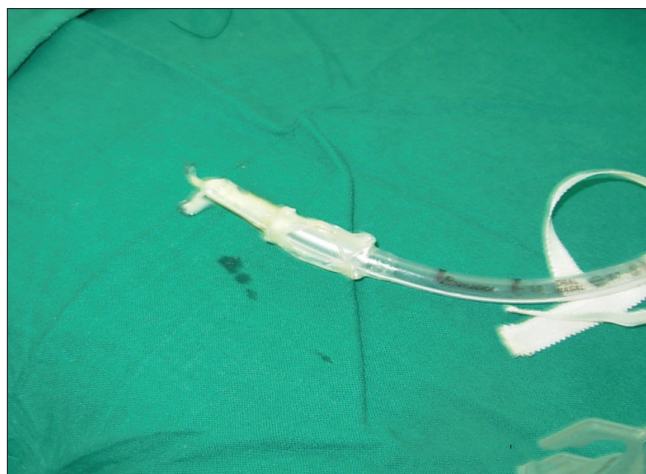


Figure 2: Endotracheal tube with a thick tenacious sheet like structure blocking the Murphy's eye and lower 2 cm

dehydrated sick/unconscious patients with poor intake, there is increased viscosity of mucus and reduced ciliary brush movement leading to inspissation of secretion with increased chances of blockade of the ETT.^[8,9] Regurgitation and aspiration are other possibilities in inadequately prepared cases. Rapid sequence intubation with Sellick's maneuver application or use of awake fiberoptic bronchoscopy may avoid this complication.

Although majority of patients are ventilated mechanically during the intraoperative period, the system must have a high-pressure alarm device incorporated. In manually ventilated patients, change in bag pressure alarms the anesthetists to look for the cause of tight bag situation early and such complication is likely to be picked up with even slight change in pressure by an experienced anesthetist. In cases of rise in ventilating pressure, anesthesia circuit pressure, or bag pressure, anesthetist should be checked and ETT suction done and ETT changed if needed.

In the case reported, surgical manipulation led to dislodgement of thick mucous secretion which suddenly blocked the ETT. During this period, it is important to observe for change in anesthesia circuit pressure or bag pressure. A gradual increase or a sudden rise suggests the possibility of mobilization of mucous plug and impending disaster. Some surgeons prefer to operate in lateral position and if ETT block occurs, the ETT may need to be taken out and bag/mask ventilation instituted. It is important to evaluate bag-mask ventilation at the beginning. Reintubation may be attempted in usual manner in lateral position. However, if it is not possible, the patient may have to be turned supine and the trachea intubated.

The case reported had a clinically clear chest on examination and had no finding suggestive of a respiratory pathology.

References

1. Shlamovitz GZ, Halpern P. Delayed obstruction of endotracheal tube by aspirated foreign body: Report of two cases. *Ann Emerg Med* 2004;43:630-3.
2. Judson MA, Sahn SA. Airway obstruction arising from blood clot: Three reports and review of literature. *Chest* 1999;115:293-300.
3. Changjoo P, Hyunjeong K, Kwangwon Y. Acute obstruction of endotracheal tube: A case report. *Anesth Prog* 2004;5:62-4.
4. Parthasarathy M, Ravishankar M. Tight bag. *Indian J Anesth* 2010;54:193-8.
5. Davis D, Joseph M, Pop RB, Szumk P. Airway obstruction due to endotracheal tube's lumen collapse secondary to cuff pressure. *Anesth Analg* 2011;112:1511-2.
6. Mehdi NE, Weinberger MM, Abu-Hasan MN. Achalasia: Unusual cause of chronic cough. *Cough* 2008;4:6.
7. Kale A, Walker J, Natrajan A. Achalasia cardia masquerading as gastro esophageal reflux disease. *Welsh Paed J* 2010;34:15-7.
8. Xue FS, Luo M, Liao Xu, Liu Jh, Zhang YM. Delayed endobroncheal tube obstruction by mucus plug in a child. *Chin Med J* 2009;122:870-2.
9. Hoyt J. Analytical Reviews: Aspiration Pneumonitis: Patient risk factors, prevention and management. *J Intensive Care Med* 1990;5(Suppl):S2-9.

How to cite this article: Gupta A, K, Thakur VK, Kumar A. Sudden endotracheal tube block in a patient of Achalasia Cardia. *J Anaesthesiol Clin Pharmacol* 2012;28:381-3.

Source of Support: Nil, **Conflict of Interest:** None declared.