

# Parotid gland cholesteatoma in a 23-year-old male: Case report

SAGE Open Medical Case Reports  
Volume 5: 1–3  
© The Author(s) 2017  
Reprints and permissions:  
sagepub.co.uk/journalsPermissions.nav  
DOI: 10.1177/2050313X17749083  
journals.sagepub.com/home/sco



Krzysztof Piersiala , Hanna Klimza, Joanna Jackowska and Małgorzata Wierzbicka

## Abstract

Cholesteatoma is a pathological tissue that may extend into all parts of temporal bone and rarely, as this study highlights, beyond its structures. Nevertheless, the spread outside the mastoid tip into the soft tissues of the neck or parotid space is very rare. The case of 23-year-old male with right parotid mass is presented. The patient had history (2006, 2009, and 2012) of three tympanoplastics for recurrent right ear cholesteatoma. The parotid tumor was revealed incidentally in magnetic resonance imaging in January 2016, but the imaging was inconclusive. After 6 months, the patient developed right-sided facial nerve palsy. The second look of the right ear was performed with simultaneous parotid surgery. The ear was healed and free of cholesteatoma, but the parotid mass resembled the cholesteatoma confirmed later on by histological examination. The tumor extended from stylomastoid foramen. This case was unusual as the disease had extended beyond the ear with the bony parts of the mastoid being preserved. To our knowledge, this is the first case report to describe a parotid gland cholesteatoma not being an extension of a cholesteatoma present in the tympanic cavity and entering the parotid gland via stylomastoid foramen.

## Keywords

Otolaryngology, surgery, cholesteatoma, head tumor

Date received: 12 September 2017; accepted: 27 November 2017

## Introduction

Cholesteatomas are non-neoplastic, keratinizing lesions, characterized by the proliferation of epithelium into the middle ear or mastoid cavity. An acquired origin is bind with a previous history of a middle ear inflammatory process.<sup>1</sup> Without timely detection and intervention, cholesteatomas can result in numerous intracranial and extracranial complications.<sup>2</sup> Nevertheless, the spread outside the mastoid tip into the soft tissues of the neck or parotid space is very rare.

## Case report

We report an extremely rare case of parotid gland cholesteatoma in 23-year-old male patient. In 2006, the patient was diagnosed with chronic suppurative otitis media (OM) and right ear conductive hearing loss of 55 dB. Consequently, the middle ear cholesteatoma was diagnosed and operated. In 2009 and 2012, recurrent cholesteatomas were diagnosed and radically resected. In March 2016, a control magnetic resonance imaging (MRI; Figure 1) incidentally revealed a hyperintense tumor in the right parotid gland. It has become painful

in July 2016 and in September 2016; the patient presented with drooping of the mouth on the side of the tumor, which corresponded to grade 2 facial nerve status in House–Brackmann facial nerve grading system. In October 2016, pre-operative examination of the ear demonstrated typical postoperative changes and was negative for cholesteatoma. The cholesteatoma-like tumor expanding from the styloid-mastoid foramen was excised during surgery. Its diameter was 30 mm and it lay on the right facial nerve trunk in between superficial and deep lobes of parotid gland (Figure 2). Histological examination confirmed cholesteatoma. In tympanoscopy, the tympanic cavity was clear of cholesteatoma.

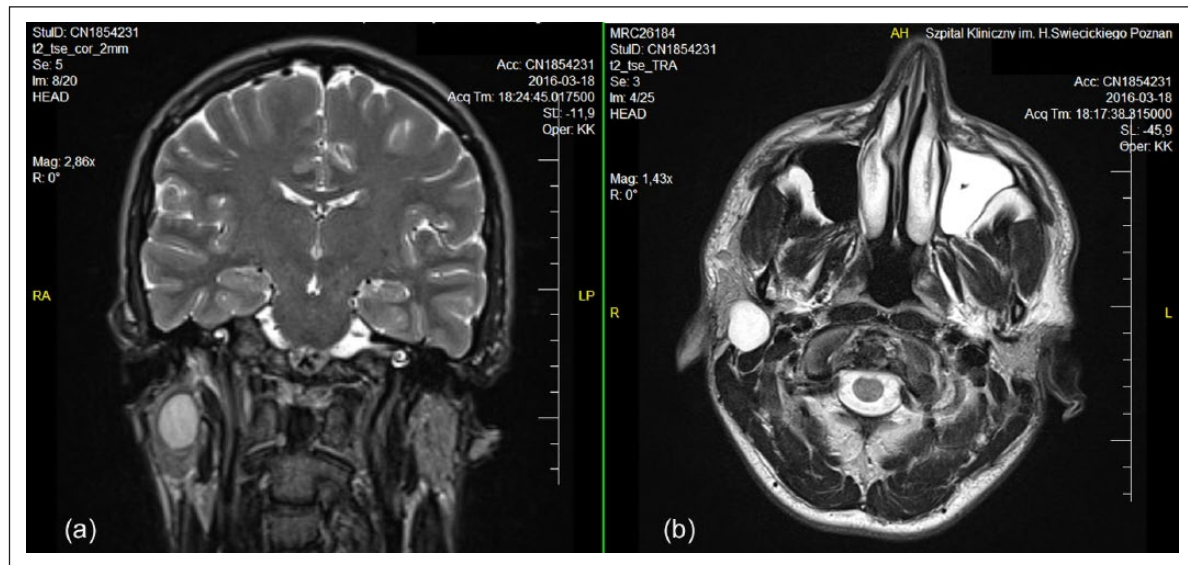
Department of Otolaryngology, Head and Neck Surgery, Poznań University of Medical Sciences, Poznań, Poland

### Corresponding Author:

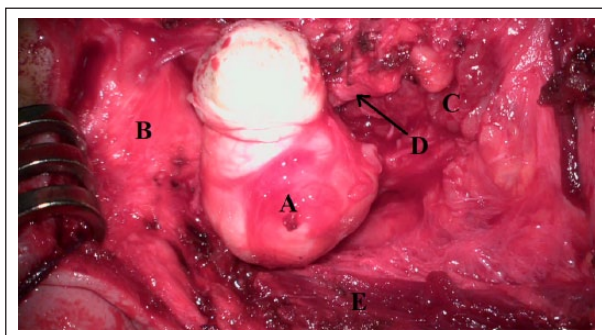
Krzysztof Piersiala, Department of Otolaryngology, Head and Neck Surgery, Poznań University of Medical Sciences, Przybyszewskiego 49, 60-355 Poznań, Poland.

Email: piersiala@hotmail.com





**Figure 1.** (a) Coronal and (b) axial magnetic resonance images show hyperintense and non-enhancing tumor by contrast mass in the right parotid gland.



**Figure 2.** Intraoperative picture of cholesteatoma in the right parotid gland extending from stylomastoid foramen. (A—cholesteatoma; B—wall of external meatus; C—parotid parenchyma; D—facial nerve trunk; E—sternocleidomastoid muscle.)

One day after surgery, the patient recovered well with no signs of facial nerve palsy or compromise.

## Discussion

The middle ear cholesteatoma is a troublesome and complex entity in otology. Even though it is a non-tumorous tissue, it may lead to fatal complications.<sup>3</sup> A review of literature on its epidemiology suggests an average annual incidence among adults of approximately 12 cases per 100,000 inhabitants.<sup>3–5</sup>

The pathogenesis still remains unclear and controversial. The well-established theories on cholesteatoma formation include metaplasia, hyperplasia, immigration, implantation, and invagination (retraction pocket) of epithelium.<sup>3,5</sup> Due to these destructive properties, cholesteatomas can invade into all parts of petrous bone including the mastoid process, sigmoid sinus, posterior and middle cranial fossa, internal auditory meatus

(IAM), cochlea, petrous apex, or into facial nerve canal. Complications of cholesteatoma extension are divided into extracranial (subperiosteal mastoid abscess, facial nerve palsy, and labyrinthine fistula) and intracranial (meningitis, brain abscess, lateral sinus thrombophlebitis, and perisinus abscess).<sup>6</sup>

Although complications of cholesteatoma extension within petrous bone occur infrequently, they are well known among otolaryngologists. However, only few physicians are aware of possible extension beyond temporal bone. A review of literature provides examples of cholesteatoma extension to maxillary and frontal sinuses<sup>7,8</sup> and into upper neck.<sup>9</sup>

To our knowledge, the disease history of our patient seems to be exceptional as at the time of incidental parotid mass diagnosis, there was no ear disease and the patient was asymptomatic. A formal ear examination also showed as expected small, well epithelized postoperative cavity. To characterize the mass in more detail preoperatively, an MRI with non-echo-polar diffusion-weighted images, postcontrast MRI sequences, and T1- and T2-weighted sequences was performed. It confirmed no recurrence of cholesteatoma in the right ear. The mass in right parotid showed low/intermediate signal in T1-weighted sequences and hyperintense signal in T2-weighted and diffusion-weighted imaging (DWI) sequences in keeping with radiological features of middle ear cholesteatoma or abscess according to Thiriati et al.<sup>10</sup> There was no apparent MRI intensity change in the facial nerve canal.

Eventually, all of the test results were indicating a benign lesion. However, the patient presented with the alarming new symptom of drooping of the mouth on the ipsilateral side of the tumor, which corresponded to grade 2 facial nerve status in House–Brackmann facial nerve grading system. Assuming the benign character of the lesion, the paralysis of the marginal mandibular branch of facial nerve was unexpected. Struggling with the preoperative diagnosis, surgeons

decided to proceed with primary surgery instead of an incisional biopsy of the lesion.

Surgery revealed a cholesteatoma-like lesion that was excised. It lay on the facial nerve trunk and extended from the stylomastoid foramen. The tumor was adjacent to the facial nerve, but still a blunt dissection within the perineurium was possible. It was removed with the capsule without microscopic features of the remnant. As the margin status was negative, there is a chance for no or delayed recurrence. Histological examination confirmed that the features of the lesion were consistent with cholesteatoma. A histopathological differential diagnosis included an iatrogenic epidermal inclusion cyst<sup>11</sup> which was eventually excluded.

As a parotid gland cholesteatoma is an extremely uncommon finding, we searched Medline/PubMed databases. Surprisingly, only one article describing cholesteatoma within the parotid gland was identified.<sup>12</sup> In that case, the parotid mass was observed in the 40-year-old female with the history of radical mastoidectomy. The tumor was located in the superficial lobe of parotid and extended from a 0.5 cm defect in the left mastoid tip. Impaired function of the facial nerve was observed as well. Authors suggested that the original mastoid work did not reach the tip or residual cholesteatoma was hidden behind Koerner's septum.

Thus, the case of our patient is the first ever presenting extension of cholesteatoma from temporal bone structures into parotid gland via stylomastoid foramen. Our hypothesis is that a portion of the cholesteatoma remained within the facial nerve canal after the last surgery. It extended along facial nerve, which was intact at that time. Eventually, it reached the stylomastoid foramen and entered parotid gland along the facial nerve.

The patient is on a frequent follow-up schedule in the outpatient setting. The plan is to perform regular formal ear examinations and radiological imaging of both ears and parotid glands. MRI serves as a gold standard to exclude the recurrence within parotid.

In conclusion, cholesteatoma is a pathological tissue that may extend into all parts of temporal bone and rarely, as this study highlights, beyond its structures. Although parotid gland cholesteatomas are rare, as clinicians we should keep them in mind in the presence of an undiagnosed parotid gland mass. The earlier cholesteatomas are discovered, the easier it is to perform surgical removal and there is a lower risk of facial nerve involvement. Also, searching for predictors of aggressiveness might help determine the proper timing of intervention, prevent recurrence, and reduce complications. We have described that the stylomastoid foramen can be a possible route for extension of cholesteatomas from middle ear structures into the parotid gland.

#### Declaration of conflicting interests

The authors declare that they have no conflicts of interest. This article does not contain any studies with animals performed by any authors.

#### Ethical approval

Our institution does not require ethical approval for reporting individual cases or case series. All procedures performed in studies involving human participants were in accordance with the ethical standards of the institutional and national research committee and with the 1964 Helsinki Declaration and its later amendments or comparable ethical standards.

#### Funding

The author(s) received no financial support for the research, authorship, and/or publication of this article.

#### ORCID iD

Krzysztof Piersiala  <http://orcid.org/0000-0003-3844-5999>.

#### Informed consent

Written informed consent was obtained from the patient(s) for their anonymized information to be published in this article.

#### References

1. Isaacson G. Diagnosis of pediatric cholesteatoma. *Pediatrics* 2007; 120: 603–608.
2. Kuo C-L, Shiao A-S, Yung M, et al. Updates and knowledge gaps in cholesteatoma research. *Biomed Res Int* 2015; 2015: 854024-1–854024-17.
3. Hamed MA, Nakata S, Sayed RH, et al. Pathogenesis and bone resorption in acquired cholesteatoma: current knowledge and future perspectives. *Clin Exp Otorhinolaryngol* 2016; 9: 298–308.
4. Aquino JE, Cruz Filho NA and de Aquino JN. Epidemiology of middle ear and mastoid cholesteatomas: study of 1146 cases. *Braz J Otorhinolaryngol* 2011; 77: 341–347.
5. Tos M. Incidence, etiology and pathogenesis of cholesteatoma in children. *Adv Otorhinolaryngol* 1988; 40: 110–117.
6. Sharma N, Jaiswal AA, Banerjee PK, et al. Complications of chronic suppurative otitis media and their management: a single institution 12 years experience. *Indian J Otolaryngol Head Neck Surg* 2015; 67: 353–360.
7. Sozansky J and Josephson JS. Cholesteatoma of the maxillary sinus: a case report and review of the literature. *Am J Otolaryngol* 2015; 36: 290–291.
8. Hammami B, Mnejja M, Chakroun A, et al. Cholesteatoma of the frontal sinus. *Eur Ann Otorhinolaryngol Head Neck Dis* 2010; 127: 213–216.
9. Li L and Ren J. Aural cholesteatoma with upper neck extension. *Auris Nasus Larynx* 2012; 39: 534–536.
10. Thiriat S, Riehm S, Kremer S, et al. Apparent diffusion coefficient values of middle ear cholesteatoma differ from abscess and cholesteatoma admixed infection. *Am J Neuroradiol* 2009; 30: 1123–1126.
11. Ulku CH, Uyar Y, Kocaogullar Y, et al. Iatrogenic epidermal inclusion cyst of the parapharyngeal space: unusual complication of ear surgery. *Skull Base* 2004; 14: 47–51.
12. Shaheen NA, Harboyan GT and Nassif RI. Cysts of the parotid gland. Review and report of two unusual cases. *J Laryngol Otol* 1975; 89: 435–444.