



Original Article

Reproducibility of a new classification of the anterior clinoid process of the sphenoid bone

Feres Chaddad-Neto¹, Marcos Devanir Silva da Costa¹, Bruno Santos¹, Ricardo Lourenco Caramanti², Bruno Lourenco Costa³, Hugo Leonardo Doria-Netto¹, Eberval Gadelha Figueiredo⁴

¹Department of Neurosurgery, Universidade Federal de São Paulo, ²Department of Neurosurgery, Faculdade de Medicina de São Jose do Rio Preto, Sao Jose do Rio Preto, ⁴Department of Neurosurgery, Universidade de São Paulo, São Paulo, Brazil, ³Department of Neurosurgery, Centro Hospitalar Tondela-Viseu, EPE, Viseu, Portugal.

E-mail: Feres Chaddad-Neto - fereschaddad@hotmail.com; *Marcos Devanir Silva da Costa - marcoscostaneuro@gmail.com; Bruno Santos - brunofernandes.se@gmail.com; Ricardo Lourenco Caramanti - rcaramanti@hotmail.com; Bruno Lourenco Costa - brunolourencocosta@gmail.com; Hugo Leonardo Doria-Netto - hldoria@hotmail.com; Eberval Gadelha Figueiredo - ebgadelha@yahoo.com



*Corresponding author:

Marcos Devanir Silva da Costa,
Department of Neurosurgery,
Universidade Federal de São
Paulo, São Paulo, Brazil.

marcoscostaneuro@gmail.com

Received : 29 March 2020

Accepted : 08 July 2020

Published : 12 September 2020

DOI:

10.25259/SNI_133_2020

Quick Response Code:



ABSTRACT

Background: Pneumatization of the anterior clinoid process (ACP) affects paraclinoid region surgery, this anatomical variation occurs in 6.6–27.7% of individuals, making its preoperative recognition essential given the need for correction based on the anatomy of the pneumatized process. This study was conducted to evaluate the reproducibility of an optic strut-based ACP pneumatization classification by presenting radiological examinations to a group of surgeons.

Methods: Thirty cranial computer tomography (CT) scans performed from 2013 to 2014 were selected for analysis by neurosurgery residents and neurosurgeons. The evaluators received Google Forms with questionnaires on each scan, DICOM files to be manipulated in the Horos software for multiplanar reconstruction, and a collection of slides demonstrating the steps for classifying each type of ACP pneumatization. Interobserver agreement was calculated by the Fleiss kappa test.

Results: Thirty CT scans were analyzed by 37 evaluators, of whom 20 were neurosurgery residents and 17 were neurosurgeons. The overall reproducibility of the ACP pneumatization classification showed a Fleiss kappa index of 0.49 (95% confidence interval: 0.49–0.50). The interobserver agreement indices for the residents and neurosurgeons were 0.52 (0.51–0.53) and 0.49 (0.48–0.50), respectively, and the difference was statistically significant ($P < 0.00001$).

Conclusion: The optic strut-based classification of ACP pneumatization showed acceptable concordance. Minor differences were observed in the agreement between the residents and neurosurgeons. These differences could be explained by the residents' presumably higher familiarity with multiplanar reconstruction software.

Keywords: Anterior clinoid process, Sphenoid bone, Cavernous sinus, Skull base, Optic strut

INTRODUCTION

The anterior clinoid process (ACP) protrudes posteriorly from the lesser sphenoid wing of the sphenoid bone, composing the anterior portion of the cavernous sinus' roof. The base of the ACP has three attachment points with the adjacent sphenoid bone: The lateral attachment is the medial border of the lesser sphenoid wing and, laterally, the anterior root of the lesser sphenoid wing extends from the base of the ACP to the sphenoid body, forming the roof of the optic canal, also called the planum

This is an open-access article distributed under the terms of the Creative Commons Attribution-Non Commercial-Share Alike 4.0 License, which allows others to remix, tweak, and build upon the work non-commercially, as long as the author is credited and the new creations are licensed under the identical terms.

©2020 Published by Scientific Scholar on behalf of Surgical Neurology International

sphenoidale. The third point is a minor sphenoid bone, called the optic strut, that extends below the optic nerve, reaching the body of the sphenoid and forming the floor of the optic canal and roof of the superior orbital fissure.^[20,21]

The optic pillar is a small bony bridge that extends from the inferomedial surface of the ACP base to the sphenoid body, immediately ahead of the carotid sulcus. From its junction with the ACP, the optic strut slopes gently downward as it approaches the body of the sphenoid.

Within the context of the anatomy of the sphenoid bone, the ACP has strategic importance for the surgical approach since its removal is a critical step in the treatment of paraclinoid lesions, which are closely related to the ACP, required to gain a partial medial view of the minor wing of the sphenoid bone and the cavernous sinus roof. Examples of conditions requiring ACP removal include aneurysms of the ophthalmic segment of the internal carotid artery, meningiomas of the cavernous sinus, and the medial third of the lesser sphenoid wing and also giant pituitary adenomas.^[10-12,15]

The microsurgical procedure of anterior clinoidectomy is a key to the treatment of pathologies that arise from the paraclinoid region. However, this procedure involves the risks of visual disturbances, oculomotor nerve palsy/paralysis, bleeding from the opening of the cavernous sinus, lesion of the internal carotid artery as well as of the ophthalmic artery, opening of the paranasal sinuses, and cerebrospinal fluid fistula potentially leading to meningitis and death. For paraclinoid aneurysm surgery, the reported rates of morbidity, mortality, and cerebrospinal fluid fistula with or without meningitis are 5.8–18%, 0.6–45.4%, and 2.2–14%, respectively. Because anterior clinoidectomy is imperative for paraclinoid aneurysms, these rates are likely to be similar to those in patients with paraclinoid diseases undergoing surgery.^[3,5-8,13,17,19,22-24]

Pneumatization of the ACP is an anatomical variation that occurs in 6.6–27.7% of individuals, making its preoperative recognition essential given the need for correction based on the anatomy of the pneumatized process.^[1,2,16,18] In 2016, da Costa *et al.* published a simplified classification of ACP pneumatization unifying multiple existing systems.^[4] The classification includes pneumatization of the optic pillar as part of the ACP pneumatization complex, resulting in four types, with a total of five subtypes, of pneumatization: Type 0 – absence of pneumatization; Type 1 – pneumatization in the optic strut without pneumatization in the ACP body; Type 2 A – pneumatization through the optic strut of $\leq 50\%$ of the ACP body; Type 2 B – pneumatization through the optic strut of $>50\%$ of the ACP body; and Type 3 – ACP pneumatization through the sphenoidal plane (with or without a pneumatized optic strut). Although promising, this classification requires validation. In the present study, we studied the a priori reproducibility of the optic strut-based classification system among different raters.^[4]

MATERIALS AND METHODS

Patients were selected from project (morphometric analysis of the ACP of the sphenoid bone), approved by the Institutional Research Ethics Committee. These patients received skull base computed tomography (CT) scans (internal and mastoid ears), because of suspected internal/mastoid ear disease, at the Department of Radiology and Diagnostic Imaging from January 1, 2013, to September 6, 2014. Patients with a history of paranasal sinus disease who had undergone transsphenoidal surgery, as well as neurosurgical procedures involving the skull base, were excluded from the study.

Images of skull base tomography (internal and mastoid) were obtained at the Department of Radiology and Diagnostic Imaging, using the Brilliance computed tomography (CT) 64 system (Philips) with the following technical specifications: collimation 20×0.625 , pitch 0.348, matrix 512, field of view 200 mm, 140 kpv, 278–600 mA, and cut thickness 0.67 mm. Pneumatization was characterized by the presence of structures with the same air density.

Each evaluator received a Google Forms email link (www.google.com) with a total of 30 examinations to evaluate the different subtypes of ACP pneumatization. None of the participants had access to the forms of other participants. Only fully completed surveys were accepted. The DICOM files were anonymized and provided on a separate email link, along with a Microsoft® Office PowerPoint presentation with JPEG images of the 2016 da Costa *et al.* article and ACP pneumatization classification instructions.^[4] Observer consensus was calculated using the Fleiss kappa value in Microsoft® Office Excel 2016.^[9] The 95% confidence interval (CI) was also calculated. Kappa values <0.40 , 0.41–0.60, 0.61–0.80, and >0.80 were considered as fair, moderate, substantial, and near-perfect agreement, respectively.^[14]

Three senior neurosurgeons, authors of the original ACP pneumatic classification paper,^[4] classified all ACPs by consensus and did not participate as observers in the analysis. The consensus classification was considered the reference response [Figure 1]. Two-tailed Fisher's exact test was used to assess the statistical significance of the difference in agreement between the resident and neurosurgeon groups for each assessed subtype.

Descriptive statistics are presented as numbers or frequencies as appropriate.

RESULTS

The 30 skull-based CT scans were analyzed by a total of 37 evaluators, of which 20 (54%) were neurosurgery residents and 17 (46%) were neurosurgeons. In the overall analysis of the classification, the Fleiss kappa index of interobserver agreement was 0.49 (95% CI: 0.49–0.50). However, when the neurosurgeons and residents were analyzed separately, the

respective Fleiss kappa indices of interobserver agreement were 0.49 (95% CI: 0.48–0.50) and 0.52 (95% CI: 0.51–0.53), and the differences between the general interobserver agreement index and those among the neurosurgery residents and neurosurgeons were statistically significant with $P < 0.00001$ [Table 1].

The overall analysis of all 37 assessors in relation to each subtype of ACP pneumatization classification revealed that Type 0 (complete lack of pneumatization) showed the substantial agreement of 0.66 (95% CI: 0.64–0.68) and Type 2A demonstrated the fair agreement of 0.35 (95% CI:

0.33–0.36). The other subtypes showed fair to moderate concordance, summarized in [Table 2].

The same trends were found when analyzing the subtypes by evaluator group. Among the neurosurgeons [Table 3], Type 0 also showed the best interobserver agreement with a Fleiss kappa value of 0.65 (95%: 0.63–0.67), while Type 2 A showed a kappa value of 0.34 (95% CI: 0.32–0.36). The resident group [Table 4] had an interobserver agreement index of 0.66 (95% CI: 0.64–0.68) for type 0 and 0.35 (95% CI: 0.33–0.36) for Type 2A.

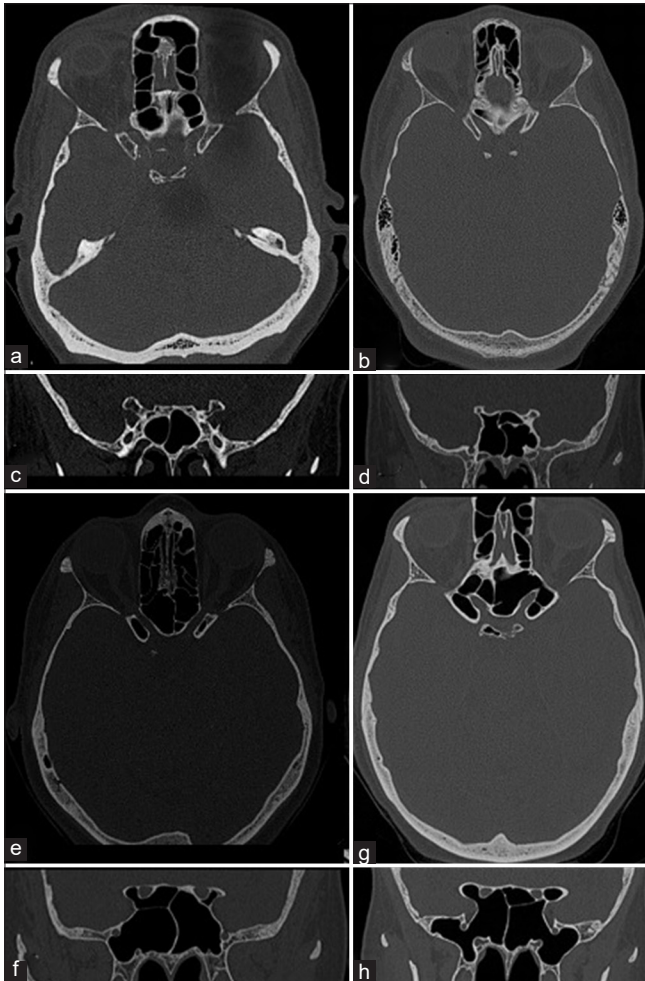


Figure 1: This is a panel of skull-based computed tomography containing all the examples of each type of anterior clinoid. (a and b) The axial and coronal views of a Type 0, absence of pneumatization. (c and d) The axial and coronal views of a Type 1, pneumatization of the optic strut without anterior clinoid pneumatization. (e and f) The axial and coronal views of Type 2A (left side) and 2B (right side), this subtype presents a pneumatized anterior clinoid and optic strut, the difference is the volume of pneumatization in the anterior clinoid, the Type 2A has less than 50% and the Type 2b has more than 50% of aeration. (g and h) The axial and coronal views of Type 3, pneumatization of the anterior clinoid, optic strut, and planum sphenoidale.

Table 1: Evaluation of the interobserver agreement between all the evaluators according to the subtype of classification of the pneumatization of the previous clinoid process.

Type	Fleiss kappa	Lower	Upper	P-value
Type 0	0.667444891	0.649088146	0.685801636	<0.00001
Type 1	0.41640958	0.398052835	0.434766325	<0.00001
Type 2A	0.350713232	0.332356487	0.369069976	<0.00001
Type 2B	0.557913147	0.539556402	0.576269891	<0.00001
Type 3	0.386333481	0.367976736	0.404690225	<0.00001

Table 2: Evaluation of the interobserver agreement between all the evaluators according to the subtype of classification of the pneumatization of the previous clinoid process.

Type	Fleiss kappa	Lower	Upper	P-value
Type 0	0.667444891	0.649088146	0.685801636	<0.00001
Type 1	0.41640958	0.398052835	0.434766325	<0.00001
Type 2A	0.350713232	0.332356487	0.369069976	<0.00001
Type 2B	0.557913147	0.539556402	0.576269891	<0.00001
Type 3	0.386333481	0.367976736	0.404690225	<0.00001

Table 3: Interobserver agreement among neurosurgeons according to the classification of the pneumatization of the anterior clinoid process.

Type	Fleiss kappa	Lower	Upper	P-value
Type 0	0.655969482	0.634272316	0.677666648	<0.00001
Type 1	0.413152776	0.39145561	0.434849942	<0.00001
Type 2A	0.344574159	0.322876993	0.366271325	<0.00001
Type 2B	0.480768869	0.459071703	0.502466035	<0.00001
Type 3	0.440465347	0.418768181	0.462162513	<0.00001

Table 4: Interobserver agreement among neurosurgeons according to the classification of the pneumatization of the anterior clinoid process.

Fleiss kappa	Lower	Upper	P-value
0.640940185	0.631135462	0.650744909	<0.00001
0.406613598	0.396808874	0.416418321	<0.00001
0.336261697	0.326456974	0.346066421	<0.00001
0.518782002	0.508977278	0.528586725	<0.00001
0.392145417	0.382340694	0.401950141	<0.00001

DISCUSSION

In an interobserver analysis considering all evaluators, the reproducibility of the optic strut-based ACP pneumatization classification was moderate, with a Fleiss kappa value of 0.49 (95% CI: 0.49–0.50), which represents acceptable interobserver reproducibility. As stated in the original report of this classification, it is intended as a preoperative guideline for surgery involving pathologies of the paracaloid region, which entails opening the anterior portion of the cavernous sinus roof and anterior clinoidectomy.^[20] Thus, preoperative ACP type recognition may guide intraoperative reconstruction. For example, in cases of anterior clinoidectomy of subtypes 1, 2A, and 2B, the neurosurgeon may follow the “yo-yo” correction procedure proposed by Chi *et al.* (2006).^[2] In Type 3 cases, a different form of the yo-yo correction would be necessary given the pneumatization involving two distinct pathways and thus requiring larger grafts, as suggested previously.^[20]

At least three other clinoid pneumatization classifications have been proposed;^[10–12] however, none of them have been tested for reproducibility. The optic strut-based classification is, therefore, the first to have been submitted to evaluation by different observers. Two types of evaluators were selected, neurosurgeons (46% [17/37] of the sample) and neurosurgery residents in different training years (54% [20/37]). We used a statistical calculation capable of decoding the interobserver agreement of multiple evaluators, the Fleiss kappa, and found statistically significant differences among the different groups. There was a difference between the evaluations of all pneumatization subtypes taken together by the neurosurgeons or neurosurgery residents. This difference may be explained in part by the need to use multiplanar reconstruction tools in DICOM visualization programs,

the residents being more likely to be familiar with such tools. However, although statistically significant differences were demonstrated for multiple subtypes, none of them changed interobserver agreement category according to the division established by Landis and Koch.^[14] For example, despite the Fleiss kappa values for the residents (0.66) and neurosurgeons (0.65) in type 0 assessment being statistically significant, both were substantial agreement.

Among the different subtypes of the classification, 2A showed the worst interobserver agreement indices, followed by 3, 1, 2B, and 0. Type 0 predictably had the best reproducibility since it represents the absence of changes or pneumatization. In contrast to 2B, subtype 2A showed only fair reproducibility. Type 3 was not highly prevalent in the sample and requires better knowledge of the DICOM viewer program; it was moderately difficult to classify.

The practical aspect of this anterior clinoid classification is the possibility of preoperative planning for the correction of possible openings or communication of the sphenoid and ethmoid sinuses in surgeries of pathologies involving the paracaloid region, which requires an anterior clinoidectomy. In this sense, type 0 indicates that there will be no need for any intraoperative repair, unless the neurosurgeon intentionally wishes to open one of these paranasal sinuses. In Types 1, 2 A, and 2 B, despite the difference in the degree of pneumatization, the pneumatization route is the same, the optic strut, and therefore, the repair technique must be focused on closing the optic strut. In type 3, the correction should require a technique that includes closing the opening of the planum sphenoidale with communication to the ethmoid sinus, and the optic strut with communication to the sphenoid sinus, [Figure 2] illustrates a clinical case with

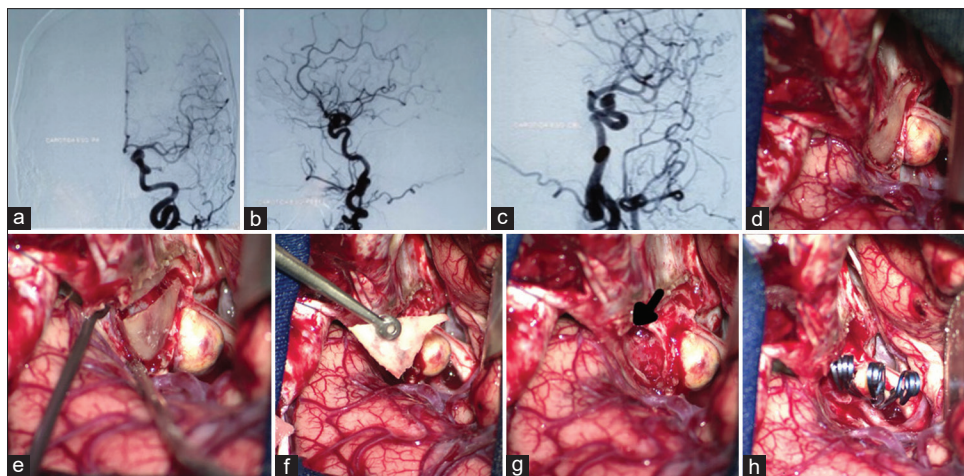


Figure 2: This panel of images illustrates a clinical case of a 56-year-old female that presented with visual loss of the left eye, the angiogram (a-c) showed a paraclinoid aneurysm. The image (d) shows the intraoperative exposure of the anterior clinoid process. The image (e) reveals the disconnection of the anterior clinoid process from its bone attachments. The image (f) shows the “*en bloc*” removal of the anterior clinoid process. The image (g) reveals the communication of the sphenoid sinus through the optic strut promoted by the anterior clinoid removal. Figure (h) shows the final aspect of the aneurysm clipping.

Type 2B where it is possible to observe the communication of the pneumatized optic strut with sphenoid sinus.

Further study is needed to analyze the effect of combining subtypes 2A and 2B into a single category on the reproducibility of the optic pillar-based pneumatic ACP classification. Because classification was based on a single contact with the CT images in the present study, future research should also address the possibility of improving reproducibility through multiple rounds of image evaluation by the same observer.

CONCLUSION

We found moderate reproducibility of the optic strut-based classification of ACP pneumatization. This classification represents a simple and sufficiently reproducible method of preoperative analysis of patient imaging data to be applied in clinical practice for planning surgery in the paraclinoid region.

Declaration of patient consent

Institutional Review Board permission obtained for the study.

Financial support and sponsorship

Nil.

Conflicts of interest

There are no conflicts of interest.

REFERENCES

- Abuzayed B, Tanriover N, Biceroglu H, Yuksel O, Tanriover O, Albayram S, *et al.* Pneumatization degree of the anterior clinoid process: A new classification. *Neurosurg Rev* 2010;33:367-73.
- Chi JH, Sughrue M, Kunwar S, Lawton MT. The yo-yo technique to prevent cerebrospinal fluid rhinorrhea after anterior clinoidectomy for proximal internal carotid artery aneurysms. *Neurosurgery* 2006;59 Suppl 1:ONS101-7.
- Colli BO, Carlotti CG Jr., Assirati JA Jr., Abud DG, Amato MC, Dezena RA. Results of microsurgical treatment of paraclinoid carotid aneurysms. *Neurosurg Rev* 2013;36:99-114.
- da Costa MD, Santos BF, Paz DA, Rodrigues TP, Abdala N, Centeno R, *et al.* Anatomical variations of the anterior clinoid process: A study of 597 skull base computerized tomography scans. *Oper Neurosurg (Hagerstown)* 2016;12:289-97.
- Day AL. Aneurysms of the ophthalmic segment. A clinical and anatomical analysis. *J Neurosurg* 1990;72:677-91.
- De Jesus O, Sekhar LN, Riedel CJ. Clinoid and paraclinoid aneurysms: Surgical anatomy, operative techniques, and outcome. *Surg Neurol* 1999;51:477-87.
- Dolenc VV. A combined epi- and subdural direct approach to carotid-ophthalmic artery aneurysms. *J Neurosurg* 1985;62:667-72.
- Drake CG, Vanderlinden RG, Amacher AL. Carotid-ophthalmic aneurysms. *J Neurosurg* 1968;29:24-31.
- Fleiss JL. *Statistical Methods for Rates and Proportions*. New York: John Wiley & Sons; 1981.
- Giannotta SL. Ophthalmic segment aneurysm surgery. *Neurosurgery* 2002;50:558-62.
- Javalkar V, Banerjee AD, Nanda A. Paraclinoid carotid aneurysms. *J Clin Neurosci* 2011;18:13-22.
- Kulwin C, Tubbs RS, Cohen-Gadol AA. Anterior clinoidectomy: Description of an alternative hybrid method and a review of the current techniques with an emphasis on complication avoidance. *Surg Neurol Int* 2011;2:140.
- Lai LT, Morgan MK. Outcomes for unruptured ophthalmic segment aneurysm surgery. *J Clin Neurosci* 2013;20:1127-33.
- Landis JR, Koch GG. The measurement of observer agreement for categorical data. *Biometrics* 1977;33:159-74.
- Lehmberg J, Krieg SM, Meyer B. Anterior clinoidectomy. *Acta Neurochir (Wien)* 2014;156:415-9.
- Mikami T, Minamida Y, Koyanagi I, Baba T, Houkin K. Anatomical variations in pneumatization of the anterior clinoid process. *J Neurosurg* 2007;106:170-4.
- Nanda A, Javalkar V. Microneurosurgical management of ophthalmic segment of the internal carotid artery aneurysms: Single-surgeon operative experience from Louisiana State University, Shreveport. *Neurosurgery* 2011;68:355-70.
- Ota N, Tanikawa R, Miyazaki T, Miyata S, Oda J, Noda K, *et al.* Surgical microanatomy of the anterior clinoid process for paraclinoid aneurysm surgery and efficient modification of extradural anterior clinoidectomy. *World Neurosurg* 2015;83:635-43.
- Raco A, Frati A, Santoro A, Vangelista T, Salvati M, Delfini R, *et al.* Long-term surgical results with aneurysms involving the ophthalmic segment of the carotid artery. *J Neurosurg* 2008;108:1200-10.
- Rhoton AL Jr. The cavernous sinus, the cavernous venous plexus, and the carotid collar. *Neurosurgery* 2002;51 Suppl 4:S375-410.
- Rhoton AL Jr. The sellar region. *Neurosurgery* 2002;51 Suppl 4:S335-74.
- Sharma BS, Kasliwal MK, Suri A, Chandra PS, Gupta A, Mehta VS. Outcome following surgery for ophthalmic segment aneurysms. *J Clin Neurosci* 2010;17:38-42.
- Silveira RL, Gusmao S, Pinheiro N, Andrade GC. Paraclinoid aneurysms: Surgical technique and results in 51 patients. *Arq Neuropsiquiatr* 2004;62:322-9.
- Xu BN, Sun ZH, Romani R, Jiang JL, Wu C, Zhou DB, *et al.* Microsurgical management of large and giant paraclinoid aneurysms. *World Neurosurg* 2010;73:137-46.

How to cite this article: Chaddad-Neto F, da Costa MD, Santos B, Caramanti RL, Costa BL, Doria-Netto HL, *et al.* Reproducibility of a new classification of the anterior clinoid process of the sphenoid bone. *Surg Neurol Int* 2020;11:281.