

## ORIGINAL ARTICLE

# Fibrous architecture of cementodentinal junction in disease: A scanning electron microscopic study

R Sudhakar, B Pratebha<sup>1</sup>

Department of Oral Pathology, Sri Venkateshwaraa Dental College, Ariyur, <sup>1</sup>Department of Periodontics, Indira Gandhi Institute of Dental Sciences, SBVU, Puducherry, India

**Address for correspondence:**

Dr. Pratebha B,

No. 9, 2<sup>nd</sup> Cross, Kailash Nagar, Airport

Road, Lawspet, Puducherry - 605 008, India.

E-mail: pratebhabalu@igids.ac.in

Received: 28-08-2014

Accepted: 21-12-2015

**ABSTRACT**

**Background:** The cementodentinal junction (CDJ) forms a biological and structural link between cementum and dentin. This biological link is regarded as a distinct tissue in its own right. Certain important proteins responsible for periodontal regeneration are said to be present in this tissue. Few studies have described the structure and composition of this layer by light and electron microscopy. Scanning electron microscopic studies pertaining to CDJ in health and disease are few and documentation of periodontal pathological changes of CDJ is unclear. In the first phase of our study, the collagenous architecture of CDJ of healthy teeth has been reported. **Aim:** The objective of this study is to observe and report periodontal pathological changes in the fibrous or collagenous architecture of CDJ of periodontitis-affected teeth and discuss the probable clinical implications of CDJ in disease. **Materials and Methods:** Twenty periodontitis-affected teeth were collected and processed for observing under a scanning electron microscope. **Results:** The results are as follows: Increased width of interface at CDJ in periodontitis samples (7.1  $\mu$ ) compared to that of healthy samples; fewer areas of fiber intermingling at CDJ in periodontitis samples as compared to healthy samples; frequent detachment of cementum from dentin during sodium hydroxide maceration of samples. **Conclusion:** It may be inferred from results that there is a possibility of a definite weakening of CDJ in periodontally affected root surfaces and we believe that clinical procedures such as scaling and root planning may have a detrimental effect on the cementodentinal attachment of periodontally involved root surfaces.

**Key words:** Cementodentinal junction, cementodentinal junction width, sodium hydroxide maceration

## INTRODUCTION

Cementodentinal junction (CDJ) is the area at the interface between cementum and dentin.<sup>[1,2]</sup> The attachment of cementum to dentin is said to be due to the presence of adhesive proteoglycans primarily and secondarily due to fiber intermingling fortified by mineralization.<sup>[3]</sup>

Studies on CDJ have proved that this junctional tissue is a distinct tissue in its own right.<sup>[4,5]</sup> The tissue is atubular, has a unique organic matrix and is more mineralized than

either cementum or dentin.<sup>[6,7]</sup> This junctional tissue plays an important role in periodontal regeneration and it is therefore imperative to develop a detailed understanding of its architecture.

Pathological changes during periodontitis affect this junctional tissue. Pathologic granules have been reported at or near the CDJ in periodontally exposed root surfaces.<sup>[8]</sup> These granules are also reported to be absent in health. Sites at or near the CDJ

This is an open access article distributed under the terms of the Creative Commons Attribution-NonCommercial-ShareAlike 3.0 License, which allows others to remix, tweak, and build upon the work non-commercially, as long as the author is credited and the new creations are licensed under the identical terms.

**For reprints contact:** reprints@medknow.com

**How to cite this article:** Sudhakar R, Pratebha B. Fibrous architecture of cementodentinal junction in disease: A scanning electron microscopic study. J Oral Maxillofac Pathol 2015;19:325-9.

Access this article online	
<b>Quick Response Code:</b> 	<b>Website:</b> <a href="http://www.jomfp.in">www.jomfp.in</a>
	<b>DOI:</b> 10.4103/0973-029X.174623

are said to be rich in unmineralized collagen and degradation of this collagen by bacterial toxins penetrating the surface of roots is said to be the etiology of the observed pathologic granules.<sup>[9,5,4]</sup>

Pathological granules, which are vacuoles due to collagen degradation, are purely light and electron microscopic observations of undemineralized teeth. Studying the collagenous architecture of demineralized teeth is likely to throw more light on the pathological alterations of exposed root surfaces at CDJ. Scanning electron microscopy (SEM) is superior to transmission electron microscope (TEM) when extended sections of root are to be examined because, with TEM, a sample can be viewed not as whole but at one point only, and therefore, we chose SEM over TEM in our study.

The collagenous architecture of CDJ of healthy teeth under a SEM has been described in a few studies and in the first phase of our study. CDJ appears as a fibril poor groove under SEM and the width of a healthy CDJ is 2–4  $\mu\text{m}$ .<sup>[7,10]</sup> A PubMed search revealed no studies pertaining to pathological alterations of fibrous architecture of CDJ as observed under SEM.

The aim and objective of this study was to observe and report the pathological alterations of the fibrous architecture at the CDJ in periodontitis-affected teeth under SEM. Only the collagenous architecture of the CDJ was studied under a scanning electron microscope. The compositional differences of this tissue in disease are beyond the scope of this study.

## MATERIALS AND METHODS

Twenty healthy and periodontitis-affected noncarious teeth were collected and processed. The periodontitis samples comprised teeth with a hopeless prognosis from patients with either chronic or aggressive periodontitis with no prior history of treatment for periodontitis. Healthy teeth samples comprised teeth extracted for orthodontic reasons. All extractions were done in Department of Periodontics. Written consent was obtained from all patients before extractions.

The collected samples were preserved in 10% formalin and sectioned into two halves. One-half of sample was processed for light microscopy and the other half for SEM. The samples for SEM were demineralized in 5% ethylenediaminetetraacetic acid for 2–3 months. Extent of demineralization was checked periodically by taking radiographs. When adequate demineralization was confirmed by radiography, the samples were immersed in 2.5% glutaraldehyde in 0.06M cacodylate buffer (pH 7.4) for a week. The samples were then taken up for sodium hydroxide (NaOH) maceration using 10% NaOH for 2–3 days. We followed the methodology that was suggested by Yamamoto *et al.*<sup>[7,10]</sup> in their studies.

The macerated specimens were treated with 2% tannic acid (to enhance electron density of elastin and collagen apart from being a fixative and mordant),<sup>[11]</sup> postfixed in 1% osmium tetroxide (to stabilize proteins during alcohol dehydration).<sup>[12]</sup> Then, they were dehydrated in graded series of alcohol, critical point dried, coated with palladium and examined under a scanning electron microscope.

SEM was chosen over TEM as samples cannot be viewed as a whole but are viewed at one particular point only and findings in one point cannot be generalized to the whole length of the root.

## RESULTS

In the first phase of the study, the observations of healthy CDJ were reported. This study reports only the collagenous architectural observations of periodontitis-affected teeth CDJ.

### Dentin

The identification of dentinal tissue was possible due to the presence of numerous dentinal tubule openings that were circular in shape [Figure 1a]. The collagen fibers appeared to be inadequately demineralized and ran parallel to dentin surface (in all periodontitis samples). Few fibers crossed the CDJ and traversed toward cementum [Figure 1b]. The contact of fibers from dentin and cementum at CDJ was mostly point-like in nature.

### Fiber intermingling

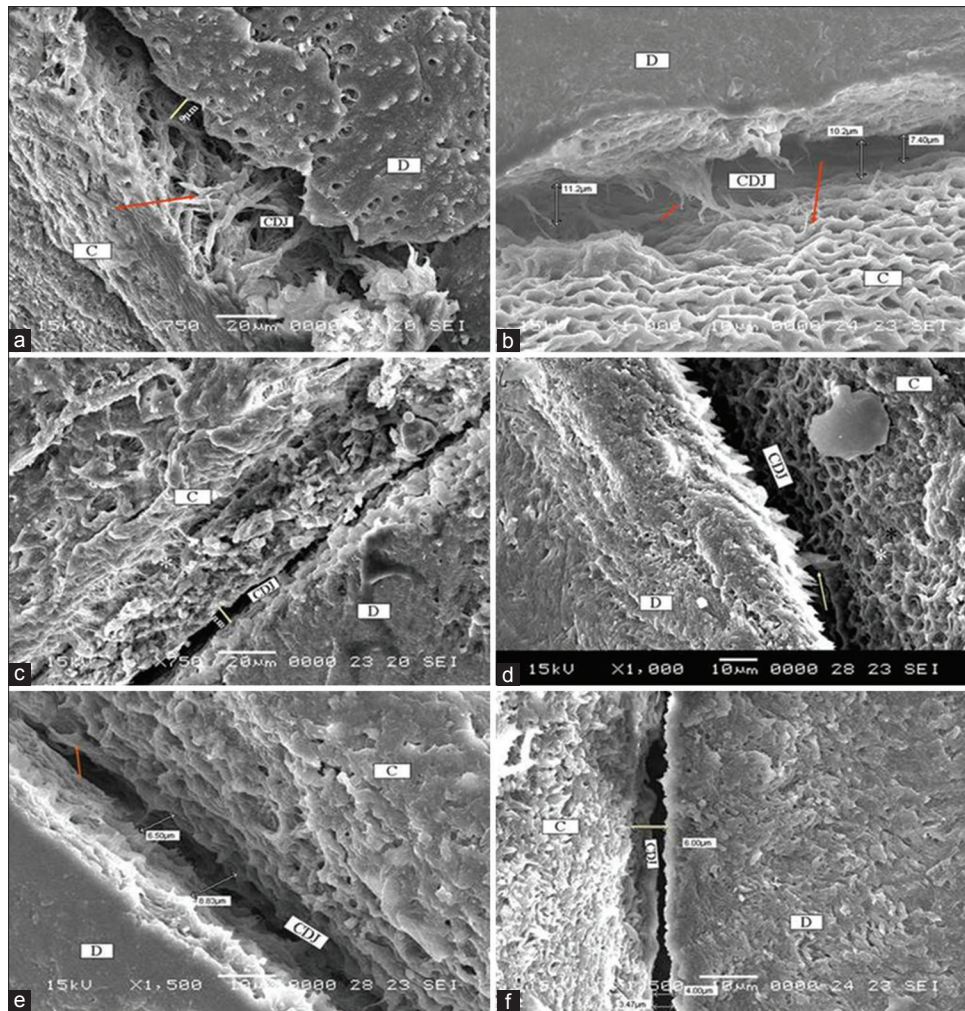
Fiber intermingling between dentin and cementum is point-like. Extensive criss-cross intermingling of fibers were not observed in both periodontitis samples [Figure 1a-f] healthy samples [Figure 2a and b] and. It was observed that the point-like contact was more frequently observed in healthy samples as compared to periodontitis samples.

### Cementum

In all images, collagen fiber architecture was better appreciated in cementum compared to dentin probably because demineralization was uniform and complete in cementum compared to dentin. Both the extrinsic and intrinsic fibers and the surface of cementum appear coarser than that in dentin. More fibers from cementum crossed over to dentin [Figure 1a-e].

In one sample, we observed an unusual honeycomb-like pattern of collagen architecture [Figure 1b]. We are unable to attribute any reason to this unusual appearance.

Detachment of cementum and dentin was observed in 7 out of 20 periodontitis samples. The detachment along the entire surface of the root can be appreciated in lower magnifications [Figure 3a-d].



**Figure 1:** (a) Dentin shows numerous tubule openings. Cementum shows coarse and thicker collagen fibers. Arrow indicates areas of fiber intermingling. The width at the CDJ is 9  $\mu$ m. (periodontitis sample) D: Dentin, C: Cementum, CDJ: Cementodentinal junction (SEM,  $\times 750$ ) (b) Cementum showing unusual honeycomb appearance (periodontitis sample) (SEM,  $\times 1000$ ). (c) Width at CDJ - 8  $\mu$ m (SEM,  $\times 750$ ). \*Incremental layers of cementum. (d) Arrow denotes fiber intermingling (SEM,  $\times 1000$ ). \*Inner surface of cementum (e) fiber intermingling (SEM,  $\times 1500$ ). (f) Mean width measured (SEM,  $\times 1500$ )

### Cementodentinal junction width

The CDJ appeared to be a fibril poor groove due to demineralization of the interfacial proteolytic substance. Width measurements were possible only in samples where detachment was absent and was measured along two to three sites along the length of the root [Figure 1b and e]. The mean width of the CDJ in periodontitis samples was 7.1  $\mu$  as compared to 3.4  $\mu$  in health. The inner surface of cementum could be observed in some samples [Figure 1e].

### DISCUSSION


Periodontally affected teeth undergo significant changes on the root surface as well as at CDJ.<sup>[13,14]</sup> Penetration of bacteria and its products into cementum causes alterations in organic and inorganic contents both on cemental surface and at CDJ.<sup>[15,16]</sup> On the external root surface of periodontally exposed root surfaces areas of remineralization and necrotic bays are observed.<sup>[17]</sup>

At CDJ due to seepage of bacterial products (endotoxins), denaturation of collagen at the CDJ is said to occur.<sup>[17]</sup> The interface at CDJ is rich in unmineralized collagen which gets easily denatured and degraded.<sup>[4,5]</sup> When collagen and other proteins are lost at the interface, there is a possibility of increase in the width of CDJ and subsequent weakening of the junction. It is therefore necessary to understand the pathologic changes at the junction and the probable clinical implications of a weak junctional tissue.


The objective of this study was to observe and report the pathological alterations of the collagenous architecture that occurred at CDJ in disease.

The fibrous architecture of CDJ of healthy teeth as observed under scanning electron microscope was described by Yamamoto *et al.*<sup>[3,7]</sup> and they reported the width of healthy CDJ as ranging between 2  $\mu$  and 4  $\mu$  which was in accordance with the first phase of our study comprising of healthy samples





**Figure 2:** Healthy sample: Arrow denotes fiber intermingling. Numerous dentinal tubule openings seen, Dentin (D) and Cementum (C) in close approximation with fiber intermingling. Areas of fiber intermingling clearly seen. Width measured is 4.5  $\mu\text{m}$  at cementodentinal junction (CDJ): (a) SEM,  $\times 1000$ , (b) SEM,  $\times 2000$



**Figure 3:** (a) Arrow shows areas of cementum detachment. Width measurement not possible (SEM,  $\times 120$ ) (b) Detachment of cementum present. Area of fiber intermingling also present (SEM,  $\times 1000$ ). (c) Arrow shows areas of cementum detachment. Width measurement not possible (SEM,  $\times 170$ ). (d) Cementum detachment (SEM,  $\times 190$ )

where the mean width of the samples was 3.9  $\mu\text{m}$ . In this study, we observed an increase in width at CDJ throughout the root surface of exposed portions. The mean width of periodontitis samples in our study was 7.1  $\mu\text{m}$  as compared to 3.9  $\mu\text{m}$  in healthy samples.

Frequent detachment of cementum from dentin was another significant observation in our study as compared to healthy samples. Of 20 samples, 7 had detached cementum and dentin

whereas no detachment was observed in healthy samples for the same period of NaOH maceration.

The reasons we propose for the detachment observed are:

- Increased denaturation and destruction of unmineralized collagen fibers at interface manifesting as increased width at interface
- Though detachment of cementum from dentin is expected to occur in prolonged NaOH maceration (r), in our study,



detachment was present only in periodontitis samples for the same period of NaOH maceration in both healthy and periodontitis samples. The only reason could be the pathologic alterations at CDJ in periodontitis samples causing detachment

- Cementum resorption could have caused thinning of cementum which could have contributed to frequent detachment in periodontitis samples.

A PubMed search revealed no studies describing the pathological alterations of fibrous architecture of CDJ using a scanning electron microscope and it was not possible to compare our results with similar studies. Based on the observations of our study, the possible clinical implications of a weakened CDJ could be as follows.

Root planing on periodontally affected root surfaces, which attempts to remove diseased and necrotic cementum,<sup>[18-22]</sup> could result in complete removal of cementum from root surfaces. With the removal of cementum, are lost cementum attachment proteins that are being increasingly implicated in periodontal regeneration<sup>[23,24]</sup> and the barrier function that is being attributed to this interfacial tissue.<sup>[22]</sup> For regeneration of acellular cementum during wound healing, this interfacial tissue is most important.<sup>[25,26]</sup> These important properties and functions of this junctional tissue at CDJ should be kept in mind during mechanical procedures such as root planing.

## CONCLUSION

The shear strength of CDJ is unknown. Furthermore, the optimal pressure for root planing that removes only necrotic cementum without the risk of complete cementum removal is still to be ascertained. It appears that it is required to develop pressure sensitive curettes for root planing to avoid overzealous root planing which can have a detrimental effect on CDJ. We like to propose that it is time to revisit the root planing procedure, as inadvertent root planing can remove this important biological link between the cementum and dentin – the interfacial tissue at CDJ.

## Financial support and sponsorship

Nil.

## Conflicts of interest

There are no conflicts of interest.

## REFERENCES

- Harrison JW, Roda RS. Intermediate cementum. Development, structure, composition, and potential functions. *Oral Surg Oral Med Oral Pathol Oral Radiol Endod* 1995;79:624-33.
- Bosshardt DD, Schroeder HE. Established of acellular extrinsic fiber cementum on human teeth: A light- and electron microscopic study. *Cell Tissue Res* 1991;263:325-36.
- Yamamoto T, Domon T, Takahashi S, Islam N, Suzuki R, Wakita M. The structure and function of the cemento-dentinal junction in human teeth. *J Periodontol Res* 1999;34:261-8.
- Hammarström L, Alati I, Fong CD. Origins of cementum. *Oral Dis* 1996;2:63-9.
- Lindskog S, Hammarström L. Formation of intermediate cementum. III: 3H-tryptophan and 3H-proline uptake into the epithelial root sheath of Hertwig *in vitro*. *J Craniofac Genet Dev Biol* 1982;2:171-7.
- Ten Cate AR. *Oral Histology: Development Structure and Function*. 3<sup>rd</sup> ed. St. Louis: CV Mosby; 1989. p. 59-89.
- Yamamoto T, Domon T, Takahashi S, Islam MN, Suzuki R. The fibrous structure of the cemento-dentinal junction in human molars shown by scanning electron microscopy combined with NaOH-maceration. *J Periodontol Res* 2000;35:59-64.
- Armitage GC, Christie TM. Structural changes in exposed human cementum I. Light microscopic observations. *J Periodontol Res* 1973;8:343-55.
- Armitage GC, Christie TM. Structural changes in exposed human cementum. II. Electron microscopic observations. *J Periodontol Res* 1973;8:356-65.
- Yamamoto T, Domon T, Takahashi S, Islam MN, Suzuki R. The fibrillar structure of the cemento-dentinal junction in different kinds of human teeth. *J Periodontol Res* 2001;36:317-21.
- Hayat MA. *Principles and Techniques of Electron Microscopy: Biologic Applications*. 4<sup>th</sup> ed. Cambridge (UK)Cambridge University Press; 2000. p. 336.
- Hayat MA. *Principles and Techniques of Electron Microscopy: Biologic Applications*. 4<sup>th</sup> ed. Cambridge (UK): Cambridge University Press.; 2000. p. 45-61.
- Adriaens PA, Edwards CA, De Boever JA, Loesche WJ. Ultrastructural observations on bacterial invasion in cementum and radicular dentin of periodontally diseased human teeth. *J Periodontol* 1988;59:493-503.
- Armitage GC, Ryder MI, Wilcox SE. Cemental changes in teeth with heavily infected root canals. *J Endod* 1983;9:127-30.
- Eide B, Lie T, Selvig KA. Surface coatings on dental cementum incident to periodontal disease. I. A scanning electron microscopic study. *J Clin Periodontol* 1983;10:157-71.
- Bigarre C, Yardin M. Demonstration of lipids in the pathologic granules in cementum and dentin in periodontal disease. *J Clin Periodontol* 1977;4:210-3.
- Daly CG, Seymour GJ, Kieser JB, Corbet EF. Histological assessment of periodontally involved cementum. *J Clin Periodontol* 1982;9:266-74.
- Nancy BC, RaymondAY, Jim W, RichardFC. A quantitative removal of cementum with hand curettes. *J Periodontol* 1990;61:293-9.
- Fukazawa E, Nishimura K. Superficial cemental curettage: Its efficacy in promoting improved cellular attachment on human root surfaces previously damaged by periodontitis. *J Periodontol* 1994;65:168-76.
- Zappa U, Smith B, Simona C, Graf H, Case D, Kim W. Root substance removal by scaling and root planing. *J Periodontol* 1991;62:750-4.
- Oberholzer R, Rateitschak KH. Root cleaning or root smoothing. An *in vivo* study. *J Clin Periodontol* 1996;23:326-30.
- Andreasen JO. Relationship between surface and inflammatory resorption and changes in the pulp after replantation of permanent incisors in monkeys. *J Endod* 1981;7:294-301.
- Pitaru S, Narayanan SA, Olson S, Savion N, Hekmati H, Alt I, *et al*. Specific cementum attachment protein enhances selectively the attachment and migration of periodontal cells to root surfaces. *J Periodontol Res* 1995;30:360-8.
- Metzger Z, Weinstock B, Dotan M, Narayanan AS, Pitaru S. Differential chemotactic effect of cementum attachment protein on periodontal cells. *J Periodontol Res* 1998;33:126-9.
- Leknes KN, Lie T, Selvig KA. Cemental tear: A risk factor in periodontal attachment loss. *J Periodontol* 1996;67:583-8.
- Schupbach P, Gaberthuel T, Lutz F, Guggenheim B. Periodontal repair or regeneration: Structures of different types of new attachment. *J Periodontol Res* 1993;28:281-93.