

Concurrent Multilevel Spinal Intra-medullary with Extensive Intracranial Tuberculomas: A Rare Case Report

Abstract

Disseminated tuberculomas in the brain and spinal cord are rare. To the best of our knowledge, only nine cases of spinal intra-medullary tuberculomas with cranial involvement have been reported till date. However, involvement of all levels in the spinal cord, brain stem with pan lobar involvement of the cerebrum and cerebellum has not been reported so far. We present such a case of a 12-year-old boy with history of pulmonary tuberculosis, who presented with gradual onset of quadriparesis and generalized seizures. We have discussed the unusual clinical presentation and the temporal changes in magnetic resonance imaging features along with clinical response to treatment. In cases reported so far, the plan of surgical versus medical management has been opted for variably, in cases of spinal intra-medullary involvement with acute neurological deficit. The decision is even more difficult in multilevel spinal intra-medullary tuberculomas. Our patient showed good clinico-radiological improvement with medical management.

Keywords: Central nervous system infection, concomitant cranio-spinal tuberculoma, intracranial tuberculoma, spinal tuberculoma, tuberculoma

Introduction

Tuberculosis has remained a major public health concern in developing countries. It is fast becoming a concern in developed countries as well, in view of rising human immunodeficiency virus (HIV) associated susceptibility. The central nervous system (CNS) involvement occurs in about 10% of the cases.^[1] Tuberculoma is the second most common manifestation of tuberculosis of the brain after meningitis. However, spinal tuberculomas are rare. The presence of both spinal (intradural-extramedullary or intra-medullary) and cranial tuberculomas in the same patient is very rare, with a handful of cases reported in literature [Table 1].^[2-12]

Case Report

The patient was a 12-year-old boy, with history of sputum-positive pulmonary tuberculosis for which he was already on anti-tubercular treatment for 3 months. He presented to us with an episode of generalized seizure which had been preceded by isolated right sixth nerve palsy, episodes of seizures and gradual onset, progressive quadriparesis over the past 1 month. On examination, he had postictal

confusion. Fundus examination revealed papilledema. He had a grade 3–4/5 spastic quadriparesis.

A magnetic resonance imaging (MRI) of the brain revealed multi-lobar tuberculomas of the brain with lesions in the brainstem and cerebellum [Figure 1]. MRI of the spine revealed cervical (C₂₋₃, C₇–D₁), dorsal (D₇, D₁₀, D₁₁₋₁₂) and lumbar (D₁₂–L₁ including conus medullaris), multiple homogeneous enhancing oval lesions [Figure 2]. Only a few lesions showed characteristic ring enhancement. Mantoux was positive (15 mm induration at 48 h) and tuberculosis-interferon- γ -release-assays (Quantiferon Tuberculosis Gold In-Tube) test were positive. Erythrocyte sedimentation rate (ESR) was 40 and serology for HIV was negative. The patient was continued anti-tubercular treatment and was supplemented with steroids for about a month. The boy showed gradual but definite clinical improvement by the time of discharge 7 days later. At 3 month follow-up, he was ambulant without support. Follow-up MRI of the brain and spine revealed reduction in the enhancement of the lesions with definite ring enhancing pattern now discernable [Figure 3a-c]. Complete

**Shyam Sundar
Krishnan,
Bhavinkumar
Rameshchandra
Patel,
Madabushi
Chakravarthy
Vasudevan**

Department of Neurosurgery,
Achanta Lakshmiopathi
Neurosurgical Centre, Voluntary
Health Services, Taramani,
Chennai, Tamil Nadu, India

Address for correspondence:
Dr. Shyam Sundar Krishnan,
Department of Neurosurgery,
Achanta Lakshmiopathi
Neurosurgical Centre, Voluntary
Health Services, TTTI Post,
Taramani, Chennai - 600 113,
Tamil Nadu, India.
E-mail: shyamsundar
krishnan76@gmail.com

Access this article online

Website: www.asianjns.org

DOI: 10.4103/1793-5482.185073

Quick Response Code:



How to cite this article: Krishnan SS, Patel BR, Vasudevan MC. Concurrent multilevel spinal intra-medullary with extensive intracranial tuberculomas: A rare case report. *Asian J Neurosurg* 2017;12:774-8.

This is an open access article distributed under the terms of the Creative Commons Attribution-NonCommercial-ShareAlike 3.0 License, which allows others to remix, tweak, and build upon the work non-commercially, as long as the author is credited and the new creations are licensed under the identical terms.

For reprints contact: reprints@medknow.com

Table 1: Year-wise list of concomitant cranial and spinal tuberculomas reported so far

Year	Author	Spine involvement		Cranial involvement	Symptoms		S _x
		IM/EM	Level		Cranial	Spinal	
1993	Shen <i>et al.</i> ^[2]	IM	Cervical thoracic	Brainstem, cerebral, cerebellum	No	Yes	No
1999	Huang <i>et al.</i> ^[3]	IM	Cervical thoracic	Basal subarachnoid space Left optic chiasma Internal auditory canal Right sylvian fissure	Yes	Yes	Yes
1999	Kim <i>et al.</i> ^[4]	EM	Thoracic	Right temporal, left basilar cistern	Yes	Yes	Yes
2003	Yen <i>et al.</i> ^[5]	IM	Thoracic lumbar	Brainstem, cerebral, cerebellum	No	Yes	Yes
2004	Thacker and Puri ^[6]	IM	Thoracic	Right cerebellum Right frontal	No	Yes	No
2004	Shenoy and Raja ^[7]	IM	Cervical	Cerebral	Yes	Yes	Yes
2005	Muthukumar <i>et al.</i> ^[8]	IM	Thoracic	Frontal, thalamus	Yes	Yes	Yes
2007	Muthukumar <i>et al.</i> ^[9]	EM	Thoracic	Multiple	No	Yes	Yes
2008	Park and Song ^[10]	IM	Thoracic	Subcortical area	Yes	Yes	Yes
2009	Chitre <i>et al.</i> ^[11]	IM	Thoracic	Left temporal region	Yes	Yes	Yes
2013	Lim <i>et al.</i> ^[12]	IM	Thoracic lumbar	Frontal, thalamus, cerebellum	No	Yes	No
2014	Present case report	IM	Multilevel spinal	Multi-lobar cerebral, cerebellar and brainstem	Yes	Yes	No

The type of spinal lesion IM or EM and the levels involved; The cranial lobes involved; Clinical presentation: Spinal or cranial or both; Treatment if it included surgery (S_x) besides medical treatment. EM – Extramedullary; IM – Intramedullary

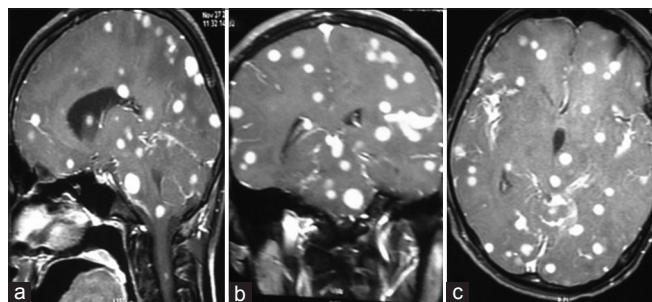


Figure 1: Magnetic resonance imaging brain T₁-contrast imaging showing multi-lobar tuberculomas diffusely enhancing with contrast. Sagittal, coronal, and axial contrast images revealing homogenous enhancing lesions (a-c respectively)

resolution of lesions on the last follow-up at the 8th month of treatment was seen [Figure 3d-f] and clinically he was ambulant with improvement in his VIth nerve palsy. We decided to continue anti-tubercular treatment for 18 months and the end of which he was free from any neurological deficits and back to productive life.

Discussion

CNS tuberculosis is a rare manifestation of extra-pulmonary tuberculosis. It occurs in only about 10% of patients with systemic tuberculosis. Meningitis is the most common manifestation followed by intracranial tuberculoma. The pathogenesis of CNS tuberculoma starts in the bacteremic phase usually from a primary focus, which most often is the lung. This is followed by the formation of a small tuberculous nidus in the brain or spinal cord called the Rich’s focus either in the sub-pial space, meninges or the sub-ependymal region. Further evolution of this lesion by

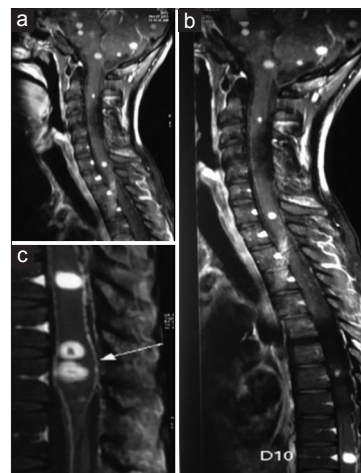


Figure 2: Magnetic resonance imaging spine T₁-contrast and Craniovertebral junction contrast imaging showing multilevel spinal involvement of tuberculomas—cervicomedullary, cervical lesions (a), cervical and dorsal spinal lesions (b), conus lesions (c)

either growth or rupture determines the further course of the disease. This progression is determined by the number and virulence of the bacteria, as well as the host immune response. If the lesion ruptures into the sub-arachnoid space or the ventricle, it results in meningitis which is the common CNS manifestation of the disease, whereas growth results in tuberculoma or a tubercular abscess formation.^[6,11,12]

Spinal cord involvement is rare as compared to the brain. The common intra-dural spinal manifestation of tuberculosis is meningitis and arachnoiditis. Intradural intra-medullary tuberculomas are very rare accounting for

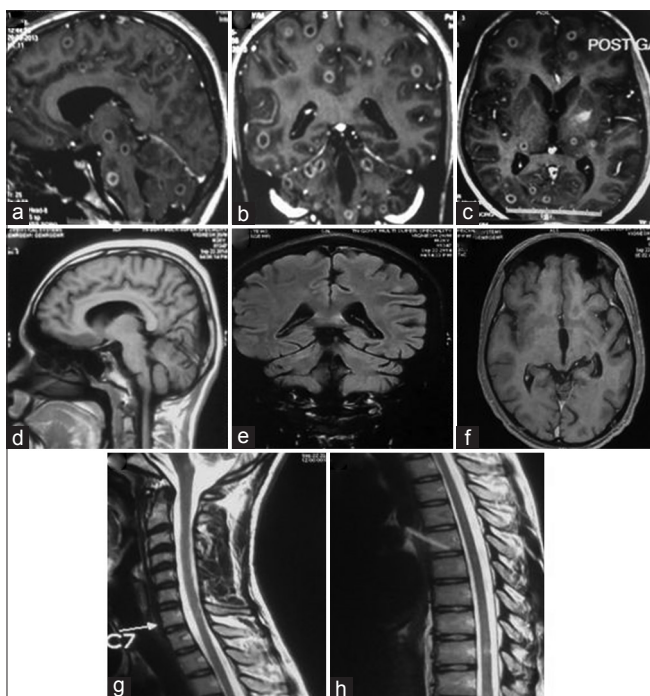


Figure 3: Sagittal, coronal, and axial magnetic resonance imaging T₁-contrast images showed evolution to a ring enhancing lesion with reduction in enhancement after 3 months of treatment (a-c respectively) which showed complete resolution after treatment (d-f). Similar resolution also noted in cervical and dorsal spine (g,h)

only about 0.2–0.5% of CNS tuberculomas and 7% of spinal tuberculomas.^[6,11,12] Usually, these lesions are single level lesions and commonly involve the dorsal spine. Multilevel occurrences are rare.

Intra-medullary spinal tuberculomas with concurrent intracranial tuberculoma are even more rare with only 9 case reported so far in literature [Table 1].^[2-12] Only 2 of these cases had multiple spinal and cranial lesions.^[2,5] Concurrent presence of multiple tuberculomas in the brainstem, all cerebral lobes and cerebellum along with extensive spinal involvement makes our patient's presentation unique. Usually such in cases of concomitant tuberculomas, patients present either with spinal or cranial tuberculoma, later progressing to other [Table 1].^[2-12] Our patient had initial presentation of raised intracranial pressure with seizures followed by spinal symptomatology of gradual progression to quadriplegia. This disparity in presenting symptomatology is equally distributed among the cases reviewed from literature.^[2-12]

Multiple tuberculoma, especially spinal tuberculomas, are common in immuno-compromised individuals either due to HIV infection or immunosuppressive therapy.^[7] Our patient was negative for both. The common differential diagnosis would be neurocysticercosis, multiple sclerosis, lymphoma, and metastasis besides the possibility of Cryptococcus in immuno-compromised patients. The Indian subcontinent being endemic to tuberculosis and neurocysticercosis meant, these becoming the most probable differential diagnosis.^[10,13,14]

The characteristic tuberculoma features on MRI can be diagnostic enough to start treatment without resorting to invasive biopsy, especially in developing countries with endemic tuberculosis.^[6,7,10] This, along with proof of tuberculosis elsewhere, or other adjunctive blood tests including polymerase chain reaction, tuberculosis-interferon- γ -release-assays, cerebrospinal fluid findings, and raised ESR values can be supplementary to the diagnostic approach in endemic areas.^[3,6,12] The follow-up image and/or the clinical response to treatment is an imperative in the management.^[3,11,12]

Raised intracranial pressure precluded lumbar puncture for cerebrospinal fluid analysis in our patient. However, history of sputum acid-fast bacilli positive pulmonary tuberculosis preceding both the cranial and spinal tuberculoma manifestation, tuberculosis-interferon- γ -release-assays (Quantiferon TB Gold In-Tube) positivity and the characteristic image findings, strengthened the diagnosis of tuberculous etiology and treatment for the same.

In these situations, the radio-pathological correlation of tuberculomas is essential for the diagnosis.^[5,6,15-17]

T₁-weighted images

Image

- The lesion is homogeneously hypointense or has a central isointensity/mixed isointensity with or without thick slight hyperintense rim and surrounding complete or partial hypointensity.

Pathological correlates

- The hyperintense layer corresponds to collagen layer, the hypointense surrounding is the surrounding inflammatory reaction and the central isointensity reflects the necrosis.

T₂-weighted images

Image

- The lesion has central hypointensity with peripheral hyperintensity due to edema. Occasional hyperintense center is also noted.

Pathological correlates

- Hypointensity reflects necrosis and/or also hypocellularity with increased macrophages and gliosis. The occasional hyperintensity represents increased cellularity with less gliosis and macrophages
- No discernable pathological layers are distinguishable on T₂-weighted images. Hypointensity is also related to high lipid content.

Contrast images

Image and pathological correlates

- The tuberculoma has initial giant-cell predominant inflammation without central caseation and poor

capsule formation. This stage reflects on contrast MRI as a homogenous enhancing lesion. The tuberculoma later undergoes central caseation reflecting on contrast MRI as ring-enhancing collagen-rich capsule with hypointense caseating center.

Our patient had similar MRI features in both cranial and spinal tuberculomas. There was a characteristic temporal sequence, which was reflected, in initial diffuse enhancement of lesion. This evolved to a more ring enhancing lesion on contrast with definite reduction in edema with treatment. This was reflected in his clinical improvement as well [Figure 3]. The standard four-drug regimen of anti-tubercular treatment (isoniazid, rifampin, ethambutol, and pyrazinamide) was used. The duration of treatment varies with institutions.^[12] We follow an 18-month regime with step-wise reduction from the 9th month onward to 3-drug then further to 2-drug regimen.

The recommendations for treatment for spinal tuberculoma—be it surgical or medical—are variable in literature[Table 1].^[2-12] For instance, Park *et al.* and Muthukumar *et al.* feel presenting features of profound paraplegia may better be given the benefit of surgery before irreversible damage sets in as may be the case if decision to operate is delayed in favor of a period of medical management.^[8,10] In addition, proponents of surgical treatment feel, a hard well-circumscribed tuberculoma is a well-demarcated lesion and its removal carries less chances of the deficit.^[12] The other point of view is that most of these lesions resolve with anti-tubercular treatment and surgery should be reserved for paradoxical enlargement, mass effect, or diagnostic dilemma.^[7,8] Three of the nine cases reported in literature—Shen *et al.*, Thaker *et al.* and Lim *et al.*—adopted conservative medical treatment with equal measure of success.^[2,6,12] In this perspective, our patient had multiple lesions and at all spinal levels, it may be difficult to decide on the level for intervention and extent of procedure in a such case in case surgery is contemplated.

Tuberculomas of the brain and spinal cord can paradoxically increase in number—which is visualization of previously invisible lesions and size, when on anti-tubercular treatment. This does not mean failure of treatment but is due to the paradoxical response of the host, to the chemotherapy-induced destruction and release of mycobacterial products.^[7-9]

Our patient was not screened for spinal and cranial tuberculomas at the time of diagnosis of pulmonary tuberculosis. Hence, it is difficult to comment if there was flare-up of lesions due to reduced host immunity or paradoxical unmasking of lesions as mentioned above or further seeding from the pulmonary primary although on anti-tubercular treatment. He, however, had a significant improvement in symptoms with continuation of the medical treatment.

Conclusion

The significance of the case report is in its rarity of presentation as presence of multiple levels spinal and cranial multiple tuberculomas in an otherwise non-immuno-compromised individual. This case report highlights the need for looking out for cranial tuberculomas in patients presenting with spinal lesions and vice versa. It also reinforces medical management as credible line of treatment even in the presence of neurological deficit, but at the same time this decision, we agree, has to be case specific and cannot be generalized.

Financial support and sponsorship

Nil.

Conflicts of interest

There are no conflicts of interest.

References

- MacDonnell AH, Baird RW, Bronze MS. Intramedullary tuberculomas of the spinal cord: Case report and review. *Rev Infect Dis* 1990;12:432-9.
- Shen WC, Cheng TY, Lee SK, Ho YJ, Lee KR. Disseminated tuberculomas in spinal cord and brain demonstrated by MRI with gadolinium-DTPA. *Neuroradiology* 1993;35:213-5.
- Huang CR, Lui CC, Chang WN, Wu HS, Chen HJ. Neuroimages of disseminated neurotuberculosis: Report of one case. *Clin Imaging* 1999;23:218-22.
- Kim MS, Kim KJ, Chung CK, Kim HJ. Intradural extramedullary tuberculoma of the spinal cord: A case report. *J Korean Med Sci* 2000;15:368-70.
- Yen HL, Lee RJ, Lin JW, Chen HJ. Multiple tuberculomas in the brain and spinal cord: A case report. *Spine (Phila Pa 1976)* 2003;28:E499-502.
- Thacker MM, Puri AI. Concurrent intra-medullary and intra-cranial tuberculomas. *J Postgrad Med* 2004;50:107-9.
- Shenoy SN, Raja A. Concurrent intramedullary and intracerebral tuberculomas. *Neurol India* 2004;52:514-6.
- Muthukumar N, Venkatesh G, Senthilbabu S, Rajbaskar R. Surgery for intramedullary tuberculoma of the spinal cord: Report of 2 cases. *Surg Neurol* 2006;66:69-74.
- Muthukumar N, Sureshkumar V, Ramesh VG. En plaque intradural extramedullary spinal tuberculoma and concurrent intracranial tuberculomas: Paradoxical response to antituberculous therapy. Case report. *J Neurosurg Spine* 2007;6:169-73.
- Park HS, Song YJ. Multiple tuberculoma involving the brain and spinal cord in a patient with miliary pulmonary tuberculosis. *J Korean Neurosurg Soc* 2008;44:36-9.
- Chitre PS, Tullu MS, Sawant HV, Ghildiyal RG. Co-occurrence of intracerebral tuberculoma with lumbar intramedullary tuberculoma. *J Child Neurol* 2009;24:606-9.
- Lim YS, Kim SB, Kim MK, Lim YJ. Disseminated tuberculosis of central nervous system: Spinal intramedullary and intracranial tuberculomas. *J Korean Neurosurg Soc* 2013;54:61-4.
- Del Brutto OH, Rajshekhar V, White AC Jr., Tsang VC, Nash TE, Takayanagui OM, *et al.* Proposed diagnostic criteria for neurocysticercosis. *Neurology* 2001;57:177-83.
- Garg RK. Diagnostic criteria for neurocysticercosis: Some modifications are needed for Indian patients. *Neurol India* 2004;52:171-7.

15. Kim TK, Chang KH, Kim CJ, Goo JM, Kook MC, Han MH. Intracranial tuberculoma: Comparison of MR with pathologic findings. *AJNR Am J Neuroradiol* 1995;16:1903-8.
16. Gupta RK, Pandey R, Khan EM, Mittal P, Gujral RB, Chhabra DK. Intracranial tuberculomas: MRI signal intensity correlation with histopathology and localised proton spectroscopy. *Magn Reson Imaging* 1993;11:443-9.
17. Wasay M, Kheleani BA, Moolani MK, Zaheer J, Pui M, Hasan S, *et al.* Brain CT and MRI findings in 100 consecutive patients with intracranial tuberculoma. *J Neuroimaging* 2003;13:240-7.