

## Left atrial appendage mass: is it always a thrombus?

Hikmet Sahratov<sup>1</sup>, Adem Guler<sup>1</sup>, Mustafa Kurkluoglu<sup>1</sup>, Fahri Gurkan Yesil<sup>2</sup>, Murat Tavlasoglu<sup>1</sup>, Faruk Cingoz<sup>1</sup>

<sup>1</sup>Department of Cardiovascular Surgery, Gulhane School of Medicine, Ankara, Turkey

<sup>2</sup>Department of Cardiovascular Surgery, Etimesgut Military Hospital, Ankara, Turkey



Kardiocirurgia i Torakocirurgia 2016; 13 (4): 359-360

### Abstract

Myxoma is the most common benign tumor of the heart, but it is very rare for it to originate from the left atrial appendage. Distinguishing between a mass, a thrombus, and a tumor in the body of the left atrium with preoperative transthoracic or transesophageal echocardiography is very difficult, even more so in patients with mitral valve disease and chronic atrial fibrillation. A 50-year-old male patient was admitted for surgery with the diagnosis of mitral stenosis and chronic atrial fibrillation. Transesophageal echocardiography demonstrated a mass attached to the wall of the left atrial appendage. Histopathological examination of the mass showed an image compatible with a myxoma. We hereby describe a case of a left atrial appendage myxoma mimicking a left atrial appendage thrombus.

**Key words:** left atrial appendage, myxoma, mitral valve.

### Streszczenie

Śluzak jest najczęściej spotykanym łagodnym guzem serca, który rzadko jednak występuje w uszku lewego przedsionka. Rozróżnienie pomiędzy masą, zakrzepem a guzem wewnątrz lewego przedsionka za pomocą przedoperacyjnej echokardiografii przezklatkowej lub przezprzełykowej jest trudnym zadaniem, szczególnie w przypadku pacjentów ze schorzeniami zastawki mitralnej i przewlekłym migotaniem przedsionków. Mężczyzna 50-letni, u którego zdiagnozowano zwężenie zastawki mitralnej i przewlekłe migotanie przedsionków, został przyjęty w celu przeprowadzenia zabiegu chirurgicznego. Przezprzełykowa echokardiografia wykazała obecność masy przyłączonej do ściany uszka lewego przedsionka. Obraz uzyskany w badaniach histopatologicznych odpowiadał śluzakowi. W pracy przedstawiono przypadek śluzaka uszka lewego przedsionka naśladującego zakrzep w uszku lewego przedsionka.

**Słowa kluczowe:** uszko lewego przedsionka, śluzak, zastawka mitralna.

### Introduction

Myxomas are the most common benign tumors of the heart. Cardiac myxomas are found in the left atrium in 80–90% of cases and are often attached to the interatrial septum. Myxomas originating from the left atrial appendage are very rare. In this report, we present a patient in whom surgery was performed after the diagnosis of mitral valve stenosis, chronic atrial fibrillation, and a possible left atrial appendage (LAA) thrombus (which was incidentally diagnosed as a myxoma).

### Case report

The 50-year-old male patient was admitted for surgery with the diagnosis of mitral stenosis and chronic atrial fibrillation. Two-dimensional transthoracic echocardiography showed severe mitral valve insufficiency and reported spontaneous echo contrast which could signify the presence of a thrombus in the left atrium. Transesophageal echocardiography demonstrated a mass attached to the wall of the left atrial appendage. Surgery was performed

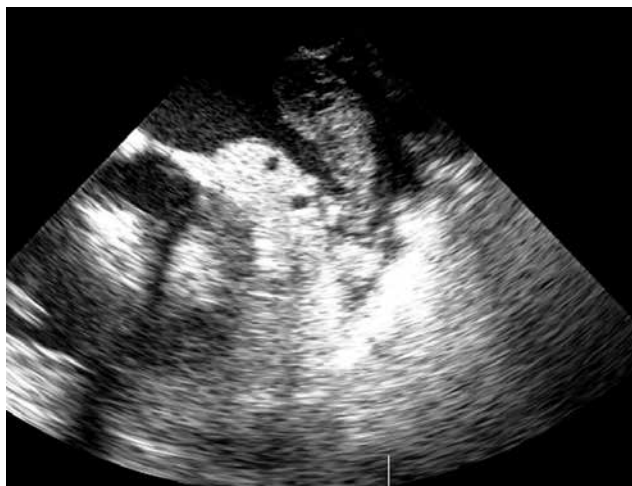via median sternotomy with cardiopulmonary bypass. The left atrium was explored after cardioplegic arrest; within, fragile areas containing white tissue mass and attached to the left atrial appendage were observed (Fig. 1). After the mass was removed, the LAA was plicated internally and excised externally. Mitral valve replacement was performed. The postoperative period was uneventful. Histopathological examination showed an image compatible with a myxoma containing myxomatous areas (Fig. 2).

### Discussion

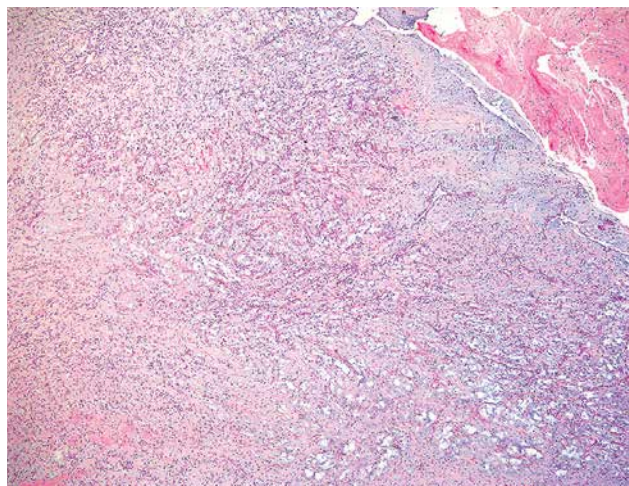
Atrial myxomas are encountered in 0.2% to 0.3% of the general population. Their most common symptom is exertional dyspnea, but they can also cause fever, weight loss, syncope, sudden death, and hemoptysis [1, 2]. A cardiac myxoma is usually attached to the left atrial side of the interatrial septum near the region of the fossa ovalis [3]. However, in very rare cases, myxomas can originate from the LAA. It is very rare to see any mass other than a thrombus at the left atrial appendage, especially in patients with

**Address for correspondence:** Hikmet Sahratov PhD, Gulhane School of Medicine, Etlik, Emrah, Apart oteli, No: 220, 06010 Ankara, Turkey, phone: +90 5345488890, fax: +90 3123045225, e-mail: sahratzade@gmail.com

**Received:** 28.05.2016, **accepted:** 10.10.2016.



**Fig. 1.** Transesophageal echocardiography showing a mass attached to the left atrial appendage



**Fig. 2.** Histopathology revealed the tumor to be a myxoma with some fibrin exudation at the periphery

atrial fibrillation [4]. The other factors that also led us to mistake the myxoma for a thrombus were the presence of atrial fibrillation and the underlying mitral stenosis.

On the echocardiogram, myxomas are typically seen as attached to the endocardium with a pedicle [3]. If the location of the pedicle is not fully identified on echocardiography, it may be difficult to differentiate a left atrial myxoma from a thrombus [5]. It is important to distinguish between thrombi and myxomas preoperatively, but it may sometimes be challenging [6]. Myxomas are generally located within the body of the left atrium; they are bigger, pedunculated, and mobile. Thrombi are usually located in the left atrial appendage; they are immobile and have a wider base.

New imaging techniques, such as myocardial perfusion contrast echocardiography, are used to differentiate cardiac masses. Contrast echocardiography enables the analysis of the vascular pattern of the cardiac mass: benign tumors generally exhibit lower vascularity than malignant tumors, while thrombi are avascular [2].

Thrombi and myxomas originating in the LAA are not always easy to differentiate. If there are no constitutive symptoms such as fever, weight loss, arthralgia, or myalgia, distinguishing between these two entities becomes more difficult. When there is clinical suspicion of an LAA mass, the presence of a myxoma can be diagnosed early with myocardial perfusion contrast echocardiography.

## Conclusions

Distinguishing between LAA thrombi and myxomas preoperatively using echocardiography is very difficult because of morphological similarities between these two entities. Histopathological examination of the surgically removed mass is a precise method for diagnosing LAA myxomas.

## Disclosure

Authors report no conflict of interest.

## References

1. Kiyani S, Aksay E. Left atrial myxoma. *J Emerg Med* 2007; 33: 73-74.
2. Al Zahrani IM, Alraqtan A, Rezk A, Almasswary A, Bella A. Atrial myxoma related myocardial infarction: case report and review of the literature. *J Saudi Heart Assoc* 2014; 26: 166-169.
3. Malik L, Borgohain S, Gupta A, Grover V, Gupta VK. Left atrial appendage myxoma masquerading as left atrial appendage thrombus. *Asian Cardiovasc Thorac Ann* 2013; 21: 205-207.
4. Turhan S, Kilickap M, Candemir B, Berkalp B, Eren NT, Akgun G. Three unusual myxomas originating from the left atrial appendage: a case report. *J Am Soc Echocardiogr* 2005; 18: 694.
5. Dhawan S, Tak T. Left atrial mass: thrombus mimicking myxoma. *Echocardiography* 2004; 21: 621-623.
6. Sim EK, Lim YT, Ng WL, Goh JJ, Reebye S. Co-existing left atrial thrombus and myxoma in mitral stenosis: a diagnostic challenge. *Singapore Med J* 1999; 40: 46-47.