


CASE REPORT

Case report of COVID-19 in a kidney transplant recipient: Does immunosuppression alter the clinical presentation?

Elena Guillen¹ | Gaston J. Pineiro^{1,3} | Ignacio Revuelta^{1,3} | Diana Rodriguez¹ |
 Marta Bodro² | Asunción Moreno² | Josep M. Campistol^{1,3} | Fritz Diekmann^{1,3,4}  |
 Pedro Ventura-Aguar^{1,3} 

¹Department of Nephrology and Kidney Transplantation, Hospital Clinic Barcelona, Barcelona, Spain

²Department of Infectious Diseases, Hospital Clinic Barcelona, Barcelona, Spain

³Laboratori Experimental de Nefrologia i Trasplantament (LENIT), Institut d'Investigacions Biomèdiques August Pi i Sunyer (IDIBAPS), Barcelona, Spain

⁴Red de Investigación Renal (REDINREN), Madrid, Spain

Correspondence

Fritz Diekmann

Email: fdiekman@clinic.cat

COVID-19 is novel infectious disease with an evolving understanding of its epidemiology and clinical manifestations. Immunocompromised patients often present atypical presentations of viral diseases. Herein we report a case of a COVID-19 infection in a solid organ transplant recipient, in which the first clinical symptoms were of gastrointestinal viral disease and fever, which further progressed to respiratory symptoms in 48 hours. In these high risk populations, protocols for screening for SARS-Cov2 may be needed to be re-evaluated.

1 | BACKGROUND

Coronavirus Disease 2019 (COVID-19) is a novel viral disease with over 93 000 confirmed cases worldwide,¹ in which knowledge regarding disease epidemiology and clinical presentation has been evolving in the past 4 months since the initial identification. In the general population, the reported case fatality rate is about 1%-6%.²

Solid organ transplant (SOT) recipients are under chronic immunosuppression, and respiratory infections may present atypically, often with two or more infectious processes presenting simultaneously.³ There have been currently only a couple of reports of COVID-19 among SOT recipients. Hence, in such a high risk population, a strong clinical suspicion is crucial. Herein we present the case of a COVID-19 infection in a kidney transplant recipient.

2 | CASE REPORT

A 50-year-old man with end-stage renal disease due to IgA nephropathy, recipient of a 3rd deceased-donor kidney transplant in 2016 with serum creatinine (Cr) of 1.3 mg/dL and estimated glomerular filtration rate (eGFR) of 60 mL/min, was admitted on February

28 to the emergency room (ER) with a 24-hour history of fever (38.2°C/100.8°F) and vomiting. He reported no other symptoms, nor had a history of travels abroad nor exposure to patients infected or suspected of contagious COVID-19.

Previous medical history included an elective splenectomy performed in 2003 due to immune thrombocytopenia, and an Epstein-Barr virus (EBV)-associated post-transplant lymphoproliferative disease (PTLD) in 2005, treated with rituximab and withdrawal of immunosuppression, achieving complete response of the PTLD, but leading to rejection and failure of the 2nd kidney graft. Following PTLD remission and a negative EBV viral load, he received a 3rd kidney transplant with induction immunosuppression (IS) with thymoglobulin, tacrolimus, everolimus and steroids, and maintenance IS with tacrolimus, everolimus and prednisone 5 mg QD. He was also under treatment with losartan 50 mg bid due to arterial hypertension.

At first evaluation in the ER the patient presented signs of mild dehydration. Physical examination was otherwise unremarkable, including breath sounds on chest auscultation. On blood workup acute phase reactants were normal, such as a C-reactive protein (CRP) of <0.50 mg/dL (normal range <1.0 mg/dL) and white blood cells (WBC) count of $8.58 \times 10^9/L$, but a mild kidney function impairment (Cr

1.6 mg/dL, eGFR 50 mL/min). He was discharged with a presumptive diagnosis of non-severe viral gastroenteritis, and oral hydration and on demand acetaminophen were prescribed.

Five days later patient returned to the ER with persistent fever, but at this time, with productive cough. He no longer presented gastrointestinal symptoms.

Physical examination revealed a body temperature of 37.4°C, blood pressure of 180/100 mm Hg, pulse of 66 beats per minute, respiratory rate of 16 breaths per minute, and blood oxygen saturation of 98% on room air. He presented with signs of mucous dehydration and crackles in the right lower lung, as well as signs of conjunctivitis of his left eye. He presented no murmurs, rubs or gallops on heart exam. His abdomen was soft and nontender, and neurologic examination was unremarkable.

WBC count on peripheral blood was $10.15 \times 10^9/L$ (total lymphocyte count $1.8 \times 10^9 U/L$), with a platelet count of $126 \times 10^9/L$, a CRP of 13.2 mg/dL, and a procalcitonin of 0-18 ng/mL (normal range <0.50 ng/mL). Persistent mild kidney function impairment (Cr 1.6 mg/dL) and hyponatremia of 129 mEq/L were also observed. Liver transaminases and coagulation were within normal reference values. There was a medium lobe consolidation on posteroanterior chest radiograph (Figure 1A). Therefore, the diagnosis of community-acquired pneumonia was assumed, and he was empirically started on ceftriaxone 1 g QD and azithromycin 500 mg QD. A nasopharyngeal swab specimen was performed, and a rapid nucleic acid amplification test for influenza A and B and respiratory syncytial virus were reported back as negative.

Thereafter, although the patient didn't have any travel history nor reported known contacts with contagious or infected people, nasopharyngeal and oropharyngeal swab specimens were collected for testing COVID-19, following an update of local authorities' screening protocol of pneumonia of undetermined aetiology. Both swabs for SARS-CoV-2 by real-time reverse-transcriptase-polymerase-chain-reaction (rRT-PCR) assay were reported positive (hereafter assumed as reference day - D0).

Local protocol for COVID-19 was activated, with patient hospitalization under isolation, and treatment with oral Lopinavir/

Ritonavir 400/100 BID was initiated at D+1 (Figure 2). Due to the interaction of Ritonavir with calcineurin inhibitors, tacrolimus was withdrawn, as was everolimus due to its reported risk for mTOR-inhibitor induced pneumonitis.⁴ Empirical broad spectrum antibiotic was also initiated (ceftaroline and meropenem) and maintained, despite negative microbiological cultures for viral, bacterial, or fungal infections, including aspergillosis, pneumocystis, and mycobacteria's. Oral hydroxychloroquine treatment was prescribed (400 mg BID for 24 hours, afterwards 200 mg BID; oral).

After 10 days since the initial symptoms and 72 hours after supportive and anti-viral treatment, the patient presented a worsening in respiratory symptoms, with hypoxia in spite of the use of high-flux nasal oxygen delivery, and a progression to diffuse bilateral infiltrates on chest X-ray (Figure 1B). Interferon Beta was initiated at this moment. The patient was intubated (D+6), with ventilatory supportive care using high positive end-respiratory pressure (PEEP; 12 cm H₂O). Serum creatinine increased to 2.1 mg/dL (GFR of 30 mL/min), with tacrolimus through level 10 days after suspension remaining at 5.1 ng/mL. As of today (D+12), the patient remains under respiratory supportive therapy in the ICU, hemodynamically stable, under treatment with Lopinavir/Ritonavir 400/100 mg BID (oral solution—pending a switch to Remdesivir once it is available at the hospital), Interferon Beta (250 mcg every 48 hours; subcutaneous), and Hydroxychloroquine (200 mg BID; oral), with serum creatinine of 3.0 mg/dL, Leucocytes $14.5 \times 10^9 U/L$, Lymphocytes $0.9 \times 10^9 U/L$, Haemoglobin 9.3g/dL, platelet count of $410 \times 10^9 U/L$, D-Dimer of 8900 ng/mL (normal range <500), and procalcitonin of 0.54 ng/mL without further progression of respiratory failure.

3 | DISCUSSION

A novel coronavirus was identified at the end of the year 2019 in Wuhan, China. There are 7 subtypes of coronaviruses that are infective to humans. Among these, the beta-coronaviruses are associated with potentially severe disease. The International Committee on Taxonomy of Viruses named this novel virus as Severe Acute

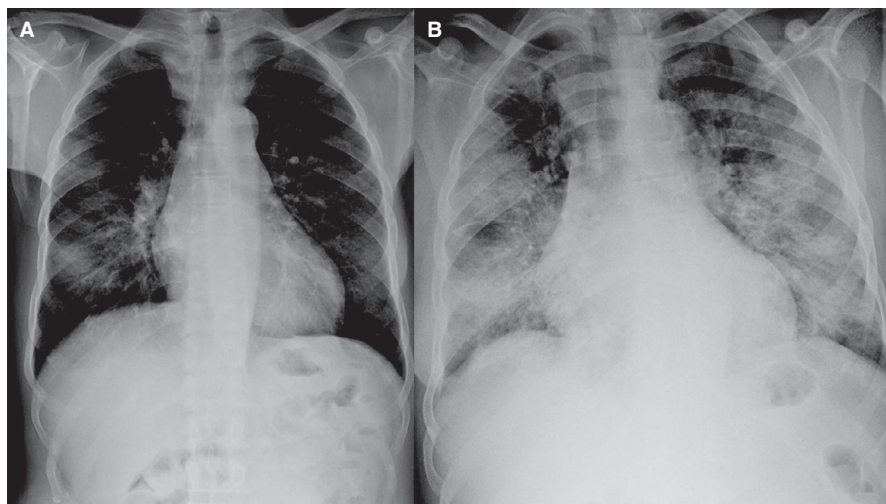


FIGURE 1 Patient's chest X-ray (A) at emergency department following 72 h of first symptoms, and (B) 72 h after admission and prior to need to mechanical ventilation

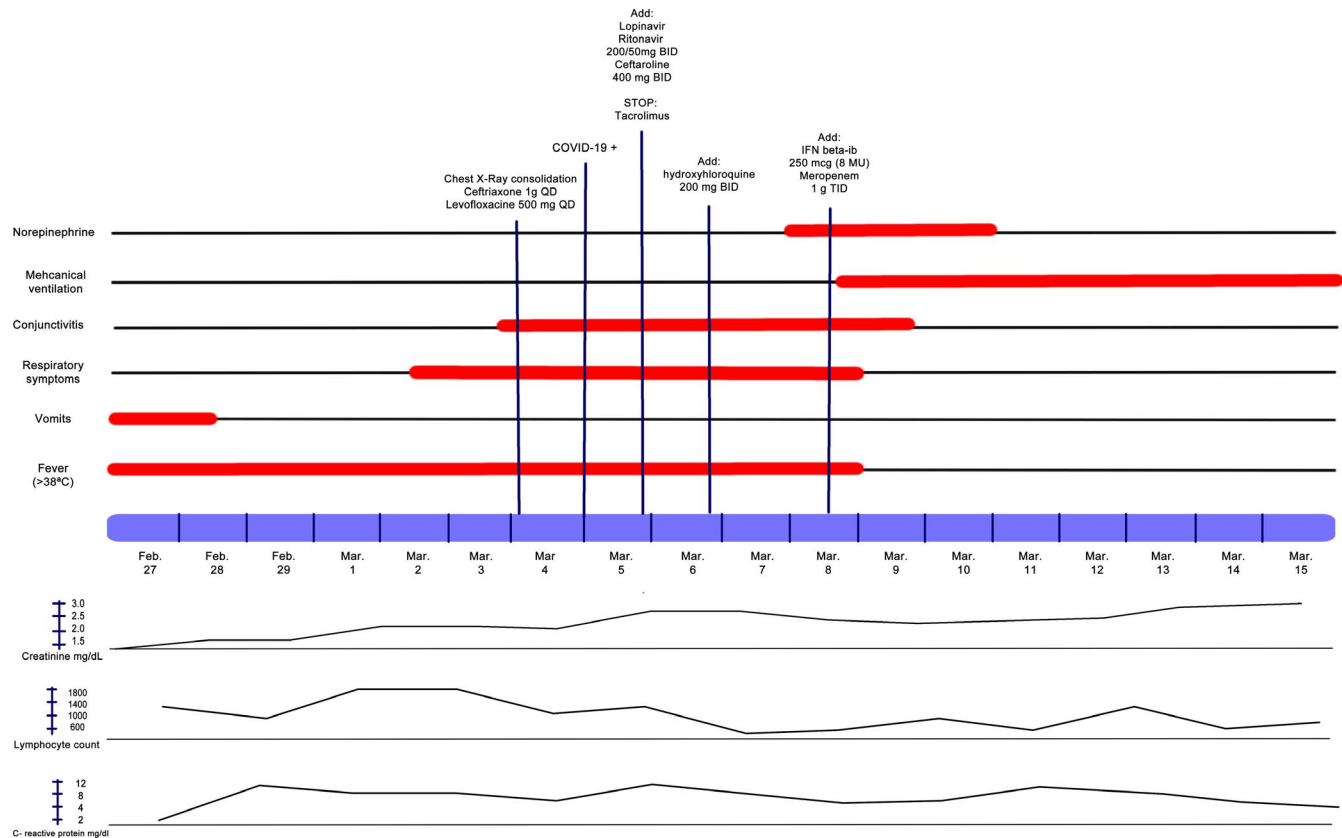


FIGURE 2 Graphic representation of symptoms presentation, diagnostic workup, treatment, and progression of creatinine levels [Color figure can be viewed at wileyonlinelibrary.com]

Respiratory Syndrome Coronavirus 2 (SARS-CoV-2), and the World Health Organization (WHO) named the associated as COVID-19. SARS-CoV-2 is closely related to the SARS-CoV and MERS-CoV, which were responsible for past outbreaks with significant morbidity and mortality.²

COVID-19's rapid spread has resulted in an epidemic throughout China and is now globally spreading. So far, 93 090 cases have been diagnosed worldwide.¹ In Spain, the first case was diagnosed on January 31, 2020, and to date, 9191 cases have been diagnosed.⁵

Initially, our patient presented with symptoms of malaise, fever, and vomiting with unremarkable lab tests and no respiratory symptoms. Gastrointestinal symptoms have been reported as part of the initial clinical presentation, but they are rather rare (around 3%-5% depending on the series).^{2,6,7} Two days later he also had productive cough without dyspnea, and his fever persisted. On the fourth day, he presented conjunctivitis of his left eye. A chest x-ray showed an opacity compatible with right lower lobe pneumonia, and his CRP rose to 13 mg/dL. This is compatible with serious reported cases, where pneumonia appears to be the most frequent serious manifestation of infection. It is characterized primarily by fever and cough, but it is usually accompanied by dyspnea, and bilateral instead of unilateral infiltrates on chest imaging.⁷ This could be related to the fact that he had a normal total lymphocyte count, and that the severity of the disease has been associated with lymphopenia.⁸ His conjunctivitis is

also an infrequent symptom, that could be explained by evidence that the virus may be present in conjunctival secretions, with around 0.8% of cases presenting with conjunctival congestion.⁹⁻¹³

Our protocol at patient admission recommended screening for SARS-Cov2 in (1) patients presenting respiratory symptoms and epidemiologic risk of contact with infected or contagious individuals and (2) patients presenting with pneumonia of unknown origin. Nevertheless, in immunocompromised populations, such as SOT recipients, COVID-19 infection should be considered in the presence of an atypical presentation and screening protocols may be needed to be re-evaluated. Hence, and since the increase in the number of cases and evidence of asymptomatic transmission among the community, contact with infected individuals was no longer mandatory.

In the general population, the reported case fatality rate is low, about 1%-6%. However, most of the fatal cases have occurred in patients with advanced age or underlying medical comorbidities. Therefore, high risk populations need more careful attention.¹³ In solid organ transplantation only two cases have been reported from the experience in China.¹⁴ Both were heart transplant recipients, with ages similar to our patient's. One of the reported cases is similar to the one herein, with an atypical presentation (fever, diarrhea, fatigue) without respiratory symptoms. Both these cases and now the one reported here highlight the need towards high suspicious and low threshold towards screening these patients for SARS-Cov2.

We would like to emphasize the challenging differential diagnosis of this case. Due to high accumulated immunosuppressive load, initial gastrointestinal symptoms and electrolyte disorders (hyponatremia) associated with a unilobar pneumonia in a transplanted patient, we first approached the case as a community-acquired pneumonia due to encapsulated bacteria. Thus, pneumococcal urinary antigen, as well as sputum and blood cultures were requested. Furthermore, the fact that our patient did not have any epidemiologic risk factor for COVID-19 infection, made the diagnostic suspicion even more difficult.

In conclusion, this is a case report of COVID-19 in a solid organ transplant recipient, and it reminds us that immunocompromised patients may present with atypical clinical manifestations. Thus, when faced with a transplanted patient with an unspecified viral clinical presentation, and without any microbiological isolation, we call upon all the medical personnel to be aware and take COVID-19 into account as a potential diagnosis, especially in epidemic areas.

DISCLOSURE

The authors of this manuscript have no conflicts of interest to disclose as described by the *American Journal of Transplantation*.

DATA AVAILABILITY STATEMENT

The data that support the findings of this study are available on request from the corresponding author. The data are not publicly available due to privacy or ethical restrictions.

ORCID

Fritz Diekmann  <https://orcid.org/0000-0001-6199-3016>

Pedro Ventura-Aguilar  <https://orcid.org/0000-0003-3381-7503>

REFERENCES

1. World Health Organization. Coronavirus disease 2019 (COVID-19) Situation Report – 44. https://www.who.int/docs/default-source/coronaviruse/situation-reports/20200304-sitrep-44-covid-19.pdf?sfvrsn=783b4c9d_6.
2. Sun P, Lu X, Xu C, Sun W, Pan B. Understanding of COVID-19 based on current evidence [published online ahead of print 2020]. *J Med Virol*. <https://doi.org/10.1002/jmv.25722>
3. Shelhamer JH, Toews GB, Masur H, et al. Respiratory disease in the immunosuppressed patient. *Ann Intern Med*. 1992;117(5):415-431.
4. Ventura-Aguilar P, Campistol JM, Diekmann F. Safety of mTOR inhibitors in adult solid organ transplantation. *Expert Opin Drug Saf*. 2016;15(3):303-319.
5. Ministerio de Sanidad. Gobierno de España. Enfermedad por el coronavirus (COVID-19) – Situación actual. https://www.mscbs.gob.es/profesionales/saludPublica/ccayes/alertasActual/nCov-China/documentos/Actualizacion_37B_COVID-19_18.00. Accessed March 16, 2020.
6. Gao QY, Chen YX, Fang JY. 2019. Novel coronavirus infection and gastrointestinal tract [published online ahead of print 2020]. *J Dig Dis*. <https://doi.org/10.1111/1751-2980.12851>
7. Huang C, Wang Y, Li X, et al. Clinical features of patients infected with 2019 novel coronavirus in Wuhan, China. *Lancet*. 2020;395(10223):497-506.
8. Tan L, Wang Q, Zhang D, et al. Lymphopenia predicts disease severity of COVID-19: a descriptive and predictive study. *Sig Transduct Target Ther*. 2020;5:33. <https://doi.org/10.1038/s41392-020-0148-4>
9. Chang D, Xu H, Rebaza A, Sharma L, Dela Cruz CS. Protecting health-care workers from subclinical coronavirus infection. *Lancet Respir Med*. 2020;8(3):e13.
10. Report of the WHO-China Joint Mission on coronavirus Disease 2019 (COVID-19). 2020;2019:16-24.
11. Guan W-J, Ni Z-Y, Hu Y, et al. Clinical characteristics of coronavirus disease 2019 in China. *N Engl J Med*. 2020:1-13. <https://doi.org/10.1056/NEJMoa2002032>.
12. The Novel Coronavirus Pneumonia Emergency Response Epidemiology Team. The epidemiological characteristics of an outbreak of 2019 novel coronavirus disease (COVID-19) – China, 2020. *China CDC Weekly*. 2020;2:1-10.
13. Wu Z, McGoogan JM. Characteristics of and important lessons from the coronavirus disease 2019 (COVID-19) outbreak in China: summary of a report of 72 314 cases from the Chinese Center for Disease Control and Prevention [published online ahead of print February 24, 2020]. *JAMA*. <https://doi.org/10.1001/jama.2020.2648>
14. Li F, Cai J, Dong N. First cases of COVID-19 in heart transplantation from China [published online ahead of print March 17, 2020]. *J Heart Lung Transplant*. <https://doi.org/10.1016/j.healun.2020.03.006>

How to cite this article: Guillen E, Pineiro GJ, Revuelta I, et al. Case report of COVID-19 in a kidney transplant recipient: Does immunosuppression alter the clinical presentation?. *Am J Transplant*. 2020;20:1875–1878. <https://doi.org/10.1111/ajt.15874>