

Posterior fusion of the occipital axis in children with upper cervical disorder using both C2 pedicle and laminar screws (C2 hybrid screws)

Kenyu Ito, Shiro Imagama, Kei Ando, Kazuyoshi Kobayashi, Mikito Tsushima, Akiyuki Matsumoto, Masayoshi Morozumi, Satoshi Tanaka, Masaaki Machino, Yoshihiro Nishida and Naoki Ishiguro

Department of Orthopaedic Surgery, Nagoya University Graduate School of Medicine, Aichi, Japan

Abstract:

Introduction: An occipital-cervical surgery for children is challenging for surgeons because of the immature bone quality, extensive anatomical variability, and small osseous structures. Furthermore, occipital-C2 fusion in children results in great stress on the C2 screws. We report a technique that uses both C2 pedicle and bilateral lateral mass screws (C2 hybrid screws) in children with an upper cervical disorder to preserve motion segment and secure strength in those who require occipital-cervical fusion.

Case Report: Case 1 was that of a 5-year-old girl with Down syndrome who had atlantoaxial dislocation and os odontoidem. Owing to the C1 hypoplasia, the posterior arch was fractured by the C1 lateral mass screw. Therefore, O-C2 fusion was performed. C2 bilateral lamina screws were added along with the C2 bilateral pedicle screws for reinforcement. Case 2 was that of an 8-year-old boy who presented with torticollis and neck pain. The patient was diagnosed as having atlantoaxial rotatory fixation. The right vertebral artery was obstructed, and the left vertebral artery was dominant. The C1 posterior arch was bifid and assimilated with the occipital bone. C2 bilateral lamina screws were added with the right C2 pedicle screw for reinforcement. Both cases attained bone union after O-C2 fusion surgery using hybrid screws.

Conclusions: The use of C2 hybrid screws with both C2 pedicle and bilateral lateral mass screws can preserve mobile segments in the fusion area in young children who require occipital-cervical fixation.

Keywords:

occipital, cervical, fusion, pedicle screw, laminar screw, hybrid, children

Spine Surg Relat Res 2018; 2(1): 82-85

[dx.doi.org/10.22603/ssrr.2017-0033](https://doi.org/10.22603/ssrr.2017-0033)

Introduction

Recently, cervical fusion and occipito-cervical fusion have been performed for children owing to the development in implant devices¹⁻⁴. However, upper cervical fixation is considered difficult for children due to the thin lamina and narrow pedicle. Furthermore, occipital-C2 fusion in children results in great stress on the C2 screws.

Several reports have described the use of a C2 laminar screw (LS) without a pedicle screw (PS) for occipital-cervical fusion in pediatric patients⁵⁻⁷. However, the fusion area expands to C3 or more caudally. To preserve a motion segment and secure strength in pediatric patients who need occipital-cervical fusion, the use of both PSs and bilateral LSs may help. Here we report a technique that uses both

PSs and bilateral LSs (C2 hybrid screws) in children with an upper cervical disorder.

Case presentation

Surgical technique

All patients wore a halo-vest for a few days preoperatively to improve cervical alignment. Under general anesthesia, the patients were placed in the prone position, and the dorsal portion of the halo-vest was removed. The C2 PS was inserted under cone-beam computed tomography (CT) with navigation and if the C2 PS strength was weak, bilateral C2 LSs were added for reinforcement and inserted using the Wright technique⁸. Offset rods were used to connect the C2

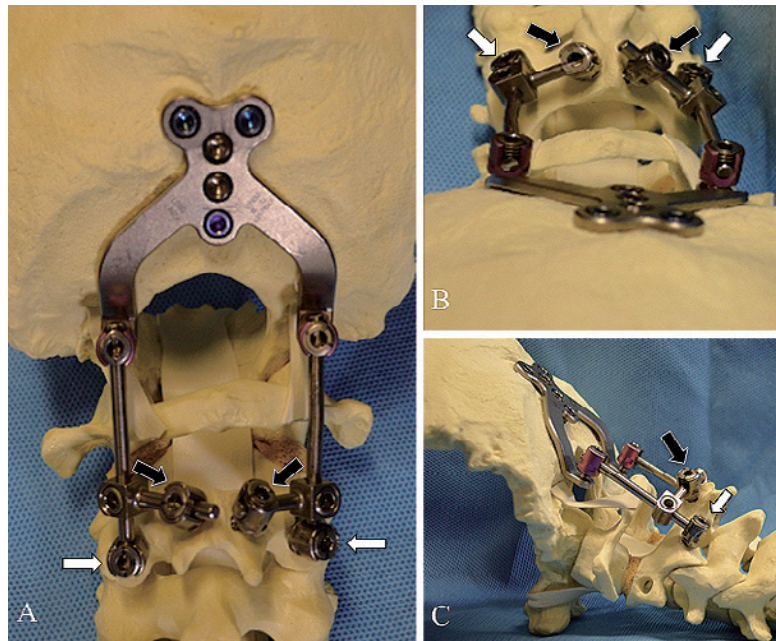


Figure 1. A model of occipital-C2 hybrid screw using both pedicle (white arrows) and laminar screws (black arrows). Posterior (A), cranial (B), and lateral (C) view.

The occipital plate and C2 pedicle screws were connected using rods.

Offset rods were used to connect the C2 lateral mass screw and the rods.

LS and O-C2 PS rods (Fig. 1).

Case 1

A 5-year-old girl with Down syndrome had gait disturbance. Her height was 97.5 cm (-2.7 SD) and weight was 13 kg (-2 SD). CT scans showed os odontoideum and irreducible atlantoaxial dislocation. Owing to hypoplasia of C1 and spinal bifida of the C1 posterior arch, occipital-C2 fusion using PS was performed with a monocortical structural iliac bone graft. Recurring fever and occipital screw backout was postoperatively observed. One month after removal, the separate-type occipital plate was replaced with a central-type plate reinforced with a soft wire. To match the strength of the reinforced occipital screws, the expansion of the cervical fusion area was considered. However, to preserve the motion segment, C2 hybrid screws were used. The 3.5-mm C2 PSs were replaced with 4.0-mm screws. C2 LSs, 3.5 mm and 20 mm long for both the laminae, were added for reinforcement. A halo-vest was used at postoperative 3 months, and no gait disturbance was observed. Bone union was confirmed during follow-up examinations (Fig. 2).

Case 2

An 8-year-old boy presented with atlantoaxial rotatory fixation (AARF) with torticollis and neck pain. His height was 128.5 cm (-0.6 SD) and weight was 23.7 kg (-1 SD). Although the patient was treated with a neck collar, Glisson neck traction, and halo-vest for 5 months, he did not recover.

The C1 posterior arch was bifid and assimilated with the

occipital bone. The left, narrow C2 pedicle and right vertebral artery obstruction required the avoidance of insertion of the left C2 PS. A surgery was planned to insert the right C2 PS and both LSs. The 3.5-mm and 20-mm long right C2 PS, 3.5-mm and 20-mm long left LS, and 3.5-mm and 28-mm long right LS were inserted. The occipital and hybrid C2 screws were connected with an iliac bone autograft. A halo-vest was used at postoperative 3 months. Bone union was confirmed during follow-up examinations (Fig. 3).

Discussion

Occipital and cervical surgeries for children are challenging for surgeons because of immature bone quality and small osseous structures⁹⁻¹⁵. When C1 shows hypoplasia, it should be skipped, and the lower instrumented vertebra should be considered as C2. In this situation, C2 screws receive the weight of the occipital bone so that the lower instrumented vertebra can be extended to C3 or below. To preserve motion segment and ensure sufficient strength in pediatric patients who require occipital-C2 fusion, C2 hybrid screws are used, as in our cases. C2 lamina is the largest cervical lamina, which allows the use of various trajectories of C2 LS, whereas the use of C2 PS is technically challenging⁸. Therefore, a trajectory of C2 LS is adjusted with the ideal insertion of C2 PS.

One of the concerns when using a C2 hybrid screw is the limited contact area for bone grafting. In our cases, the bone graft was shaved to avoid the head of the C2 LS, and good contact was obtained. Finally, bone union was confirmed in

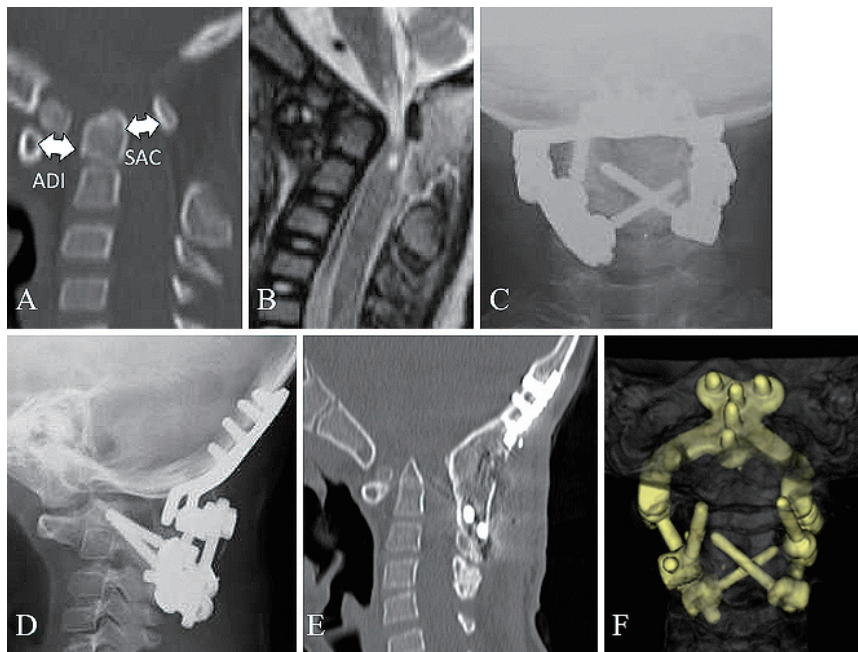


Figure 2. Case 1: 5-year-old girl with Down syndrome.
 (A) Preoperatively, CT demonstrated atlantoaxial dislocation, os odontoideum, atlas-dens interval (ADI) of 8.8 mm, and space available for spinal cord (SAC) of 7.0 mm.
 (B) MRI suggested high intensity change in the spinal cord on the T2 weighed at the cervicomedullary junction.
 (C, D) Postoperatively, X-ray imaging revealed O-C2 hybrid fusion.
 (E) On follow-up CT, bone union was confirmed.
 (F) Anterior view of 3D constructed CT demonstrates the bilateral C2 pedicle screws and C2 laminar screws.

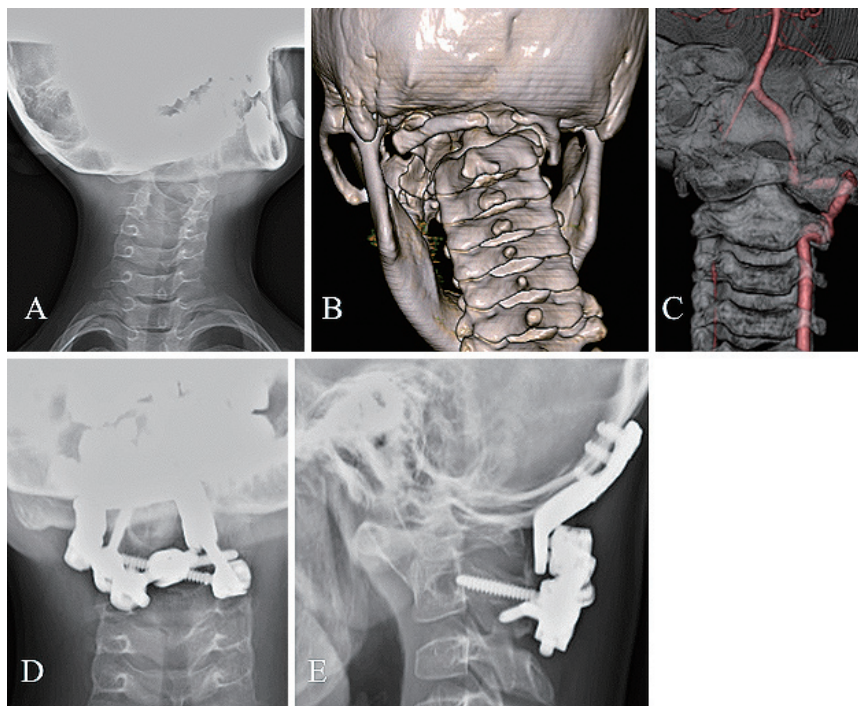


Figure 3. Case 2: 8-year-old boy with atlantoaxial rotatory fixation.
 (A) X-ray imaging revealed torticollis.
 (B, C) 3D CT demonstrated the assimilation of C1 bifida and C1 right posterior arch with the occipital bone. Right vertebral artery was obstructed, and left vertebral artery was dominant.
 (D, E) Postoperatively, X-ray imaging revealed O-C2 hybrid fusion.

both cases and the symptoms improved.

In conclusion, C2 hybrid screws save mobile segments within the fusion area in pediatric patients who require an occipital-cervical fixation.

Conflicts of Interest: The authors declare that there are no conflicts of interest.

References

1. Hedequist D, Hresko T, Proctor M. Modern cervical spine instrumentation in children. *Spine (Phila Pa 1976)*. 2008;33(4):379-83. eng.
2. Heuer GG, Hardesty DA, Bhowmick DA, et al. Treatment of pediatric atlantoaxial instability with traditional and modified Goel-Harms fusion constructs. *Eur Spine J*. 2009;18(6):884-92. eng.
3. Hwang SW, Gressot LV, Rangel-Castilla L, et al. Outcomes of instrumented fusion in the pediatric cervical spine. *J Neurosurg Spine*. 2012;17(5):397-409. eng.
4. Rajasekaran S, Kanna PR, Shetty AP. Safety of cervical pedicle screw insertion in children: a clinicoradiological evaluation of computer-assisted insertion of 51 cervical pedicle screws including 28 subaxial pedicle screws in 16 children. *Spine (Phila Pa 1976)*. 2012;37(4):E216-23. eng.
5. Chern JJ, Chamoun RB, Whitehead WE, et al. Computed tomography morphometric analysis for axial and subaxial translaminar screw placement in the pediatric cervical spine. *Journal of neurosurgery Pediatrics*. 2009;3(2):121-8. eng.
6. Chamoun RB, Relyea KM, Johnson KK, et al. Use of axial and subaxial translaminar screw fixation in the management of upper cervical spinal instability in a series of 7 children. *Neurosurgery*. 2009;64(4):734-9;discussion 9. eng.
7. Singh B, Cree A. Laminar screw fixation of the axis in the pediatric population: a series of eight patients. *The spine journal: official journal of the North American Spine Society*. 2015;15(2):e17-25. eng.
8. Wright NM. Posterior C2 fixation using bilateral, crossing C2 laminar screws: case series and technical note. *Journal of spinal disorders & techniques*. 2004;17(2):158-62. eng.
9. Martich V, Ben-Ami T, Yousefzadeh DK, et al. Hypoplastic posterior arch of C-1 in children with Down syndrome: a double jeopardy. *Radiology*. 1992;183(1):125-8. eng.
10. Bertapelli F, Martin JE, Goncalves EM, et al. Growth curves in Down syndrome: Implications for clinical practice. *Am J Med Genet A*. 2013. eng.
11. Cronk C, Crocker AC, Pueschel SM, et al. Growth charts for children with Down syndrome: 1 month to 18 years of age. *Pediatrics*. 1988;81(1):102-10. eng.
12. Pueschel SM, Orson JM, Boylan JM, et al. Adolescent development in males with Down syndrome. *Am J Dis Child*. 1985;139(3):236-8. eng.
13. Guijarro M, Valero C, Paule B, et al. Bone mass in young adults with Down syndrome. *J Intellect Disabil Res*. 2008;52(Pt 3):182-9. eng.
14. McKelvey KD, Fowler TW, Akel NS, et al. Low bone turnover and low bone density in a cohort of adults with Down syndrome. *Osteoporos Int*. 2013;24(4):1333-8. eng.
15. Wu J. Bone mass and density in preadolescent boys with and without Down syndrome. *Osteoporos Int*. 2013;24(11):2847-54. eng.

Spine Surgery and Related Research is an Open Access article distributed under the Creative Commons Attribution - NonCommercial - NoDerivatives 4.0 International License. To view the details of this license, please visit (<https://creativecommons.org/licenses/by-nc-nd/4.0/>).