

# Novel mutation in the periaxin gene causal to Charcot–Marie–Tooth disease type 4F

Journal of International Medical Research

48(2) 1–7

© The Author(s) 2019

Article reuse guidelines:

[sagepub.com/journals-permissions](http://sagepub.com/journals-permissions)

DOI: 10.1177/0300060519862064

[journals.sagepub.com/home/imr](http://journals.sagepub.com/home/imr)



Yu-hui Chen<sup>1</sup>, Hua Zhang<sup>1</sup>, Ling-bing Meng<sup>1</sup>,  
Xiao-yan Tang<sup>2</sup>, Tao Gong<sup>1</sup> and Jian Yin<sup>1</sup> 

## Abstract

Charcot–Marie–Tooth (CMT) disease is the most common hereditary neuropathy. Mutations in the periaxin gene (*PRX*) can cause CMT type 4F, an autosomal recessive neuropathy, which is clinically characterized by slowly progressive distal muscle atrophy and weakness, with pes cavus deformity of the foot, and the absence of deep tendon reflexes. To date, dozens of reports of *PRX* mutations have been published worldwide, but none have been reported in Chinese patients. Here, we describe a 14-year-old Chinese boy with neuropathy characterized by slowly progressive limb weakness and atrophy, as well as sensory ataxia, whose cerebrospinal protein levels were 1627 mg/L. Genetic analysis identified a novel homozygous mutation, c.1174C>T (p.R392X), in exon 6 of *PRX*, which is the first case of its kind recorded in China.

## Keywords

Charcot–Marie–Tooth disease, periaxin, c.1174C>T (p.R392X), muscle atrophy, sensory ataxia, cerebrospinal protein

Date received: 25 April 2019; accepted: 17 June 2019

## Introduction

The periaxin gene (*PRX*) is located on chromosome 19q13.13–13.2 and encodes a myelin-associated protein that plays an important role in maintaining the stability of myelin.<sup>1</sup> Periaxin binds peripheral nerve fibers to the cytoskeleton and functions in

<sup>1</sup>Neurology Department, Beijing Hospital, National Center of Gerontology, Beijing 100730, P. R. China

<sup>2</sup>Clinical Laboratory of Zhongke, Beijing 102200, P. R. China

### Corresponding author:

Jian Yin, Neurology Department, Beijing Hospital, National Center of Gerontology, No. 1 Dahua Road, Dong Dan, Beijing 100730, P. R. China.  
Email: [silverbox@vip.sina.com](mailto:silverbox@vip.sina.com)



the development of peripheral nerve fibers.<sup>2</sup> Abnormal PRX expression caused by *PRX* mutations causes poor myelin generation, demyelination, and other peripheral nerve changes.<sup>1,3-7</sup> To date, dozens of patients with *PRX* mutations have been reported worldwide, including those with nonsense, missense, and frameshift mutations.<sup>8</sup> However, none of these mutations have been found in Chinese patients. In this paper, we report a novel homogenous point nonsense mutation in *PRX* in a 14-year-old Chinese boy.

## Case Report

The patient is a 14-year-old boy who is the second child of healthy, nonconsanguineous Chinese parents. He has a healthy older sister. He started to walk at the age of 1.5 years. Although his gait was clumsy and he was prone to falling down, this did not greatly affect his daily life. His symptoms progressed slowly. At the age of 7 years, the muscles in his limbs were so weak that he had difficulty standing up from a squatting position and could not pick up food with chopsticks. He was also noted to have scoliosis and pes cavus. At the age of 14, he can still walk independently and feed himself with a spoon.

Neurological examination revealed a thin body habitus, scoliosis, and bilateral pes cavus. He showed severe weakness and foot eversion with no proximal muscle involvement. His muscle weaknesses were much more pronounced distally (a 4/5 Medical Research Council score) than proximally (5/5). Sensitivities to pinprick, touch, position, and vibration decreased distally up to the knee and elbow level; the vibration sensation was more severely disturbed than pain sensations in all limbs. Sensory ataxia and a positive Romberg sign were also present. Deep tendon reflexes were absent and pathologic reflexes were

negative. His gait was slightly broad-based and unsteady.

Blood, urine routine, and stool tests were negative, and his coagulation function and blood biochemical tests, including hepatic, renal function, glucose, lipid, and ion concentrations, were normal. Tumor biomarkers and autoimmune antibodies were negative, and serum M protein was also negative. Hepatitis B and C, syphilis, and HIV tests were all negative. A lumbar puncture revealed that the cerebrospinal fluid (CSF) pressure was 175 mmH<sub>2</sub>O (normal range, 80–180 mm H<sub>2</sub>O), CSF leukocytes were 1/mm<sup>3</sup> (normal range, 0–5/mm<sup>3</sup>), CSF protein levels were greatly elevated at 1627 mg/L (normal range, 150–450 mg/L), and the oligoclonal band of CSF was negative.

A chest X-ray, electrocardiogram, and transthoracic echocardiography found no dysfunction. One cyst (1.1 × 0.8 mm) was detected in the right kidney, but the other organs were normal. Brain magnetic resonance imaging (MRI) was also normal. Spinal MRI detected spinal scoliosis, but no abnormal signal was found. Fundus examination was normal.

Electrophysiologic examinations revealed absent compound muscle action potentials (CMAPs) in the median, ulnar, peroneal, and tibial nerves, and absent sensory nerve action potentials in the median, ulnar, and sural nerves. Motor nerve conduction velocity (NCV) and sensory nerve conduction were absent in all peripheral nerves. A needle electromyogram showed insertional activity (+), spontaneous activity (+), and severely reduced recruitment of motor unit potentials. Motor unit action potentials had a prolonged duration and increased amplitude (15.5 ms and 2793 μV, respectively, in the tibialis anterior muscle, and 9.1 ms and 1174 μV, respectively, in the first dorsal interosseous muscle). The electromyographic examination was consistent with chronic reinnervation. Electrophysiologic examinations of the

**Table 1.** Electrophysiologic manifestation of the patient and his family members.

Nerves	Items	Patient (14 years)	Father (48 years)	Mother (47 years)	Sister (20 years)
<b>Motor</b>					
Right/left ulnar	Distal latency (ms)	NR	2.7/2.5	2.5	2.1
	MNCV (m/s)	NR	54.1/57.3	64.0	62.7
	Amplitude (mV)	NR	5.2/4.8	11.4	9.9
Right/left median	Distal latency (ms)	NR	3.1/3.1	3.3	2.6
	MNCV (m/s)	NR	55.7/57.4	61.5	62.3
	Amplitude (mV)	NR	6.4/6.9	2.9	7.8
Right/left peroneal	Distal latency (ms)	NR	3.3/3.6	2.7	3.1/3.8
	MNCV (m/s)	NR	41.6/45.3	47.9	48.6/47.7
	Ampl (mV)	NR	6.0/4.6	5.7	7.8/6.2
Right/left tibial	Distal latency (ms)	NR	4.1/3.9	3.1	3.3
	MNCV (m/s)	NR	40.1/41.6	45.8	51.1
	Amplitude (mV)	NR	8.7/9.9	11.8	17.3
<b>Sensory</b>					
Right/left ulnar	SCV (m/s)	NR	57.1/59.9	58.7/55.9	59.3/54.4
	Amplitude ( $\mu$ V)	NR	14.4/26.6	42.6/44.3	45.1/55.9
Right/left median	SCV (m/s)	NR	62.2/62.5	56.1/54.3	61.2/56.4
	Amplitude ( $\mu$ V)	NR	27.3/18.2	39.8/44.1	64.0/47.4
Right/left peroneal	SCV (m/s)	NR	45.7/49.4	49.5/48.0	52.6/53.7
	Amplitude ( $\mu$ V)	NR	8.5/7.5	16.8/22.8	35.0/9.2
Right/left tibial	SCV (m/s)	NR	47.9/50.8	53.1/51.0	49.5/49.0
	Amplitude ( $\mu$ V)	NR	6.4/7.9	13.9/11.3	25.6/34.0

MNCV = motor nerve conduction velocity; NR = not recordable; SCV = sensory nerve conduction velocity.

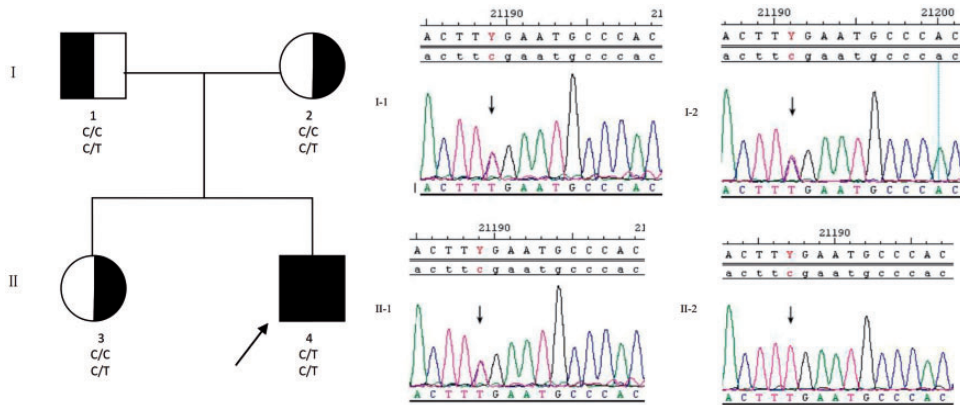
patient's parents and sister showed that their sensory nerve conduction and motor nerve conduction were within normal ranges (Table 1). The patient and his parents refused muscle and nerve biopsy tests.

Because Charcot–Marie–Tooth disease (CMT) is the most common hereditary neuropathy with infantile onset and limb atrophy, we screened 39 CMT-related genes using high-throughput sequencing technology. This identified a homozygous mutation, c.1174C>T (p.R392X), in exon 6 of *PRX* that was the most likely cause of disease in the patient (Figure 1). This research conformed to the Declaration of Helsinki and was authorized by the Human Ethics and Research Ethics Committees of Beijing Hospital. Informed consent was obtained from the patient.

## Discussion

*PRX* on chromosome 19q13.13-q13.2 encodes periaxin, which is a vital structural protein for correct maintenance of the peripheral nerve myelin sheath and for Schwann cell compartmentalization. Periaxin has two isoforms generated by alternative splicing: L-periaxin and S-periaxin.<sup>1,2</sup> L-periaxin is composed of 1461 amino acids and is located mainly in the cell membrane and nucleus, while S-periaxin contains only 147 amino acids and is mostly found in the cytoplasm. In immature myelin, periaxin proteins are typically located near the axon membrane; in mature myelin, they are further away from the axon membrane.

L-periaxin has four characteristic domains: PDZ, nuclear localization signal



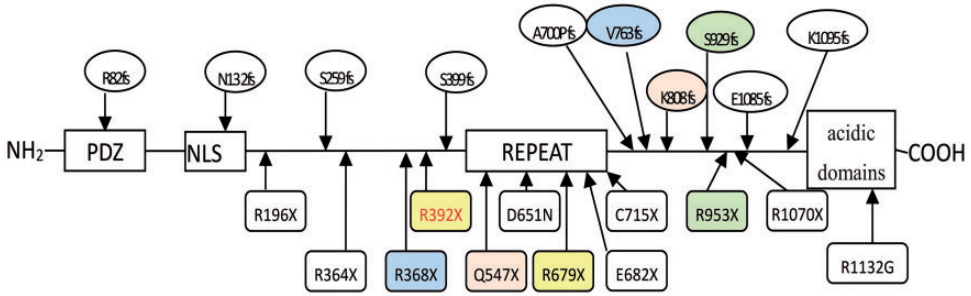
**Figure I.** Causative homozygous point mutation, c.1174C>T (p.R392X), in exon 6 of *PRX*.

(NLS), repeat, and acidic.<sup>9–11</sup> The PDZ domain interacts with proteins, peptide ligands, and liposomes to form homogeneous or heterogeneous dimers,<sup>12</sup> while the NLS domain mediates the export of L-periaxin from the nucleus to the cytoplasm. L-periaxin stabilizes the dystroglycan–glycoprotein complex by directly interacting with dystrophin-related protein 2, linking the basal lamina to the Schwann cell cytoskeleton and contributing, together with utrophin and extracellular laminin, to the correct compartmentalization and elongation of Schwann cells.<sup>13,14</sup> Acidic domains may mediate protein–protein interactions and enable L-periaxin to bind to the cytoskeleton of Schwann cells or transmit signals, leading to stabilized myelin formation.<sup>15</sup>

To date, dozens of patients have been described with around 30 different *PRX* mutations (Figure 2). These include nonsense, missense, point, and frameshift mutations,<sup>1,3,4,15–21,22</sup> and most affect the synthesis of L-periaxin. Eleven pathogenic point mutations have been detected,<sup>1,3,4,16–22</sup> of which one is a missense mutation<sup>15,18</sup> while the remainder are nonsense mutations. Twenty-two patients were reported to harbor homozygous nonsense/missense mutations,<sup>1,3,4,16–20</sup> of whom 14

are from three families<sup>1,3,4,17</sup> and the remaining eight are sporadic. Half of the 22 patients had consanguinity. Ten of the *PRX* frameshift mutation loci are pathogenic and affect 30 patients.<sup>5,15–17,22–25</sup> Twenty-four cases are from Reunion Island,<sup>5</sup> suggesting that they derive from the same ancestor. Complex heterozygous mutations are relatively rare, with only six reported cases<sup>8,15,16,21,22</sup> of whom two are from the same family.<sup>16</sup> None of the parents were inbred.

Most patients with *PRX* mutations have an onset of symptoms as infants or young children while others were middle-aged.<sup>18</sup> The main characteristics include motor retardation, an unsteady gait, atrophy, weakness in proximal and distal muscles, peripheral sensory disorders, deep sensory disturbance, and even sensory ataxia. Additionally, patient extremities lack tendon reflexes, and most patients develop dysmorphic features including scoliosis, kyphosis, and pes cavus. Electrophysiological examination reveals an NCV that is undetectable or less than 10 cm/s, although some patients have a NCV >20 cm/s.<sup>17,18</sup> Neuropathological examination reveals a characteristic decrease of myelin sheath fibers accompanied by hypoplasia of myelin fibers, thin myelin sheaths, and an ‘onion bulb’ appearance.<sup>1,3,4,15–22</sup>



**Figure 2.** *PRX* mutation sites according to the published literature. The same color indicates one patient with two mutation sites.

Our patient had very high CSF protein levels of 1627 mg/L, which compares with a previous study reporting mildly elevated CSF protein of 580 mg/L.<sup>15</sup> We propose two reasons for this observed high increase of CSF protein. First, *PRX* is expressed in peripheral nerves where it maintains the function of the peripheral nerve myelin sheath and Schwann cell compartmentalization. Therefore, *PRX* mutations may impair peripheral neuropathy, leading to peripheral nerve demyelination and hypoplasia of myelin fibers. Second, *PRX* is also expressed in human cerebral capillary endothelial cells where it establishes endothelial tight junctions and plays an important role in maintaining the brain–blood barrier BBB function and reducing permeability.<sup>26</sup> Therefore, *PRX* mutations may reduce the BBB function enabling molecules to leak into the CSF.

The present study has some limitations. First, we did not investigate the presence of this *PRX* variant in healthy controls because of limited sources; this should be done in future studies. Second, we did not measure CMAPs in proximal muscles. We propose to detect these in the proximal muscles of future patients if they demonstrate similar symptoms to this present case.

In summary, inherited peripheral neuropathy caused by *PRX* mutations is characterized by early-onset distal limb

weakness and atrophy that is more severe in lower than upper limbs. Sensory disturbance is prominent in affected patients, especially deep sensory disturbance, which is the main characteristic of this disease. Most patients have pes cavus, scoliosis, and other skeletal deformities, and most show progressive disease. The oldest patient reported in the literature was 60 years old. Around 29% of patients carrying *PRX* mutations are disabled;<sup>5</sup> for example, a patient carrying *PRX* C715X was deaf,<sup>17</sup> *PRX* D651N was detected in an individual with hoarseness and vocal cord paralysis,<sup>18</sup> while *PRX* R82fsX96<sup>17</sup> was associated with weakness and atrophy of tongue muscles. Therefore, the possibility of *PRX* mutations should be considered in patients with distal limb weakness and atrophy associated with sensory disturbance, and further screening of relevant gene loci is needed for diagnosis.

To the best of our knowledge, this is the first patient of Chinese origin with a *PRX* mutation. Additionally, this novel homozygous nonsense mutation, c.1174C>T (p.R392X), in exon 6 of *PRX* has not been reported before. Although mutation p.R392X has previously been documented as pathogenic in a pair of compound heterozygote nonsense mutations,<sup>21</sup> we consider it to be causative of disease in the present case as a homozygous mutation. *PRX* mutations may not cause severe early-onset

CMT with autosomal recessive inheritance, but the presence of early-onset prominent distal limb weakness should justify genetic testing of *PRX* mutations. Additionally, CMT patients with extremely low or undetectable sensory and motor nerve conduction and high levels of CSF protein should be considered for *PRX* screening.

### Acknowledgements

We thank the Neurology Department of Beijing Hospital for technical assistance in nerve biopsy preparation.

### Author contributions

Yu-hui Chen and Hua Zhang contributed to writing the manuscript and its submission. Jian Yin and Tao Gong made substantial contributions to the study conception, and drafted the manuscript. Ling-bing Meng critically revised the manuscript for intellectual content. Xiaoyan Tang examined the patient's genotype and mutation locus. All authors read and approved the final manuscript.

### Declaration of conflicting interest

The authors declare that there is no conflict of interest.

### Funding

This research received no specific grant from any funding agency in the public, commercial, or not-for-profit sectors.

### ORCID iD

Jian Yin  <https://orcid.org/0000-0002-9654-8358>

### References

1. Delague V, Bareil C, Tuffery S, et al. Mapping of a new locus for autosomal recessive demyelinating Charcot-Marie-Tooth disease to 19q13.1-13.3 in a large consanguineous Lebanese family: exclusion of *MAG* as a candidate gene. *Am J Hum Genet* 2000; 67: 236–243. doi: 10.1086/302980.
2. Dytrych L, Sherman DL, Gillespie CS, et al. Two PDZ domain proteins encoded by the murine periaxin gene are the result of alternative intron retention and are differentially targeted in Schwann cells. *J Biol Chem* 1998; 273: 5794–800.
3. Guilbot A, Williams A, Ravise N, et al. A mutation in periaxin is responsible for CMT4F, an autosomal recessive form of Charcot-Marie-Tooth disease. *Hum Mol Genet* 2001; 10: 415–421.
4. Nouioua S, Hamadouche T, Funalot B, et al. Novel mutations in the *PRX* and the *MTMR2* genes are responsible for unusual Charcot-Marie-Tooth disease phenotypes. *Neuromuscul Disord* 2011; 21: 543–550. doi: 10.1016/j.nmd.2011.04.013.
5. Renouil M, Stojkovic T, Jacquemont ML, et al. [Charcot-Marie-Tooth disease associated with periaxin mutations (CMT4F): Clinical, electrophysiological and genetic analysis of 24 patients]. *Rev Neurol (Paris)* 2013; 169: 603–612. doi: 10.1016/j.neurol.2013.07.004.
6. Dohrn MF, Glockle N, Mulahasanovic L, et al. Frequent genes in rare diseases: panel-based next generation sequencing to disclose causal mutations in hereditary neuropathies. *J Neurochem* 2017; 143: 507–522. doi: 10.1111/jnc.14217.
7. Kim S, Maynard JC, Sasaki Y, et al. Schwann cell O-GlcNAc glycosylation is required for myelin maintenance and axon integrity. *J Neurosci* 2016; 36: 9633–9646. doi: 10.1523/jneurosci.1235-16.2016.
8. Williams HJ, Hurst JR, Ocaka L, et al. The use of whole-exome sequencing to disentangle complex phenotypes. *Eur J Hum Genet* 2016; 24: 298–301. doi: 10.1038/ejhg.2015.121.
9. Sherman DL and Brophy PJ. A tripartite nuclear localization signal in the PDZ-domain protein L-periaxin. *J Biol Chem* 2000; 275: 4537–4540.
10. Liang M, Peng T and Shi Y. [Establishment of L-periaxin gene knock-out RSC96 cell line]. *Sheng wu gong cheng xue bao* 2016; 32: 1735–1744. doi: 10.13345/j.cjb.160170.

11. Yang Y, Ren Y and Shi Y. Intermolecular disulfide bond in the dimerization of S-periaxin mediated by Cys88 and Cys139. *Acta Biochim Biophys Sin (Shanghai)* 2016; 48: 326–33. doi: 10.1093/abbs/gmw008.
12. Shi Y, Zhang L and Yang T. Nuclear export of L-periaxin, mediated by its nuclear export signal in the PDZ domain. *PLoS One* 2014; 9: e91953. doi: 10.1371/journal.pone.0091953.
13. Scherer SS, Xu YT, Bannerman PG, et al. Periaxin expression in myelinating Schwann cells: modulation by axon-glia interactions and polarized localization during development. *Development* 1995; 121: 4265–4273.
14. Court FA, Hewitt JE, Davies K, et al. A laminin-2, dystroglycan, utrophin axis is required for compartmentalization and elongation of myelin segments. *J Neurosci* 2009; 29: 3908–3919. doi: 10.1523/jneurosci.5672-08.2009.
15. Otagiri T, Sugai K, Kijima K, et al. Periaxin mutation in Japanese patients with Charcot-Marie-Tooth disease. *J Hum Genet* 2006; 51: 625–628. doi: 10.1007/s10038-006-0408-3.
16. Marchesi C, Milani M, Morbin M, et al. Four novel cases of periaxin-related neuropathy and review of the literature. *Neurology* 2010; 75: 1830–1838. doi: 10.1212/WNL.0b013e3181fd6314.
17. Takashima H, Boerkoel CF, De Jonghe P, et al. Periaxin mutations cause a broad spectrum of demyelinating neuropathies. *Ann Neurol* 2002; 51: 709–715. doi: 10.1002/ana.10213.
18. Tokunaga S, Hashiguchi A, Yoshimura A, et al. Late-onset Charcot-Marie-Tooth disease 4F caused by periaxin gene mutation. *Neurogenetics* 2012; 13: 359–365. doi: 10.1007/s10048-012-0338-5.
19. Kijima K, Numakura C, Shirahata E, et al. Periaxin mutation causes early-onset but slow-progressive Charcot-Marie-Tooth disease. *J Hum Genet* 2004; 49: 376–379. doi: 10.1007/s10038-004-0162-3.
20. Parman Y, Battaloglu E, Baris I, et al. Clinicopathological and genetic study of early-onset demyelinating neuropathy. *Brain* 2004; 127(Pt 11): 2540–2550. doi: 10.1093/brain/awh275.
21. Choi YJ, Hyun YS, Nam SH, et al. Novel compound heterozygous nonsense PRX mutations in a Korean Dejerine-Sottas neuropathy family. *J Clin Neurol* 2015; 11: 92–96. doi: 10.3988/jcn.2015.11.1.92.
22. Boerkoel CF, Takashima H, Stankiewicz P, et al. Periaxin mutations cause recessive Dejerine-Sottas neuropathy. *Am J Hum Genet* 2001; 68: 325–333. doi: 10.1086/318208.
23. Auer-Grumbach M, Fischer C, Papic L, et al. Two novel mutations in the GDAP1 and PRX genes in early onset Charcot-Marie-Tooth syndrome. *Neuropediatrics* 2008; 39: 33–38. doi: 10.1055/s-2008-1077085.
24. Kabzinska D, Drac H, Sherman DL, et al. Charcot-Marie-Tooth type 4F disease caused by S399fsx410 mutation in the PRX gene. *Neurology* 2006; 66: 745–747. doi: 10.1212/01.wnl.0000201269.46071.35.
25. Barankova L, Siskova D, Huhne K, et al. A 71-nucleotide deletion in the periaxin gene in a Romani patient with early-onset slowly progressive demyelinating CMT. *Eur J Neurol* 2008; 15: 548–551. doi: 10.1111/j.1468-1331.2008.02104.x.
26. Wang MM, Zhang X, Lee SJ, et al. Expression of periaxin (PRX) specifically in the human cerebrovascular system: PDZ domain-mediated strengthening of endothelial barrier function. *Sci Rep* 2018; 8: 10042. doi:10.1038/s41598-018-28190-7.