

Endoscopic repair of hip abductor tears: outcomes with two-year follow-up

J. W. Thomas Byrd* and Kay S. Jones

Nashville Sports Medicine Foundation, 2011 Church Street, Suite 100, Nashville, TN 37203, USA

*Correspondence to: J. W. Thomas Byrd. E-mail: info@nsmfoundation.org

Submitted 27 July 2016; Revised 4 October 2016; revised version accepted 18 November 2016

ABSTRACT

Abductor lesions are increasingly recognized as a source of recalcitrant laterally based hip pain and dysfunction. There is a growing body of evidence that many of these may be amenable to endoscopic repair. To report the demographic data and outcomes of endoscopic hip abductor repair. Twelve patients underwent endoscopic abductor repair with 2-year follow-up. These patients were prospectively assessed with modified Harris hip and iHOT scores. The indications for surgery were clinical and MRI findings of symptomatic abductor tears that had failed conservative treatment. All patients underwent concomitant or prior arthroscopy of the joint. Repair was performed with suture anchors using an iliotibial band-sparing endoscopic technique; followed by a 4-month structured rehabilitation protocol. Follow-up was obtained on all patients at 24 months. The average age was 56 years (range 39–77 years). These were all females. All demonstrated improved modified Harris hip scores, averaging 43 points (preop 42; postop 85). Eleven of 12 (92%) demonstrated improved iHOT scores, averaging 52 points (preop 21; postop 73). Ten patients had accompanying intra-articular pathology including 10 labral tears, 7 chondral lesions, 6 synovitis and 1 pincer impingement. There were no complications, and none underwent further surgery. Abductor tears of the hip can be clinically relevant and respond well to endoscopic repair. This tends to be a disorder of older females who present with severe disability, reflected by low preoperative modified Harris hip scores, and demonstrate significant, although incomplete, improvement.

INTRODUCTION

Historically, recalcitrant lateral-sided hip pain was attributed to chronic trochanteric bursitis [1]. However, abductor tendinopathy has been recognized as a more common source of lateral hip pain that fails to respond to conservative treatment [2]. The term ‘greater trochanteric pain syndrome’ was coined representing a less specific but more accurate term for the constellation of disorders that can present within the trochanteric region [3].

Although abductor lesions are a common cause of greater trochanteric pain syndrome, imaging evidence of abductor pathology may be an incidental normal consequence of the aging process identified by MRI [4]. Thus, the history and physical examination are essential to establishing the clinical relevance of abductor damage. Ultrasound-guided injections of the abductors may have therapeutic value and are especially helpful in establishing that the tendon damage is the principal pain generator [5, 6].

There is a modest body of scientific evidence to support that appropriately selected abductor lesions may benefit from endoscopic repair [7–9].

The purpose of this study is to report the demographic data and outcomes of endoscopic abductor repair. It is hypothesized that, with proper patient selection, these cases may benefit from endoscopic intervention.

METHODS

All patients undergoing abductor repair were prospectively assessed using the modified Harris hip score and iHOT-12 [10, 11]. This study consists of the first 12 consecutive patients who had achieved 2-year follow-up. All repairs were performed endoscopically, and no cases were excluded from this study. The data obtained and presented in this manuscript has been granted exemption status by the institutional review board.

The indication for abductor repair was imaging evidence of clinically relevant abductor tearing that had failed conservative treatment including activity modification, supervised physical therapy, oral anti-inflammatory medication and judicious use of corticosteroid injections. All procedures were performed by the senior author using a previously described systematic standard supine method [12–15]. All patients underwent concomitant or prior arthroscopy of the central compartment, and then abductor repair using an iliotibial band-sparing approach to the peritrochanteric space (Fig. 1).

Longitudinal tears were repaired with longitudinally oriented suture anchors (Fig. 2) while complete avulsions were repaired with double-row fixation consisting of transversely oriented proximal row suture anchors and distal row knotless devices (Fig. 3).

Supervised postoperative physical therapy was begun on the day following surgery [16]. Crutches were used for 8 weeks, minimizing tensile forces at the repair site. Routine precautions were continued until 4 months, at which point the repair was felt to be fully healed.

Statistical analysis comparing the preoperative and postoperative scores was performed using a paired samples *t* test.

RESULTS

Follow-up was obtained on all patients at 24 months. They were all females with an average age of 56 years (range

39–77 years). All demonstrated improved modified Harris hip scores with an average of 43 points (preop 42; postop 85). The iHOT-12 score was improved in 11 of 12 (92%) with an average improvement of 52 points (preop 21; postop 73). The improvement was statistically significant for both scoring systems ($P < 0.001$). Six patients had Tönnis 0, and 6 Tönnis 1 radiographic changes. Ten patients had accompanying intra-articular pathology including 10 labral tears, 7 chondral lesions (3 outer bridge grade I, 2 grade III, 2 grade IV), 6 synovitis and 1 pincer impingement. Among the 10 patients with intra-articular pathology, 9 underwent labral debridement and one underwent acetabuloplasty with labral refixation. Additionally, 4 chondroplasties and one microfracture were performed. There were no complications, and no patient underwent further surgery.

DISCUSSION

This study reflects that, for properly selected patients, endoscopic abductor repair can result in significantly improved outcomes scores. This is consistent with previously reported studies. Voos *et al.*, noted complete pain relief and full strength among 10 patients with an average 2-year follow-up [7]. McCormick *et al.*, reported 60% good and excellent results among 10 patients with minimum 1-year follow-up, but 90% were satisfied with the procedure [8]. Domb *et al.* noted that 93% (14 patients) were improved among 15 patients with minimum 2-year follow-up [9].

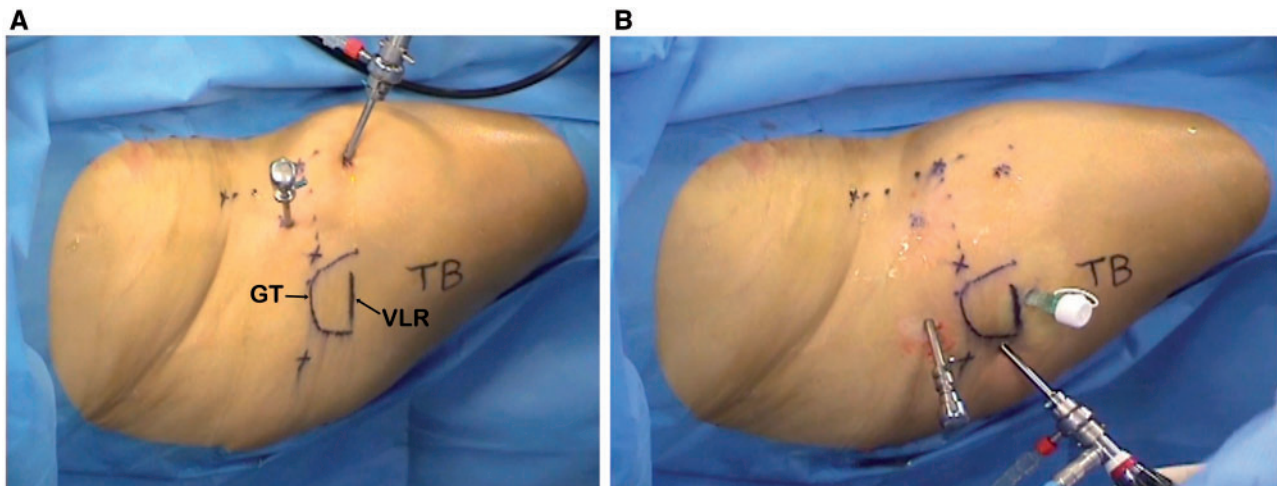


Fig. 1. Viewing a right hip: (A) Initially two anteriorly based portals are established to develop the peritrochanteric space lateral to the greater trochanter (GT) and deep to the iliotibial band. Surface markings for the GT and vastus lateralis ridge (VLR) are noted as well as routine markings that would be used for arthroscopy of the central compartment. (B) Once the space and anatomy has been fully identified, portals for gluteal repair are then established. Three laterally based portals have been positioned for gluteal repair. A viewing portal with a 30° arthroscope is just posterior to the vastus lateralis ridge. A working portal with an 8.5 mm disposable cannula is just distal to the ridge. Anchors are inserted from a proximal portal allowing placement perpendicular to the trochanteric cortex.

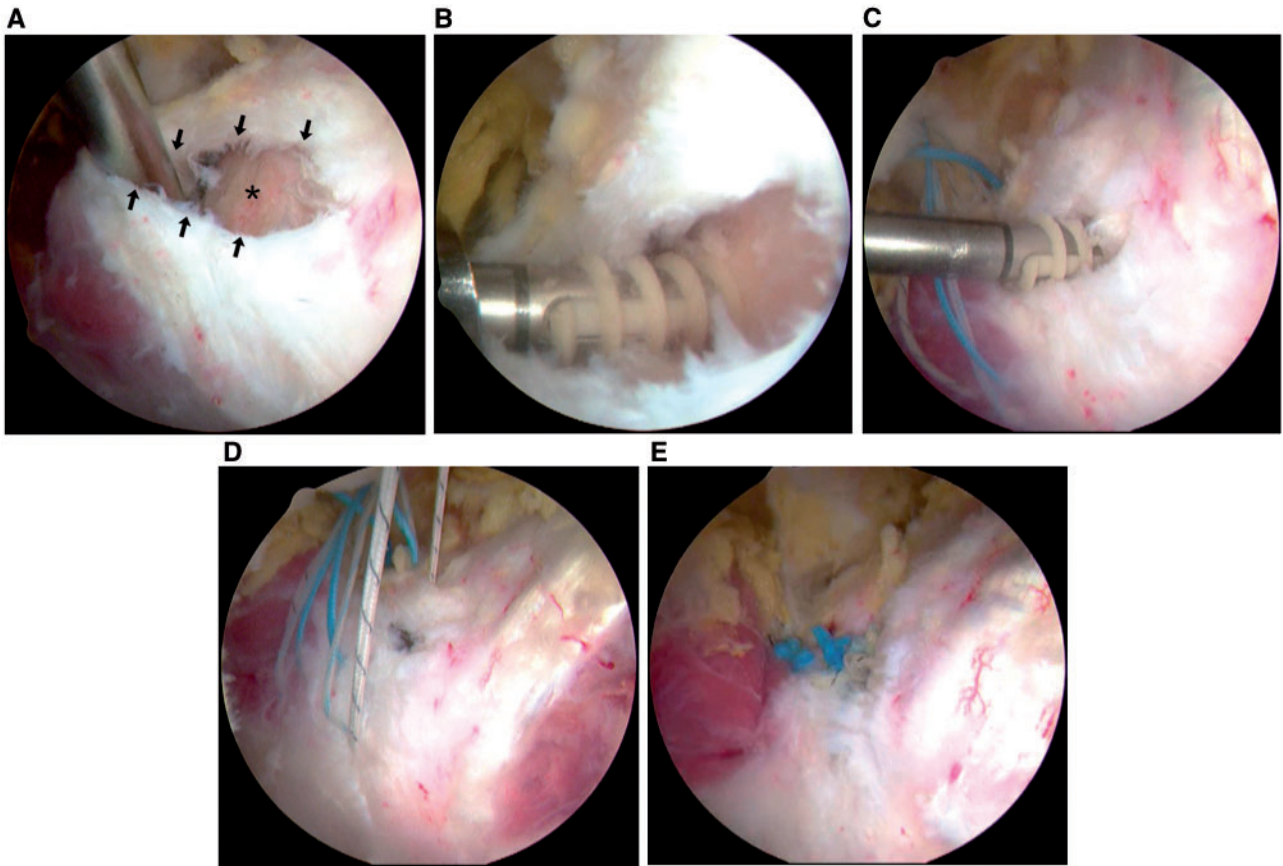


Fig. 2. Looking into the peritrochanteric space from the viewing portal of this right hip, (A) a vertically oriented tear of the gluteus medius (arrows) shows the underlying bony footprint (*). (B) A triple-loaded suture anchor is inserted at the proximal aspect of the repair site. (C) A more distal anchor is being seated. The three sutures from the proximal anchor are shown passed through the posterior and anterior leaves of the torn tendon. (D) All suture pairs have been passed and are ready to be tied, restoring the tendinous insertion site of the gluteus medius. (E) The final repair construct is inspected with secure approximation of the tendon back to its bony footprint.

Several contrasts were noted compared with arthroscopic treatment of femoroacetabular impingement (FAI), which is a much more common disorder. Compared with data published by these authors on arthroscopic correction of FAI, these patients with abductor repair average 56 years of age (34 for FAI), are 100% female (67% male for FAI), with baseline preoperative modified Harris hip scores averaging 42 points (65 points for FAI), and demonstrating an average improvement of 43 points (21.5 points for FAI) [17]. Thus, compared with FAI, these patients are significantly older (22 years) and female dominated. They tend to be severely disabled as reflected by low preoperative modified Harris hip scores, 23 points worse than FAI. Results of surgery can be strikingly good, double that of FAI, although still not normal with an average score of 85.

The majority of these patients had concomitant intra-articular pathology, but in no case did this lead to a poor

result for abductor repair. Since these patients tend to be older and often have joint disease, it is prudent to assess the joint to make sure that abductor repair would not be contraindicated due to advanced occult disease. These authors would not advocate that the central compartment of the hip must be assessed in every case, but would propose that there should be a good reason not to assess it. As a parallel in the shoulder, one would not routinely perform a rotator cuff repair without first assessing the glenohumeral joint.

This is a modest study with no major limitations other than those inherent in a Level 4 case series. Patients with abductor lesions amenable to endoscopic intervention tend to be older age females. Abductor lesions of the hip can be associated with severe disability as reflected by low baseline scores and, with proper patient selection, can respond remarkably well to endoscopic repair as reflected by significant improvement in outcomes scores.

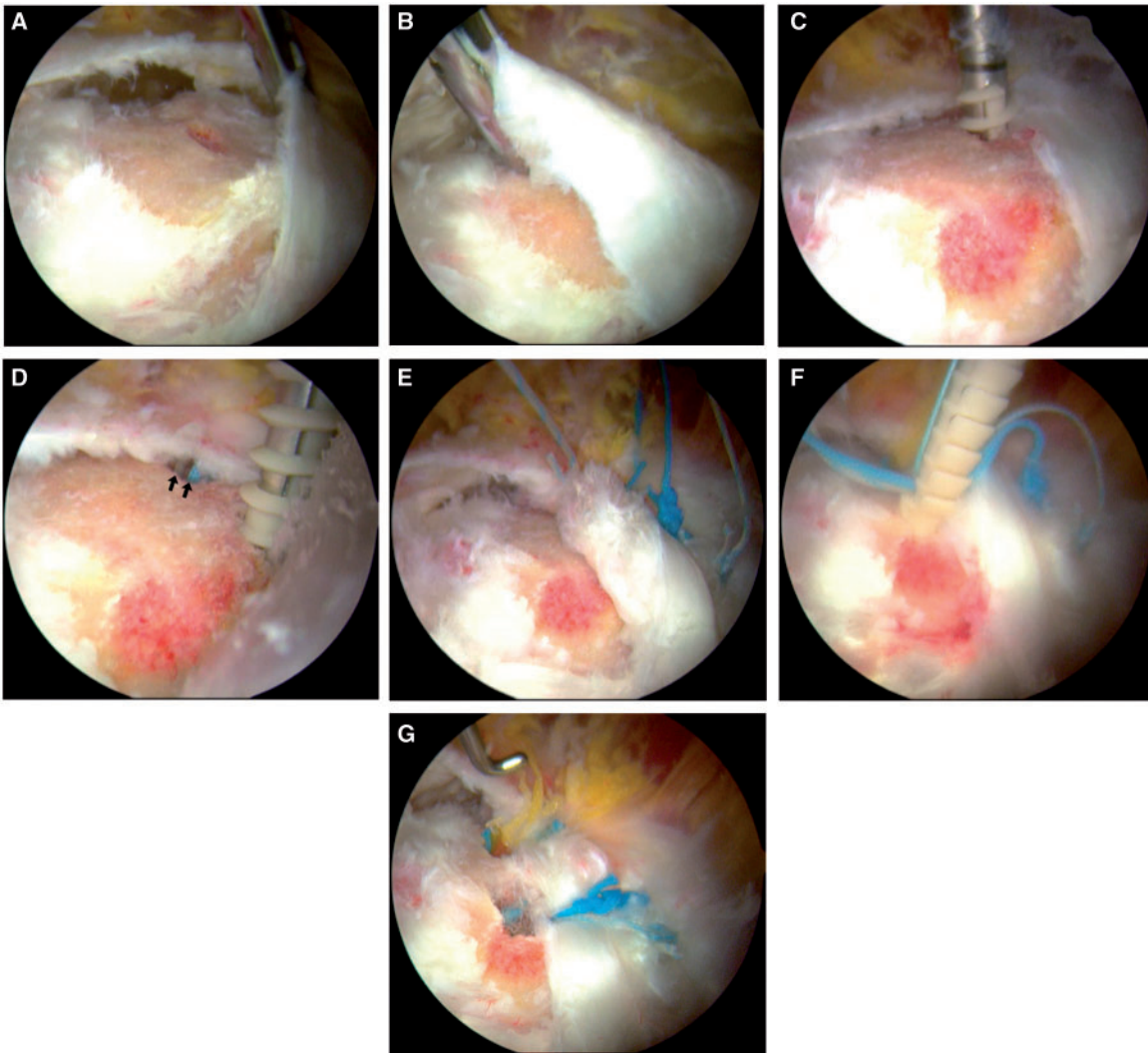


Fig. 3. Looking into the peritrochanteric space from the viewing portal of this left hip, a complete tear of the gluteus medius from the lateral facet is identified. (A) A grasper retracts the tendon proximally exposing the bony footprint. (B) The tendon is mobilized distally over the insertion site. (C) The anterior of two double-loaded suture anchors is being inserted in the proximal portion of the bony footprint. (D) A second, more posterior, anchor is being inserted. The colored sutures of the anterior anchor are seen emerging from the anchor hole (arrows); these have already been passed in a mattress fashion through the proximal tendon. (E) The four sutures from the two double-loaded anchors have been tied, leaving one suture limb from each knot to be incorporated into the distal fixation. (F) A distal knotless anchor device is driven into place, incorporating two suture limbs from the proximal knots. (G) The final repair construct is inspected with secure double row fixation.

FUNDING

This research was performed at Nashville Sports Medicine Foundation. During the study period, Nashville Sports Medicine Foundation received research support from Smith & Nephew.

CONFLICT OF INTEREST STATEMENT

J. W. Thomas Byrd is a consultant for Smith & Nephew; he is a non-paid consultant and has stock in A3 Surgical.

REFERENCES

1. Schapira D, Nahir M, Scharf Y. Trochanteric bursitis: a common clinical problem. *Arch Phys Med Rehabil* 1986; **67**:815–7.
2. Kingzett-Taylor A, Tirman PF, Feller J *et al.* Tendinosis and tears of gluteus medius and minimus muscles as a cause of hip pain: MR imaging findings. *AJR Am J Roentgenol* 1999; **173**:1123–6.
3. Karpinski MR, Piggott H. Greater trochanteric pain syndrome. A report of 15 cases. *J Bone Joint Surg Br* 1985; **67**:762–3.
4. Haliloglu N, Inceoglu D, Sahin G. Assessment of peritrochanteric high T2 signal depending on the age and gender of the patients. *Eur J Radiol* 2010; **75**:64–6.

5. Labrosse JM, Cardinal E, Leduc BE *et al.* Effectiveness of ultrasound guided corticosteroid injection for treatment of gluteus medius tendinopathy. *AJR* 2010; **194**:202–6.
6. Jones KS, Potts EA, Byrd JWT. Perioperative care. In Byrd JWT (ed) *Operative Hip Arthroscopy*, 3rd edn. New York: Springer, 2013, 441–54.
7. Voos JE, Shindle MK, Pruett A *et al.* Endoscopic repair of gluteus medius tendon tears of the hip. *Am J Sports Med* 2009; **37**:743–7.
8. McCormick F, Alpaugh K, Nwachukwu BU *et al.* Endoscopic repair of full-thickness abductor tendon tears: surgical technique and outcome at minimum of 1-year follow-up. *Arthroscopy* 2013; **29**:1941–7.
9. Domb BG, Botser I, Giordano BD. Outcomes of endoscopic gluteus medius repair with minimum 2-year follow-up. *Am J Sports Med* 2013 May; **41**:988–97. Epub 2013 Mar 22.
10. Byrd JWT, Jones KS. Prospective analysis of hip arthroscopy with 10-year follow-up. *Clin Orthop Relat Res* 2010; **468**:741–6. Epub 2009 Apr 21.
11. Griffin DR, Parsons N, Mohtadi NG *et al.* Multicenter arthroscopy of the hip outcomes research network: a short version of the International Hip Outcome Tool (iHOT-12) for use in routine clinical practice. *Arthroscopy* 2012; **28**:611–6.
12. Byrd JWT. Hip arthroscopy utilizing the supine position. *Arthroscopy* 1994; **10**:275–80.
13. Byrd JWT. Routine arthroscopy and access: central and peripheral compartments, iliopsoas bursa, peritrochanteric, and subgluteal spaces. In: Byrd JWT (ed) *Operative Hip Arthroscopy*, 3rd edn. New York: Springer, 2012, 131–60.
14. Byrd JWT. Peritrochanteric access and gluteus medius repair. *Arthrosc Tech* 2013. <http://dx.doi.org/10.1016/j.eats.2013.02.015>.
15. Byrd JWT. Gluteus medius repair with double row fixation. *Arthrosc Tech* 2013. <http://dx.doi.org/10.1016/j.eats.2013.02.014>.
16. Coplen EM, Voight ML. Rehabilitation of the hip. In Byrd JWT (ed) *Operative Hip Arthroscopy*, 3rd edn. New York: Springer, 2013, 411–40.
17. Byrd JW, Jones KS. Arthroscopic management of femoroacetabular impingement: minimum 2-year follow-up. *Arthroscopy* 2011; **27**:1379–88. doi:10.1016/j.arthro.2011.05.018. Epub 2011 Aug 20.