


# Gastric adenocarcinoma of the fundic gland: A review of clinicopathological characteristics, treatment and prognosis

Rare Tumors  
Volume 13: 1–7  
© The Author(s) 2021  
Article reuse guidelines:  
[sagepub.com/journals-permissions](https://sagepub.com/journals-permissions)  
DOI: 10.1177/20363613211060171  
[journals.sagepub.com/home/rtu](https://journals.sagepub.com/home/rtu)  


Xiang-yu Meng<sup>2,\*</sup>, Guang Yang<sup>1,3,\*</sup> , Cheng-ji Dong<sup>4</sup> and Ru-yi Zheng<sup>5</sup>

## Abstract

Gastric adenocarcinoma of the fundic gland is a rare, well-differentiated gastric cancer entity, and very few patients transition to poorly differentiated tubular adenocarcinoma during progression. Gastric adenocarcinoma of the fundic gland originates from the mucosa of the gastric fundic gland, usually without chronic gastritis or intestinal metaplasia. Histologically, the tumor cells are closely arranged to form anastomosing tubular glands, and more than 95% of tumor cells differentiate towards chief cells. Most gastric adenocarcinoma of the fundic gland cases are characterized by submucosal involvement, but the tumor volume is usually small, with lymphatic and vascular invasion rarely observed. Therefore, endoscopic submucosal dissection can be an ideal treatment, leading to a favorable prognosis, and recurrence and metastasis of the disease are uncommon.

## Keywords

Gastric adenocarcinoma of the fundic gland, chief cells, histopathology, treatment, prognosis

Date received: 13 October 2021; accepted: 28 October 2021

## Introduction

Morphologically, gastric cancer features a wide range of morphological heterogeneity, resulting in a variety of different histological subtypes.<sup>1</sup> According to the Lauren classification, gastric cancer is classified into intestinal and diffuse types<sup>2</sup>; according to the Nakamura classification, gastric cancer is grouped into differentiated and undifferentiated types.<sup>3</sup> Based on molecular and genetic profiling, gastric cancer is divided into four genetic subtypes: EpsteinBarr virus (EBV)infected tumors, microsatellite instability (MSI) tumors, genomically stable tumors, and chromosomally unstable tumors.<sup>4</sup> With the development of immunohistochemistry (IHC), it has been confirmed that intestinal gastric cancer contains a gastric phenotype. The gastric phenotypes include foveolar type, pyloric gland type, and fundic gland type.

In 2007, gastric adenocarcinoma of the fundic gland (GA-FG) was first reported as a novel tumor entity by Tsukamoto et al.<sup>5</sup> According to tumor cell differentiation,

GA-FG can be divided into three subtypes: chief cell-predominant type, parietal cell-predominant type, and mixed type. The GA-FG chief cell-predominant (GA-FG-CCP) type accounts for approximately 99% of all GA-FG

<sup>1</sup>Department of Pathology, Dentistry and Pharmaceutical Sciences, Okayama University Graduate School of Medicine, Okayama, Japan

<sup>2</sup>Department of Biochemistry and Molecular Biology, Mudanjiang Medical University, Mudanjiang, China

<sup>3</sup>Department of Pathology, Mudanjiang Medical University, Mudanjiang, China

<sup>4</sup>Department of Hepatobiliary and Pancreas Surgery, The First Hospital of Jilin University, Changchun, China

<sup>5</sup>Medical Imaging Center, The Mine Hospital of Xu Zhou, Xuzhou, China

\*Guang Yang and Xiang-yu Meng contributed equally to this work.

## Corresponding author:

Guang Yang, Department of Pathology, Okayama University Graduate School of Medicine, Dentistry and Pharmaceutical Sciences, 2 Chome-5-1 Shikatacho, Kita Ward, Okayama 700-8558, Japan.  
Email: [178771425@qq.com](mailto:178771425@qq.com)



Creative Commons Non Commercial CC BY-NC: This article is distributed under the terms of the Creative Commons Attribution-NonCommercial 4.0 License (<https://creativecommons.org/licenses/by-nc/4.0/>) which permits non-commercial use, reproduction and distribution of the work without further permission provided the original work is attributed as specified on the SAGE and Open Access pages (<https://us.sagepub.com/en-us/nam/open-access-at-sage>).

cases.<sup>6</sup> With the increasing number of reported GA-FG cases, the purpose of this review is to summarize the clinicopathological characteristics, endoscopic appearance, pathogenesis, molecular phenotype, and prognosis of GA-FG to increase understanding of clinicians and pathologists regarding this type of disease.

### Clinicopathological characteristics

GA-FG is a rare subtype of gastric cancer with well-differentiated tissue and clear boundaries, accounting for approximately 1% of early gastric adenocarcinomas.<sup>7</sup> Most lesions are located in the middle and upper third of the stomach.<sup>8</sup> According to previous studies, the ratio of male to female patients with GA-FG is approximately 1.4<sup>9</sup>; however, based on our analysis, the ratio is approximately 2.2. The GA-FG tumor volume is usually small, approximately 1 cm.<sup>10</sup> Most GA-FG patients do not have intestinal metaplasia, atrophic glands, or *Helicobacter pylori* (*H. pylori*) infection.<sup>8,11</sup> However, in our study, according to the available data, 19 of 67 GA-FG patients had *H. pylori* positive infection, and 11 of 48 GA-FG negative patients experienced *H. pylori* eradication therapy. Therefore, we think that the *H. pylori* infection should be given more attention as a factor in GA-FG pathogenesis. GA-FG is a well-differentiated and low malignant potential tumor. Lymphatic and vascular invasion rarely occurs,<sup>8,11,12</sup> according to the Japanese classification of gastric carcinoma. Our current analysis shows that only 10 (6.3%) of 159 GA-FG cases with available relevant data had lymphatic invasion, and only 8 (5.0%) of 160 GA-FG cases had vascular invasion, which is similar to previous studies. Yasuhiro Okunura<sup>13</sup> reported a rare case of GA-FG. This was the first report of GA-FG progressing to aggressive cancer with lymph node metastasis. More detailed clinical features are presented in Table 1.

### Endoscopic imaging features

Endoscopically, most GA-FG lesions are located in the middle/upper third of the stomach. According to a previous review, the proportion of GA-FG lesions located in the middle/upper third of the stomach is up to 98% among the total GA-FG cases.<sup>6</sup> In our current analysis, the proportion was approximately 97.4%, which is similar to the previous results. The number of cases located in the upper, middle, and lower third of the stomach was 156, 34, and 3, respectively. Macroscopically, according to the available data, 3 tumor lesions showed a protruded type (T0-I); 1 tumor lesion presented an ulcerative type (T2); and the number of cases of superficial and elevated (0-IIa), superficial and flat (0-IIb), superficial and depressed (0-IIc), and mixed type was 94, 14, 39, and 20, respectively. Narrow band imaging can enhance visualization of mucosal vessels and show

irregular patterns, which indicate heterogeneity of microvessels in GA-FG.<sup>7,14</sup> The use of narrow band imaging and endoscopic ultrasound can improve the chance of complete resection through endoscopic mucosal resection (EMR) technology.

### Histopathological features

The histopathological findings for GA-FG are shown in Figure 1. The tumor surface area is typically still covered with normal foveolar epithelium. Chronic inflammation, atrophic glands, and intestinal metaplasia are rarely observed in the surrounding mucosal background. Tumor lesions are composed of closely arranged and anastomosing glands, forming an “endless gland.” Tumor cells are similar to fundic gland cells, appearing as well-differentiated, mildly heterogeneous columnar cells with moderately enlarged nuclei. In approximately 99% of cases, tumor cells differentiate into chief cells.<sup>6</sup> In our study, according to the relevant data available, the number of GA-FG-CCP cases was 163, accounting for 96%. In addition, 2 cases appeared to exhibit the foveolar epithelium type, 1 case showed mixed type differentiation, and 3 cases differentiated towards the mucous neck cell type. GA-FG originates from the deep layer of the lamina propria. Although most tumor lesions show submucosal invasion, lymphatic and vascular invasion is very rare.<sup>7,8,15</sup> According to our analysis, among 163 cases of GA-FG, 119 cases had submucosal infiltration (73%), and only two cases had subserosal infiltration. Although tumor submucosal involvement has been identified in most reports, thin wisps of muscularis mucosae with the absence of desmoplasia were identified throughout the lesions. Therefore, Singhi et al.<sup>16,17</sup> suggested that this change represents prolapse-type growth to the submucosa rather than the more typical submucosal infiltration seen with malignant tumors. Some researchers believe that it is excessive and exaggerated to name this disease “GA-FG,” and this type of disease should be considered benign. They prefer to use “oxyntic gland polyps/adenomas” rather than “GA-FG.”<sup>16</sup> Although Yasuhiro Okumura reported a rare case of GA-FG that gradually transitioned into aggressive tubular adenocarcinoma with poorly differentiated components in the muscularis propria and subserosal layers, there were only two cases of subserosal infiltration in our analysis.<sup>13,18</sup>

IHC was used to evaluate lineage differentiation in GA-FG. The main relevant cell differentiation markers are shown in Table 2. Mucin phenotypes of GA-FG were identified by detecting the expression of gastric phenotype markers, such as MUC5AC and MUC6, and intestinal phenotype markers, such as MUC2 and CD10.<sup>19</sup> Pepsinogen-1 is the most specific marker of chief cell differentiation, and its immunohistochemical analysis will be necessary for diagnosis of GA-FG-CCP. Previously,

**Table 1.** Characteristics of reported gastric adenocarcinoma of the fundic gland.

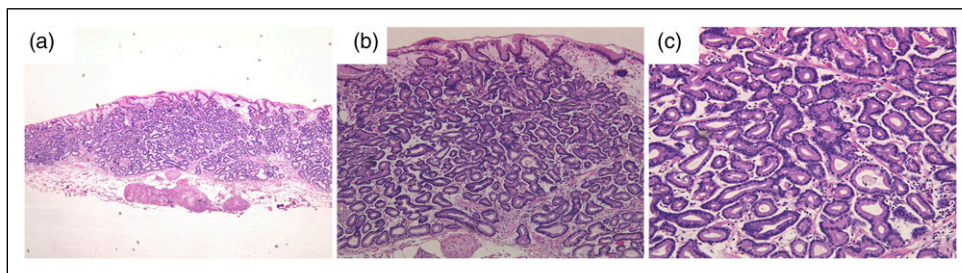
Author (Year)	No. of cases	Age or age range	Gender distribution (M/F)	Location of lesion (U/M/L)	<i>H. pylori</i> infection (+/-/post eradication)	Size of tumor or range (mm)	Macroscopic type (0-IIa/IIb/IIc/mixed)	Invasion depth (M/SM1/SM2/SS)	Lymphatic invasion (Present/Absent)	Venous invasion (Present/Absent)	Cell type
Fan <sup>21</sup>	1	60	1/0	0/1/0	1/0/0	5	—	0/1/0/0	—	—	Chief cell
Li <sup>8</sup>	8	48–80	3/5	7/1/0	0/8/0	4–12	6/0/2/0	2/5/1/0	-	-	Chief cell
Chen <sup>11</sup>	1	55	0/1	2/0/0	0/0/1	6 and 4	1/1/0/0	2/0/0/0	-	-	Chief cell
Takeshi <sup>12</sup>	1	73	1/0	1/0/0	1/0/0	25	1/0/0/0	1/0/0/0	-	-	Foveolar epithelium
Yu <sup>27</sup>	1	77	0/1	0/0/1	0/0/1	6	1/0/0/0	0/1/0	-	-	Chief cell
Fumiaki <sup>15</sup>	8	51–83	4/4	6/2/0	0/4/4	4–14	6/2/0/0	5/3/0/0	-	-	Chief cell
Keita <sup>28</sup>	1	76	0/1	—	1/0/0	28	0/0/1/0	0/1/0/0	-	-	Chief cell
Atsushi <sup>29</sup>	1	70	1/0	0/1/0	—	23	—	0/1/0	-	—	Foveolar epithelium
Yasuhir <sup>13</sup>	1	55	1/0	1/0/0	—	47	T2	0/0/0/1	+	+	Chief cell
Hitoshi <sup>30</sup>	1	78	1/0	—	0/0/1	4 and 7	T0-I	1/1/0/0	-	-	Chief cell
Shigeo <sup>31</sup>	1	58	1/0	1/0/0	0/0/1	7	1/0/0/0	0/1/0/0	-	-	Chief cell
Keitaro <sup>32</sup>	1	87	1/0	0/0/1	1/0/0	3	T0-I	1/0/0/0	-	-	Mixed
Takashi <sup>26</sup>	26	49–82	19/7	20/6/0	—	3–39	17/0/5/4	11/15/0	2/24	1/25	Chief cell
Yoriaki <sup>33</sup>	1	50	1/0	—	0/1/0	5	1/0/0/0	0/1/0	—	—	Chief cell
Gen <sup>34</sup>	4	42–62	2/2	3/1/0	2/2/0	2–5	2/2/0/0	2/2/0	-	-	Chief cell
Keisuke <sup>35</sup>	1	62	1/0	0/1/0	0/1/0	—	0/0/1/0	0/1/0	-	+	Chief cell
Eleanor <sup>36</sup>	1	49	1/0	1/0/0	0/1/0	11	—	0/1/0	-	+	Chief cell
Takashi <sup>25</sup>	20	44–85	16/4	14/6/0	13/5/2	—	12/5/3/0	—	—	—	Chief cell
Sato <sup>37</sup>	1	77	0/1	1/0/0	0/1/0	10	1/0/0/0	0/1/0/0	-	-	Chief cell
Hee <sup>3</sup>	1	69	1/0	1/0/0	—	25	—	0/1/0	-	-	Chief cell
Soichi <sup>38</sup>	1	66	1/0	1/0/0	0/1/0	—	0/1/0/0	1/0/0/0	-	-	Chief cell
Masaki <sup>7</sup>	5	67–78	3/2	5/0/0	0/5/0	5–13	4/1/0/0	0/2/3/0	1/4	-	Chief cell
Lee <sup>39</sup>	11	55–82	8/3	8/3/0	—	3–18	T0-I:1; 5/1/4/0	—	-	-	Chief cell
Kato <sup>40</sup>	1	80	1/0	1/0/0	0/1/0	30	1/0/0/0	0/1/0/0	-	-	Chief cell
Ueyama <sup>41</sup>	10	55–78	6/4	6/4/0	*1/6/1	3–31	*1/1/3/0	5/4/1/0	1/9	-	Chief cell
Nomura <sup>10</sup>	26	49–79	22/4	23/3/0	—	3–85	15/0/5/6	0/20/6/0	3/23	2/24	—
Ueo <sup>18</sup>	1	62	1/0	0/1/0	0/1/0	44	—	0/0/0/1	+	+	Chief cell
Ryoji <sup>42</sup>	3	56–78	1/2	3/0/0	—	3–8	—	1/1/1/0	—	—	Chief cell
Hidaka <sup>17</sup>	31	41–79	21/10	28/3/0	—	3–85	14/0/10/7	0/31/0	1/30	1/30	Chief cell
Su park <sup>43</sup>	3	47–76	3/0	1/1/1	—	12–36	0/0/0/3	1/1/1/0	-	-	Chief cell
Singhi <sup>16</sup>	10	44–79	4/6	10/0/0	—	20–80	—	10/0/0/0	-	-	Chief cell: 7; Mucous neck cell: 3
Fukatsu <sup>44</sup>	1	55	1/0	1/0/0	—	5	—	0/1/0/0	-	-	Chief cell
Terada <sup>22</sup>	1	78	1/0	1/0/0	—	15	1/0/0/0	—	—	—	Chief cell

(continued)

**Table 1.** (continued)

Author (Year)	No. of cases	Age or age range	Gender distribution (M/F)	Location of lesion (U/M/L)	<i>H. pylori</i> infection (+/-/post eradication)	Size of tumor or range (mm)	Macroscopic type (0-Ila/IIb/IIc/mixed)	Invasion depth (M/SM1/SM2/SS)	Lymphatic invasion (Present/Absent)	Venous invasion (Present/Absent)	Cell type
Ueyama <sup>20</sup>	10	42–79	6/4	10/0/0	—	4–20	5/0/5/0	1/6/3/0	-	-	Chief cell
Total	195	41–87	134/61	156/34/3	19/37/11	2–85	T0-I: 3; T2: 1; 94/14/39/20	44/11/9/2	10/159	8/160	Chief cell: 163; Foveolar epithelium: 2; Mixed: 1; Mucous neck cell: 3

—: Relevant data is not available; M: male; F: female; U: upper third of stomach; M: middle third of stomach; L: lower third of stomach; *H. pylori*: *Helicobacter pylori*; Type 0-I: protruded type; 0-Ila: superficial and elevated type; 0-IIb: superficial and flat type; 0-IIc: superficial and depressed type; T2: ulcerative; M: tumor confined to the mucosa; SM1: tumor confined to the submucosa, but depth is within 0.5 mm of the muscularis mucosae; SM2: tumor invasion is 0.5 mm or more deep into the muscularis mucosae; SS: tumor invades the subserosa; +: positive; -: negative; \*: partial data is unknown.



**Figure 1.** Histopathological findings of representative GA-FG case. (A) In low-power view ( $\times 40$ ), the tumor originated from the deep layer of the lamina propria and invaded submucosal layer. The surface was covered with non-atypical foveolar epithelium; (B) and (C): In high-power view ( $\times 100$  and  $200$ ), the tumor comprised well-differentiated columnar cells mimicking the fundic gland cells with mild nuclear atypia.

Ueyama et al.<sup>20</sup> reported that in the tumor progression process, cell differentiation can change from the fundic gland type to the foveolar type in advanced GA-FG patients. GA-FG differentiation in several directions has more malignant potential than GA-FG differentiation into chief cells.<sup>12</sup>

Regarding expression of p53 protein and the Ki67 labeling index, none of the reported cases showed an over-expression of p53, and the Ki67 labeling index was very low (less than 5%).<sup>21,22</sup>

### Pathogenesis and molecular analysis

Although many studies have been performed to elucidate the pathogenesis of GA-FG, it is still unclear. *H. pylori* is a gram-negative, flagellated, acid-resistant bacterium that infects more than 50% of the world's population.<sup>23</sup> In etiology, *H. pylori* infection is associated with nonatrophic or atrophic gastritis, intestinal metaplasia,<sup>15,24</sup> and peptic

**Table 2.** Cell differentiation markers.

Marker	Cell type targeted
MUC2	Goblet cell
MUC5AC	Gastric foveolar epithelium
MUC6	Mucous neck cell and pyloric gland
CD10	Brush border
Pepsinogen-I	Chief cell
H+/K+-ATPase	Parietal cell

ulcers and is an increased risk factor for developing gastric adenocarcinoma and mucosa-associated lymphoid tissue lymphoma.<sup>23</sup>

A recent study reported the effect of *H. pylori* infection in GA-FG. Compared with the *H. pylori*-negative group, a decreasing number of fundic glands and thinned foveolar epithelium covering tumor ducts were observed in the *H. pylori* eradication group.<sup>15</sup> Takashi Chiba et al.<sup>25</sup> reported 20

cases of GA-FG, of which 15 were *H. pylori* positive or experienced *H. pylori* eradication, but almost all lesions occurred in nonatrophic gastric mucosa. Therefore, the association between *H. pylori* infection and GA-FG still needs to be further studied.

Some GA-FG cases showed distended fundic glands mixed with foveolar cells, similar to fundic gland polyps. Therefore, some hypotheses have been raised regarding whether the occurrence of GA-FG is related to the use of proton pump inhibitors. However, the associated research is limited, and the relationship between the occurrence of GA-FG and the use of proton pump inhibitors is not clear.

There are few studies on the molecular changes associated with GA-FG. Activation of the Wnt/ $\beta$ -catenin signaling pathway is considered to be related to GA-FG occurrence, but the detailed mechanism underlying the activation of this signaling pathway has not been elucidated. To elucidate the potential role of gene methylation in relation to the Wnt/ $\beta$ -catenin signaling pathway, Takashi Murakami et al.<sup>26</sup> performed  $\beta$ -catenin immunostaining and methylation-specific PCR detection of related genes, including *SFRPs*, *APC*, *AXIN2*, and *MCC*, in GA-FG-CCP. They found that the nuclear  $\beta$ -catenin labeling index was higher in GA-FG-CCP. *SFRPs*, *APC*, and *AXIN2* are also more frequently methylated in GA-FG-CCP. A significant correlation was observed between nuclear  $\beta$ -catenin expression and *SFRP1* methylation. In conclusion, the activation of this signaling pathway mediated by gene methylation may be related to the occurrence and development of GA-FG-CCP. In 2014, Ryosuke Nomura et al.<sup>10</sup> detected the mutation status of *GNAS* and the Wnt/ $\beta$ -catenin signaling pathway related genes *CTNNB1/AXIN2/APC* in 26 cases of GA-FG. They found that nearly half of the cases harbored at least one mutation in *CTNNB1/AXIN2/APC*, leading to persistent activation of the Wnt/ $\beta$ -catenin signaling pathway. Among 26 cases of GA-FG, only 5 cases contained *GNAS* mutations (R201 C). *GNAS* mutation may occur in a small proportion of GA-FG as an alternative mechanism to activate the Wnt/ $\beta$ -catenin signaling pathway. Similarly, in 2013, Yasuhiro Hidaka et al.<sup>17</sup> detected the mutation status of the *CTNNB1/AXIN1/AXIN2/APC* genes. The results showed that 14 (51.9%) of 27 GA-FG-CCP type lesions contained at least one gene mutation in *CTNNB1/AXIN1/AXIN2/APC*. Among 27 cases of GA-FG, 17 cases presented low nuclear  $\beta$ -catenin expression, and 7 cases had high nuclear  $\beta$ -catenin expression. Therefore, as a unique nonaggressive tumor entity, GA-FG-CCP is characterized by accumulation of nuclear  $\beta$ -catenin and mutation of *CTNNB1* or *AXIN* genes, indicating activation of the Wnt/ $\beta$ -catenin pathway. However, in a recent paper on 8 cases of GA-FG,<sup>8</sup> tumor nuclear  $\beta$ -catenin expression was negative in all cases, which may be attributed to the limited number of cases.

## Treatment and prognosis

GA-FG is a well-differentiated, well-circumscribed, and low malignant potential gastric cancer entity that rarely exhibits lymphatic or vascular invasion. However, it is commonly observed in the submucosa. Endoscopic submucosal dissection (ESD) is considered the most effective regimen for restricted GA-FG. The present evidence shows that GA-FG has a favorable prognosis, and metastasis and recurrence rarely occur during follow-up. Li et al.<sup>8</sup> performed a follow-up of 8 cases of GA-FG from 5 to 33 months. None of the patients had recurrence or metastasis. According to these characteristics, GA-FG confined to the submucosa can be treated by ESD. However, extended gastrectomy is needed for GA-FG that has transitioned into a more malignant tumor, disease with suspected lymph node metastasis, or multiple gastric cancer.

## Conclusion

GA-FG is a well-differentiated, low malignant potential, gastric cancer entity originating from the gastric fundic gland. In the surrounding mucosal background, chronic gastritis, atrophic glands, and intestinal metaplasia cannot be observed. In more than 95% of GA-FG cases, the tumor cells differentiate towards chief cells. Tumor cells with mild atypia and enlarged nuclei are closely arranged to form anastomosing glands, the so-called “endless gland.” Tumor lesions are very prone to involve the submucosa, despite their low malignancy and invasiveness. This phenomenon may not be malignant invasion of the tumor but instead may be a prolapse-type growth pattern into the submucosa. Although abnormal activation of the Wnt/ $\beta$ -catenin signaling pathway is related to GA-FG, there are few studies on the molecular changes in GA-FG and its pathogenesis, and further studies on GA-FG pathogenesis are necessary.

## Author contributions

Guang Yang, Ru-yi Zheng, Xiang-yu Meng, and Cheng-ji Dong developed the main content of this manuscript. Guang Yang and Ru-yi Zheng were involved in writing the manuscript. Cheng-ji Dong and Xiang-yu Meng edited the language of revised manuscript. Guang Yang supervised the project and contributed to the revision of the final manuscript.

## Declaration of conflicting interests

The author(s) declared no potential conflicts of interest with respect to the research, authorship, and/or publication of this article.

## Funding

The author(s) received no financial support for the research, authorship, and/or publication of this article.

## Ethical approval

An approval of our Institutional Review Board or Ethics Committee was not needed to conduct this analysis.

## Informed consent

Not applicable.

## ORCID iD

Guang Yang  <https://orcid.org/0000-0001-5427-7054>

## References

- Smyth EC, Nilsson M, Grabsch HI, et al. Gastric cancer. *The Lancet* 2020; 396: 635–648. DOI: [10.1016/s0140-6736\(20\)31288-5](https://doi.org/10.1016/s0140-6736(20)31288-5).
- Wang X-X, Ding Y, Wang S-W, et al. Intratumoral and peritumoral radiomics analysis for preoperative Lauren classification in gastric cancer. *Cancer Imaging* 2020; 20: 83. DOI: [10.1186/s40644-020-00358-3](https://doi.org/10.1186/s40644-020-00358-3).
- Cha HJ, Kim K, Kim M, et al. Concurrent gastric adenocarcinoma of fundic gland type and carcinoma with lymphoid stroma: a rare case report. *Case Rep Gastroenterol* 2016; 10: 292–301. DOI: [10.1159/00044277](https://doi.org/10.1159/00044277).
- Cancer Genome Atlas Research Network. Comprehensive molecular characterization of gastric adenocarcinoma. *Nature* 2014; 513: 202–209. DOI: [10.1038/nature13480](https://doi.org/10.1038/nature13480).
- Tsukamoto T, Yokoi T, Maruta S, et al. Gastric adenocarcinoma with chief cell differentiation. *Pathol Int* 2007; 57: 517–522. DOI: [10.1111/j.1440-1827.2007.02134.x](https://doi.org/10.1111/j.1440-1827.2007.02134.x).
- Benedict MA, Lauwers GY and Jain D. Gastric adenocarcinoma of the fundic gland type. *Am J Clin Pathol* 2018; 149: 461–473. DOI: [10.1093/ajcp/aaq019](https://doi.org/10.1093/ajcp/aaq019).
- Miyazawa M, Matsuda M, Yano M, et al. Gastric adenocarcinoma of fundic gland type: five cases treated with endoscopic resection. *World J Gastroenterol* 2015; 21: 8208–8214. DOI: [10.3748/wjg.v21.i26.8208](https://doi.org/10.3748/wjg.v21.i26.8208).
- Li C, Wu X, Yang S, et al. Gastric adenocarcinoma of the fundic gland type: clinicopathological features of eight patients treated with endoscopic submucosal dissection. *Diagn Pathol* 2020; 15: 131. DOI: [10.1186/s13000-020-01047-2](https://doi.org/10.1186/s13000-020-01047-2).
- Matsuda A, Matsuda T, Shibata A, et al. Cancer incidence and incidence rates in Japan in 2008: a study of 25 population-based cancer registries for the Monitoring of Cancer Incidence in Japan (MCIJ) project. *Jpn J Clin Oncol* 2014; 44: 388–396. DOI: [10.1093/jjco/hyu003](https://doi.org/10.1093/jjco/hyu003).
- Nomura R, Saito T, Mitomi H, et al. GNAS mutation as an alternative mechanism of activation of the Wnt/ $\beta$ -catenin signaling pathway in gastric adenocarcinoma of the fundic gland type. *Hum Pathol* 2014; 45: 2488–2496. DOI: [10.1016/j.humpath.2014.08.016](https://doi.org/10.1016/j.humpath.2014.08.016).
- Chen O, Shao Z-Y, Qiu X, et al. Multiple gastric adenocarcinoma of fundic gland type: a case report. *World J Clin Cases* 2019; 7: 2871–2878. DOI: [10.12998/wjcc.v7.i18.2871](https://doi.org/10.12998/wjcc.v7.i18.2871).
- Uozumi T, Seki H, Matsuzono E, et al. Gastric adenocarcinoma of fundic gland type arising from heterotopic gastric glands during a 19-year follow-up period. *Clin J Gastroenterol* 2019; 12: 556–561. DOI: [10.1007/s12328-019-00989-5](https://doi.org/10.1007/s12328-019-00989-5).
- Okumura Y, Takamatsu M, Ohashi M, et al. Gastric adenocarcinoma of fundic gland type with aggressive transformation and lymph node metastasis: a case report. *J Gastric Cancer* 2018; 18: 409–416. DOI: [10.5230/jgc.2018.18.e22](https://doi.org/10.5230/jgc.2018.18.e22).
- Parikh ND, Gibson J and Aslanian H. Gastric fundic gland adenocarcinoma with chief cell differentiation. *Clin Gastroenterol Hepatol* 2015; 13: A17–A18. DOI: [10.1016/j.cgh.2015.07.023](https://doi.org/10.1016/j.cgh.2015.07.023).
- Ishibashi F, Fukushima K, Ito T, et al. Influence of Helicobacter pylori infection on endoscopic findings of gastric adenocarcinoma of the fundic gland type. *J Gastric Cancer* 2019; 19: 225–233. DOI: [10.5230/jgc.2019.19.e21](https://doi.org/10.5230/jgc.2019.19.e21).
- Singhi AD, Lazenby AJ and Montgomery EA. Gastric adenocarcinoma with chief cell differentiation. *Am J Surg Pathol* 2012; 36: 1030–1035. DOI: [10.1097/PAS.0b013e31825033e7](https://doi.org/10.1097/PAS.0b013e31825033e7).
- Hidaka Y, Mitomi H, Saito T, et al. Alteration in the Wnt/ $\beta$ -catenin signaling pathway in gastric neoplasias of fundic gland (chief cell predominant) type. *Hum Pathol* 2013; 44: 2438–2448. DOI: [10.1016/j.humpath.2013.06.002](https://doi.org/10.1016/j.humpath.2013.06.002).
- Ueo T, Yonemasu H and Ishida T. Gastric adenocarcinoma of fundic gland type with unusual behavior. *Dig Endosc* 2014; 26: 293–294. DOI: [10.1111/den.12212](https://doi.org/10.1111/den.12212).
- Tsukashita S, Kushima R, Bamba M, et al. MUC gene expression and histogenesis of adenocarcinoma of the stomach. *Int J Cancer* 2001; 94: 166–170. DOI: [10.1002/ijc.1460](https://doi.org/10.1002/ijc.1460).
- Ueyama H, Yao T, Nakashima Y, et al. Gastric adenocarcinoma of fundic gland type (chief cell predominant type): proposal for a new entity of gastric adenocarcinoma. *Am J Surg Pathol* 2010; 34: 609–619. DOI: [10.1097/PAS.0b013e3181d94d53](https://doi.org/10.1097/PAS.0b013e3181d94d53).
- Fan X, Yang X-S, Bai P, et al. Gastric adenocarcinoma of the fundic gland type. *Medicine* 2020; 99: e20361. DOI: [10.1097/md.00000000000020361](https://doi.org/10.1097/md.00000000000020361).
- Terada T. Well differentiated adenocarcinoma of the stomach composed of chief cell-like cells and parietal cells (Gastric adenocarcinoma of fundic gland type). *Int J Clin Exp Pathol* 2011; 4: 797–798.
- Aimasso U, D’Onofrio V, D’Eusebio C, et al. Helicobacter pylori and nutrition: a bidirectional communication. *Minerva Gastroenterologica e Dietologica* 2019; 65: 116–129. DOI: [10.23736/s1121-421x.19.02568-6](https://doi.org/10.23736/s1121-421x.19.02568-6).
- Chitapanarux T, Jesadaporn P, Chitapanarux N, et al. Chronic gastritis according to age and Helicobacter pylori in Thailand: histopathological patterns. *Scand J Gastroenterol* 2021; 56: 228–233. DOI: [10.1080/00365521.2020.1869820](https://doi.org/10.1080/00365521.2020.1869820).
- Chiba T, Kato K, Masuda T, et al. Clinicopathological features of gastric adenocarcinoma of the fundic gland (chief cell predominant type) by retrospective and prospective analyses of endoscopic findings. *Dig Endosc* 2016; 28: 722–730. DOI: [10.1111/den.12676](https://doi.org/10.1111/den.12676).

26. Murakami T, Mitomi H, Yao T, et al. Epigenetic regulation of Wnt/ $\beta$ -catenin signal-associated genes in gastric neoplasia of the fundic gland (chief cell-predominant) type. *Pathol Int* 2017; 67: 147–155. DOI: [10.1111/pin.12509](https://doi.org/10.1111/pin.12509).
27. Yu Y-N, Yin X-Y, Sun Q, et al. Gastric adenocarcinoma of fundic gland type after *Helicobacter pylori* eradication: a case report. *World J Clin Cases* 2019; 7: 1696–1702. DOI: [10.12998/wjcc.v7.i13.1696](https://doi.org/10.12998/wjcc.v7.i13.1696).
28. Kai K, Satake M and Tokunaga O. Gastric adenocarcinoma of fundic gland type with signet-ring cell carcinoma component: a case report and review of the literature. *World J Gastroenterol* 2018; 24: 2915–2920. DOI: [10.3748/wjg.v24.i26.2915](https://doi.org/10.3748/wjg.v24.i26.2915).
29. Uchida A, Ozawa M, Ueda Y, et al. Gastric adenocarcinoma of fundic gland mucosa type localized in the submucosa. *Medicine* 2018; 97: e12341. DOI: [10.1097/md.00000000000012341](https://doi.org/10.1097/md.00000000000012341).
30. Kino H, Nakano M, Kanamori A, et al. Gastric adenocarcinoma of the fundic gland type after endoscopic therapy for metachronous gastric cancer. *Intern Med* 2018; 57: 795–800. DOI: [10.2169/internalmedicine.9359-17](https://doi.org/10.2169/internalmedicine.9359-17).
31. Manabe S, Mukaisho K-i, Yasuoka T, et al. Gastric adenocarcinoma of fundic gland type spreading to heterotopic gastric glands. *World J Gastroenterol* 2017; 23: 7047–7053. DOI: [10.3748/wjg.v23.i38.7047](https://doi.org/10.3748/wjg.v23.i38.7047).
32. Takahashi K, Fujiya M, Ichihara S, et al. Inverted gastric adenocarcinoma of fundic gland mucosa type colliding with well differentiated adenocarcinoma. *Medicine* 2017; 96: e7080. DOI: [10.1097/md.0000000000007080](https://doi.org/10.1097/md.0000000000007080).
33. Komeda Y, Watanabe T, Matsui S, et al. A case of small invasive gastric cancer arising from *Helicobacter pylori*-negative gastric mucosa: fundic gland-type adenocarcinoma. *JGH Open* 2017; 1: 74–75. DOI: [10.1002/jgh3.12011](https://doi.org/10.1002/jgh3.12011).
34. Tohda G, Osawa T, Asada Y, et al. Gastric adenocarcinoma of fundic gland type: endoscopic and clinicopathological features. *World J Gastrointest Endosc* 2016; 8: 244–251. DOI: [10.4253/wjge.v8.i4.244](https://doi.org/10.4253/wjge.v8.i4.244).
35. Kawasaki K, Kurahara K, Oshiro Y, et al. Depressed gastric adenocarcinoma of the fundic gland type. *Intern Med* 2016; 55: 543–544. DOI: [10.2169/internalmedicine.55.5706](https://doi.org/10.2169/internalmedicine.55.5706).
36. Lewin E, Daroca P, Sikka S, et al. Gastric adenocarcinoma of the fundic gland type treated by endoscopic mucosal resection: a case report and review of the literature. *Case Rep Pathol* 2016; 2016: 1–4. DOI: [10.1155/2016/8646927](https://doi.org/10.1155/2016/8646927).
37. Sato Y, Fujino T, Kasagawa A, et al. Twelve-year natural history of a gastric adenocarcinoma of fundic gland type. *Clin J Gastroenterol* 2016; 9: 345–351. DOI: [10.1007/s12328-016-0680-5](https://doi.org/10.1007/s12328-016-0680-5).
38. Takeda S, Mitoro A, Namisaki T, et al. Gastric adenocarcinoma of fundic gland type (chief cell predominant type) with unique endoscopic appearance curatively treated by endoscopic submucosal resection. *Acta Gastro-Enterologica Belgica* 2015; 78: 340–343.
39. Lee S-Y, Saito T, Mitomi H, et al. Mutation spectrum in the Wnt/ $\beta$ -catenin signaling pathway in gastric fundic gland-associated neoplasms/polyps. *Virchows Archiv* 2015; 467: 27–38. DOI: [10.1007/s00428-015-1753-4](https://doi.org/10.1007/s00428-015-1753-4).
40. Kato M, Uraoka T, Isobe Y, et al. A case of gastric adenocarcinoma of fundic gland type resected by combination of laparoscopic and endoscopic approaches to neoplasia with non-exposure technique (CLEAN-NET). *Clin J Gastroenterol* 2015; 8: 393–399. DOI: [10.1007/s12328-015-0619-2](https://doi.org/10.1007/s12328-015-0619-2).
41. Ueyama H, Matsumoto K, Nagahara A, et al. Gastric adenocarcinoma of the fundic gland type (chief cell predominant type). *Endoscopy* 2014; 46: 153–157. DOI: [10.1055/s-0033-1359042](https://doi.org/10.1055/s-0033-1359042).
42. Kushima R, Sekine S, Matsubara A, et al. Gastric adenocarcinoma of the fundic gland type shares common genetic and phenotypic features with pyloric gland adenoma. *Pathol Int* 2013; 63: 318–325. DOI: [10.1111/pin.12070](https://doi.org/10.1111/pin.12070).
43. Park ES, Kim YE, Park CK, et al. Gastric adenocarcinoma of fundic gland type: report of three cases. *Korean J Pathol* 2012; 46: 287–291. DOI: [10.4132/KoreanJPathol.2012.46.3.287](https://doi.org/10.4132/KoreanJPathol.2012.46.3.287).
44. Fukatsu H, Miyoshi H, Ishiki K, et al. Gastric adenocarcinoma of fundic gland type (chief cell predominant type) treated with endoscopic aspiration mucosectomy. *Dig Endosc* 2011; 23: 244–246. DOI: [10.1111/j.1443-1661.2011.01125.x](https://doi.org/10.1111/j.1443-1661.2011.01125.x).