

Outcomes after Surgery for Spinal Metastasis of Colorectal Origin: Case Series

Matthew R Leach, Darryl Lau, Frank La Marca, Paul Park

Department of Neurosurgery, University of Michigan, Ann Arbor, MI, USA

Study Design: Retrospective study.

Purpose: The aim of this study was to evaluate the clinical management and outcomes of patients who underwent surgical intervention for metastatic colorectal adenocarcinoma of the spine.

Overview of Literature: Gastrointestinal (GI) cancer metastasis to the spine are relatively rare and represent later manifestations of the disease. Studies and reports on the outcomes of patients who undergo surgery for spinal metastasis of GI origin are scarce.

Methods: A retrospective chart review of all patients who underwent surgery for spinal metastasis of colorectal origin was performed. Four patients were identified. Patient characteristics, outcomes, and survival were analyzed.

Results: Two patients experienced improvement in pain or myelopathic symptoms. Although the mean survival was 15.3 months, this average included a patient still living at 57.1 months. The mean survival was just 1.3 months for the 3 patients who expired.

Conclusions: In certain cases, symptomatic improvement with prolonged survival is possible after surgery for metastatic spinal lesions of colorectal origin; however, survival is poor in the majority of cases.

Keywords: Cancer; Colorectal; Gastrointestinal; Metastasis; Spine; Surgery

Introduction

Metastases represent the majority of spinal cancers [1]. The primary concern with metastasis is pathologic fracture and/or spinal cord compression, which may lead to intractable pain, sensory alterations, weakness, and/or paralysis [2-8]. Operations in these patients are palliative and are typically performed for symptomatic relief, and thereby, to improve the quality of life rather than survival [2-8]. Of all the metastatic spinal lesions, those of gastrointestinal (GI) origin are particularly aggressive, with the mean survival as low as 2.6 months after diagnosis of a GI-primary spinal lesion [2,9], and high recurrence

rates relative to metastases of other primary cancers [10]. These tumors are also particularly rare, making them difficult to study. GI cancers that reportedly metastasize to the spine include: colon cancer [1,11-16], hepatocellular carcinoma [3,17-20], gastric cancer [1,10], and more rarely, cholangiosarcoma [21-24]. There is a paucity of data available regarding the overall management of patients with GI spinal metastasis, and even less regarding surgical management and outcomes. In this article, we report our findings from a series of 4 surgically managed patients with metastatic spinal disease from colorectal adenocarcinoma and review the current literature on the subject.

Received Feb 12, 2013; Revised Mar 31, 2013; Accepted Apr 2, 2013

Corresponding author: Paul Park

Department of Neurosurgery, University of Michigan, 1500 E. Medical Center Drive, Room 3552 TC, Ann Arbor, MI 48109-5338, USA

Tel: +1-734-615-2627; Fax: +1-734-936-9294, E-mail: ppark@med.umich.edu

Materials and Methods

Following approval by the University of Michigan Institutional Review Board, we queried the electronic medical records for all adult patients who underwent surgery for spinal metastasis from colorectal cancer for the period of 2005 to 2011. Patients were considered candidates for surgery if symptoms included refractory pain and/or neurologic deficit, concern for instability, and if life expectancy was predicted to be at least 3 months. A total of 4 patients underwent spinal surgery. In each case, tumor pathology confirmed metastatic colorectal cancer. A number of covariates in each patient's case were reviewed: age, sex, presenting symptomatology, primary tumor site, presence of extraspinal metastases, comorbidities, use of adjuvant therapies (chemotherapy and/or radiotherapy), procedure performed, functional status (measured by Karnofsky Performance Score [KPS]), neurological status (measured by Nurick score), and pain (measured by visual analogue scale [VAS]). Perioperative and postoperative characteristics of interest included estimated blood loss and complications. Complications were defined as procedure-related or unexpected events, requiring additional intervention at any time within 30 days following the surgery. Clinical outcomes included the Medical Research Council scale of 0 to 5 [25] to assess motor strength, Nurick score [26] of 0 to 5 to assess myelopathy, and follow-up KPS. Survival

length was recorded. Recurrence and repeat surgery for recurrence were also documented.

Results

Table 1 displays demographic information, clinical details, and outcomes for each of the 4 patients included in the study. The mean age at the time of surgery was 61.3 years for colorectal patients, and 1 patient (25.0%) was male. Of the 4 patients, 1 was presented with the inability to ambulate due to lower extremity weakness, 1 presented with back pain only as a primary symptom, and 2 presented with both pain and weakness. Metastases were located in the cervical spine in 1 patient, thoracic spine in 2 patients, and lumbar spine in 1 patient. Surgical procedures are also detailed in Table 1 (Fig. 1). The mean estimated blood loss was 762.5 mL.

Postoperatively, 2 patients had no change in neurological status, while 1 patient regained ambulatory ability for an improved Nurick score, and another experienced loss of ambulation with a decline in the Nurick score. Two patients (patients #1 and #3) showed improved KPS and strength, while the other 2 had lower KPS and no strength changes. Of the 3 patients with pain, 2 experienced significant pain relief with at least a 2-point improvement in VAS. Recurrence occurred in 2 patients, with 1 of the 2 undergoing repeat surgery for worsening pain and neuro-

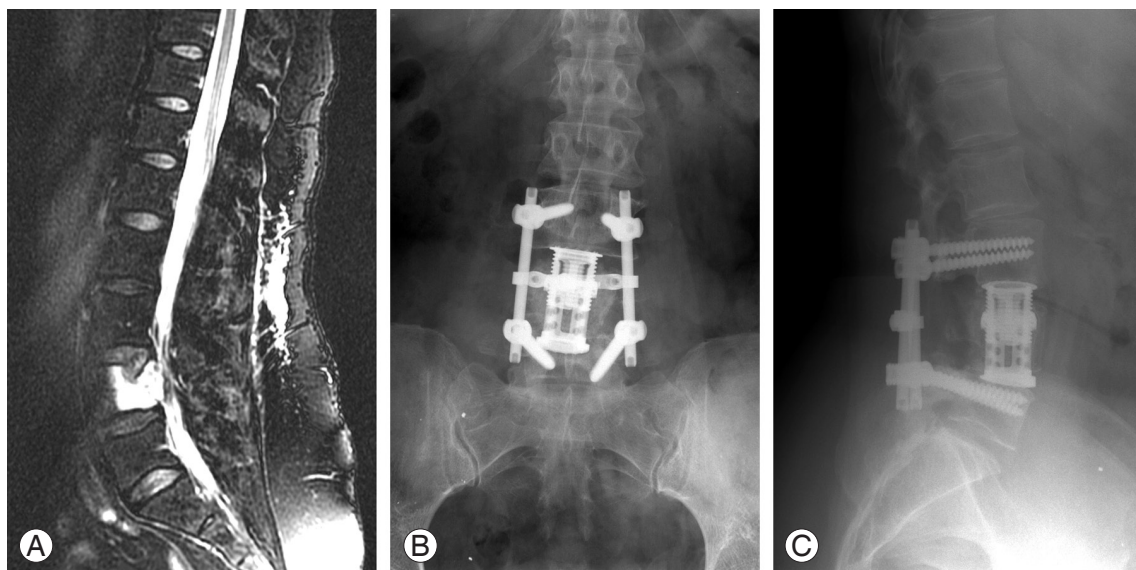


Fig. 1. (A) Sagittal T2-weighted magnetic resonance imaging of patient #1 showing L4 metastasis causing spinal stenosis. (B) Anteroposterior and (C) lateral X-rays showing interbody cage placement and posterior instrumentation after posterolateral corpectomy for tumor resection.

Table 1. Demographics and outcomes for patients with colorectal cancer metastatic to spine

Patient no.	Presentation	Primary tumor	Extraspinal metastases	Sex	Age (yr)	Spinal level	Chemotherapy and/or radiotherapy?	Surgery	Clinical outcome	Recurrence (mo)/repeat surgery?	Survival (mo)
1	Back and leg pain; leg weakness	Rectum	Liver, diffuse bony metastases	Female	51	L4	Yes, yes	Lateral extracavitary approach for L4 corpectomy and tumor resection with L3-L5 posterior fusion	Improved motor strength (from 3 to 4) and VAS score (from 5 to 0) at 1-month follow-up; recurrent pain (due to new metastasis in thoracic spine and jaw), normal motor strength and improved Karnofsky score (from 60 to 80) at 57-month follow-up	Yes (52.2)/no	57.1 (alive at last follow-up)
2	Left arm pain and weakness	Colon	Liver, omentum	Male	57	C4-C5	Yes, yes	Left C4 and C5 laminotomies and facetectomies with resection of tumor; C2 to T2 posterior spinal fusion	Worsened Karnofsky score (from 80 to 20) at 2-week follow-up due to rapid progression of systemic disease causing ascites and jaundice	No/no	1.3
3	Progressive lower extremity weakness	Rectum	Lung, hilar lymph nodes, ribs	Female	60	T7-T12	Yes, yes	T7-T12 laminectomies for epidural tumor resection	Returned ambulation, improved VAS (from 3 to 0), motor strength (from 2 to 3), Nurick (from 5 to 4) and Karnofsky scores (from 30 to 50) at 1-month follow-up	No/no	1.4
4	Worsening back pain and right leg pain (greater than left leg)	Colon	None	Female	77	T12-L1	No, yes	T12-L1 laminectomy for debulking of tumor	Loss of ambulation, worsened Nurick (4 to 5) and Karnofsky (40 to 20) scores at 1-month follow-up	No/no	1.3

VAS, visual analog scale.

logic deficit 1 month after the initial operation. Although the overall mean survival was 15.3 months, this average included a still-living patient. The mean survival of patients who expired was just 1.3 months.

Discussion

About 1.2 million cases of colorectal cancer are diagnosed globally each year, with most being adenocarcinomas [27]. Although more aggressive than breast cancer, mortality rates are otherwise lower than for solid tumors [28]. There is little evidence concerning the surgical management of spinal metastases of colorectal primary origin. Currently, the overall mean survival for all spinal metastases following surgery is about 7 to 8 months [2,17,29,30], with metastasis from GI origin associated with one of the lowest mean survivals at 2.6 months [2]. Patients with metastases from rectal primary sites have been shown to have significantly improved survival over patients with colon primary tumors (7.9 months and 2.7 months, respectively) [31]. Osseous metastases from colorectal malignancies are infrequently seen [11], usually representing a late manifestation of the disease [12], and are frequently asymptomatic [15]. Incidence of such metastases is reported to range anywhere from 2% to as high as 24% in autopsy cases [11-14,16]. Overall, it has been reported that colorectal adenocarcinoma accounts for 1.5% to 4.7% of all metastatic spinal disease [6,31,32]. Colorectal cancer bony metastases are primarily osteolytic and most often involve the vertebral column [33]. The main sites of spinal metastases are the lumbar (36% to 75%) and thoracic spine (17% to 61%), followed by the sacral (6% to 35%) and cervical vertebrae (2% to 7%) [13,34,35]. In about 16% of patients with spinal metastasis, pathological fracture and/or spinal cord compression are found [33].

Medical management of colorectal metastases most commonly consists of chemotherapy with 5-fluorouracil and leucovorin, oxaliplatin or irinotecan, and bevacizumab, cetuximab, or panitumumab where indicated [36-40]. With recent improvements in medical management, survival following colorectal metastasis has been reported to be greater than 20 months. However, this increase in survival has subsequently led to an increase in bony metastasis and its clinical manifestations in these patients. In cases where the patient experiences intractable pain and/or neurological compromise, which causes significant debilitation and overall dysfunction, surgery is a consid-

eration.

The main goals and advantages of surgery in patients with spinal metastasis include decreasing tumor burden, pain relief, prevention and reversal of neurologic deficit, and/or preserving and restoring spinal stability [10,41]. However, there are very few case reports and only 2 small case series that exclusively evaluated surgical management of these patients. In a study focusing primarily on radiotherapy, Brown et al. [31] followed 3 patients who were treated surgically and noted that survival remained poor with patients dying at 3, 4, and 9 months, postoperatively. In that entire cohort, the mean overall survival was 4.1 months, which was similar to other reports of patients who were medically managed [31,33,42]. However, the surgically managed patients tended to fare better than those treated non-operatively; the median overall survival for those 3 patients was 5.3 months [31]. In addition, all 3 surgically treated patients remained ambulatory until death [31]. There is also evidence that more aggressive surgical management can offer prolonged survival. Chen et al. [43] reported an improved mean survival of 10 months with more aggressive treatment, especially in patients with neurological deficit.

While survival time for our colorectal cohort was relatively long with a mean of 15.3 months, the average is biased due to a still-living patient with a survival time of 57.1 months at time of the latest follow-up. Thus, long-term survival is possible in these patients, though our data seem to indicate it to be the exception rather than the rule.

Radiotherapy and/or chemotherapy show limited benefit as the sole means of therapy, especially for metastasis of the GI origin, as several studies have shown that few non-ambulatory patients with metastatic spinal disease of colorectal origin regain ambulation after treatment with chemo-radiotherapy alone [6,31,44-46]. As adjuvant therapy, however, these modalities hold an important place in the treatment of these patients [15]. For patients with short predicted survival or patients unable to tolerate surgery, vertebroplasty and radiotherapy are alternatives [17].

Conclusions

There are no established methods of treating colorectal spinal metastasis, and there are few reports and recommendations regarding this topic. From our experience

and available data, surgical resection and stabilization can result in pain relief, improved neurological function, and improved quality of life. Special care should be taken when assessing patients with colorectal spinal metastases as candidates for surgery, however, as most of these patients have a relatively poor prognosis.

Conflict of Interest

No potential conflict of interest relevant to this article was reported.

References

1. Su YF, Lieu AS, Lin CL, et al. Analysis of surgically treated intraspinal tumors in southern Taiwan. *Kaohsiung J Med Sci* 2007;23:573-8.
2. Arrigo RT, Kalanithi P, Cheng I, et al. Predictors of survival after surgical treatment of spinal metastasis. *Neurosurgery* 2011;68:674-81.
3. El-Serag HB, Mason AC. Rising incidence of hepatocellular carcinoma in the United States. *N Engl J Med* 1999;340:745-50.
4. Harrington KD. Metastatic disease of the spine. *J Bone Joint Surg Am* 1986;68:1110-5.
5. Liaw CC, Ng KT, Chen TJ, Liaw YF. Hepatocellular carcinoma presenting as bone metastasis. *Cancer* 1989;64:1753-7.
6. Martenson JA Jr, Evans RG, Lie MR, et al. Treatment outcome and complications in patients treated for malignant epidural spinal cord compression (SCC). *J Neurooncol* 1985;3:77-84.
7. Tomita K, Kawahara N, Kobayashi T, Yoshida A, Murakami H, Akamaru T. Surgical strategy for spinal metastases. *Spine (Phila Pa 1976)* 2001;26:298-306.
8. Witham TF, Khavkin YA, Gallia GL, Wolinsky JP, Gokaslan ZL. Surgery insight: current management of epidural spinal cord compression from metastatic spine disease. *Nat Clin Pract Neurol* 2006;2:87-94.
9. Chang SS, Luo JC, Chao Y, et al. The clinical features and prognostic factors of hepatocellular carcinoma patients with spinal metastasis. *Eur J Gastroenterol Hepatol* 2001;13:1341-5.
10. Deol GS, Haydon R, Phillips FM. Tumors of the spine. In: Vaccaro AR, editor. *Orthopedic knowledge update 8*. Rosemont: American Academy of Orthopaedic Surgeons; 2005. p.587-98.
11. Besbeas S, Stearns MW Jr. Osseous metastases from carcinomas of the colon and rectum. *Dis Colon Rectum* 1978;21:266-8.
12. Kanthan R, Loewy J, Kanthan SC. Skeletal metastases in colorectal carcinomas: a Saskatchewan profile. *Dis Colon Rectum* 1999;42:1592-7.
13. Katoh M, Unakami M, Hara M, Fukuchi S. Bone metastasis from colorectal cancer in autopsy cases. *J Gastroenterol* 1995;30:615-8.
14. Platell CF. Changing patterns of recurrence after treatment for colorectal cancer. *Int J Colorectal Dis* 2007;22:1223-31.
15. Stewart D, Kitsanta P, Hampton J, Shorthouse A. Asymptomatic isolated coccygeal metastasis in low rectal carcinoma. *Tech Coloproctol* 2011;15:349-51.
16. Sundermeyer ML, Meropol NJ, Rogatko A, Wang H, Cohen SJ. Changing patterns of bone and brain metastases in patients with colorectal cancer. *Clin Colorectal Cancer* 2005;5:108-13.
17. Bartels RH, van der Linden YM, van der Graaf WT. Spinal extradural metastasis: review of current treatment options. *CA Cancer J Clin* 2008;58:245-59.
18. Colombo M. Hepatocellular carcinoma. *J Hepatol* 1992;15:225-36.
19. Greenberg HS, Kim JH, Posner JB. Epidural spinal cord compression from metastatic tumor: results with a new treatment protocol. *Ann Neurol* 1980;8:361-6.
20. Poon RT, Fan ST, O'Suilleabhain CB, Wong J. Aggressive management of patients with extrahepatic and intrahepatic recurrences of hepatocellular carcinoma by combined resection and locoregional therapy. *J Am Coll Surg* 2002;195:311-8.
21. Ishiguchi T, Itoh S, Fukatsu H, et al. Arterial embolization therapy for metastatic bone and soft-tissue tumors with microcatheter and microcoils. *Nihon Igaku Hoshasen Gakkai Zasshi* 1991;51:260-9.
22. Masala S, Roselli M, Manenti G, Mammucari M, Bartolucci DA, Simonetti G. Percutaneous cryoablation and vertebroplasty: a case report. *Cardiovasc Intervent Radiol* 2008;31:669-72.
23. Takahashi I, Nakamura Y, Suzuki Y, Mitsuhashi N, Niibe H, Osada J. Case report: bone metastasis from cholangiocarcinoma showing unusual accumulation on bone scintigraphy and ⁶⁷Ga scintigraphy. *Br J Radiol* 1994;67:303-5.
24. Yeh CN, Chen MF, Chen TC, Tseng JH. Peripheral cholangiocarcinoma with thoracic spine metas-

- tasis: a successful surgically treated case. *Int Surg* 2001;86:225-8.
25. Compston A. Aids to the investigation of peripheral nerve injuries. Medical Research Council: Nerve Injuries Research Committee. His Majesty's Stationery Office: 1942; pp. 48 (iii) and 74 figures and 7 diagrams; with aids to the examination of the peripheral nervous system. By Michael O'Brien for the Guarantors of Brain. Saunders Elsevier: 2010; pp. [8] 64 and 94 Figures. *Brain* 2010;133:2838-44.
 26. Nurick S. The pathogenesis of the spinal cord disorder associated with cervical spondylosis. *Brain* 1972;95:87-100.
 27. Ferlay J, Shin HR, Bray F, Forman D, Mathers C, Parkin DM. Estimates of worldwide burden of cancer in 2008: GLOBOCAN 2008. *Int J Cancer* 2010;127:2893-917.
 28. Jemal A, Siegel R, Xu J, Ward E. Cancer statistics, 2010. *CA Cancer J Clin* 2010;60:277-300.
 29. Hoover JM, Krauss WE, Lanzino G. Intradural spinal metastases: a surgical series of 15 patients. *Acta Neurochir (Wien)* 2012;154:871-7.
 30. van der Linden YM, Dijkstra SP, Vonk EJ, Marijnen CA, Leer JW, Dutch Bone Metastasis Study Group. Prediction of survival in patients with metastases in the spinal column: results based on a randomized trial of radiotherapy. *Cancer* 2005;103:320-8.
 31. Brown PD, Stafford SL, Schild SE, Martenson JA, Schiff D. Metastatic spinal cord compression in patients with colorectal cancer. *J Neurooncol* 1999;44:175-80.
 32. Barron KD, Hirano A, Araki S, Terry RD. Experiences with metastatic neoplasms involving the spinal cord. *Neurology* 1959;9:91-106.
 33. Santini D, Tampellini M, Vincenzi B, et al. Natural history of bone metastasis in colorectal cancer: final results of a large Italian bone metastases study. *Ann Oncol* 2012;23:2072-7.
 34. Bonnheim DC, Petrelli NJ, Herrera L, Walsh D, Mittelman A. Osseous metastases from colorectal carcinoma. *Am J Surg* 1986;151:457-9.
 35. Talbot RW, Irvine B, Jass JR, Dowd GS, Northover JM. Bone metastases in carcinoma of the rectum: a clinical and pathological review. *Eur J Surg Oncol* 1989;15:449-52.
 36. Douillard JY, Siena S, Cassidy J, et al. Randomized, phase III trial of panitumumab with infusional fluorouracil, leucovorin, and oxaliplatin (FOLFOX4) versus FOLFOX4 alone as first-line treatment in patients with previously untreated metastatic colorectal cancer: the PRIME study. *J Clin Oncol* 2010;28:4697-705.
 37. Goldberg RM, Sargent DJ, Morton RF, et al. A randomized controlled trial of fluorouracil plus leucovorin, irinotecan, and oxaliplatin combinations in patients with previously untreated metastatic colorectal cancer. *J Clin Oncol* 2004;22:23-30.
 38. Saltz LB, Clarke S, Diaz-Rubio E, et al. Bevacizumab in combination with oxaliplatin-based chemotherapy as first-line therapy in metastatic colorectal cancer: a randomized phase III study. *J Clin Oncol* 2008;26:2013-9.
 39. Tournigand C, Andre T, Achille E, et al. FOLFIRI followed by FOLFOX6 or the reverse sequence in advanced colorectal cancer: a randomized GERCOR study. *J Clin Oncol* 2004;22:229-37.
 40. Van Cutsem E, Kohne CH, Hitre E, et al. Cetuximab and chemotherapy as initial treatment for metastatic colorectal cancer. *N Engl J Med* 2009;360:1408-17.
 41. Lin CC, Chen PQ, Chen WJ, Chen LH. Prognosis of operative treatment for metastatic hepatocellular carcinoma of the spine. *Clin Orthop Relat Res* 2006;444:209-15.
 42. Geh JI, Glynne-Jones R. Cervical spine involvement in metastatic colorectal carcinoma. *Clin Oncol (R Coll Radiol)* 1998;10:125-8.
 43. Chen LH, Chen WJ, Niu CC, Shih CH. Anterior reconstructive spinal surgery with Zielke instrumentation for metastatic malignancies of the spine. *Arch Orthop Trauma Surg* 2000;120:27-31.
 44. Gilbert RW, Kim JH, Posner JB. Epidural spinal cord compression from metastatic tumor: diagnosis and treatment. *Ann Neurol* 1978;3:40-51.
 45. Maranzano E, Latini P. Effectiveness of radiation therapy without surgery in metastatic spinal cord compression: final results from a prospective trial. *Int J Radiat Oncol Biol Phys* 1995;32:959-67.
 46. Young RF, Post EM, King GA. Treatment of spinal epidural metastases. Randomized prospective comparison of laminectomy and radiotherapy. *J Neurosurg* 1980;53:741-8.