

## Recurrent refractive error after myopic laser-assisted *in situ* keratomileusis – What could be the reason?

Radhika Natarajan, Raj S Paul

Recurrence of myopia after myopic LASIK reduces the outcome of the procedure. Important causes include post-LASIK ectasia, regression of myopia, accommodative strain, and lens or axial length changes. Herein, we present a case of myopia recurring after LASIK and try to arrive at the possible diagnosis among these, as the treatment differs for each. The detailed evaluation showed that our patient had regression of myopia after LASIK. Of the multiple causes for recurrence of refractive error after myopic laser vision correction, it is important to identify the relevant reason as the treatment and prognosis for each of these is different.

**Key words:** Post LASIK, recurrent myopia, regression

Recurrence of myopia after myopic laser-assisted *in situ* keratomileusis (LASIK) is often a source of discontentment for the patient and dissatisfaction for the surgeon. Important causes include post-LASIK ectasia<sup>[1]</sup> and regression of myopia<sup>[2,3]</sup> besides others related to accommodative strain<sup>[4]</sup> as well as lens and axial length<sup>[2]</sup> changes. Herein, we present a case of myopia recurring after LASIK and try to arrive at the possible diagnosis among these, as the treatment is different for each.

### Case Report

A 29-year-old woman presented with the blurring of vision over the last few years. She had undergone myopic femtosecond LASIK in both eyes 5 years back elsewhere and had not followed up after that. According to records, her preoperative refractive error was -3.5 DS in both eyes. No details were available about her pre-LASIK work up. Her post-LASIK result was documented as a Snellen vision of 20/20 with the near vision of N6 with a distance correction of -0.25 DS. There was no other contributing history.

On examination, her uncorrected Snellen vision was 20/40, near vision N6 and 20/200, near vision N6 in the right and left eye, respectively. Her best-corrected Snellen vision was 20/20, near vision N6 in both eyes. Cycloplegic refraction was -1.25 DS in the right eye and -3.75DS in the left eye. Keratometry was 41.00 @165; 42.25 @ 75 in the right eye and 41.25@160; 43.50 @ 70 in the left eye. Slit-lamp examination revealed good LASIK flaps with edges faintly seen. The interfaces showed 1+ haze in both the eyes. There was no clinical evidence of post-LASIK ectasia in either eye. Her crystalline lenses were clear. Rest of the ocular examination was normal. Corneal tomography showed no evidence of post-LASIK ectasia. [Figs. 1 and 2]. Epithelial mapping using anterior segment optical coherence tomography (ASOCT, Cirrus HD-OCT 5000 Carl Zeiss Meditec) did not reveal any compensatory central hyperplasia which could account for the recurrent myopic error. Axial length measurements did not show abnormal elongation of the globes. Orthoptic and binocular vision evaluation did not reveal any accommodative strain. Pentacam Scheimpflug densitometry testing showed moderately high values (25.4 to 28.2 Grey Scale Units) in the flap region, more in the left eye than in the right eye. This was also corroborated as a haze on ASOCT imaging [Fig. 3a and b].

The patient was diagnosed to have regression of refractive error following myopic LASIK. The negative tests helped rule out many of the other reasons for recurrent myopia. She was counseled for options of refractive correction including glasses, contact lenses, surface ablation with mitomycin C, and LASIK enhancement.

### Discussion

Patients who undergo laser vision correction are often unhappy with less than perfect quality or quantity of uncorrected vision. Surgeons sometimes under correct myopic LASIK due to pachymetric limitation or to confer monovision for presbyopia. Besides, less often done to keep postoperative keratometric flattening in check to avoid the suboptimal visual result. These are usually explained during preoperative counseling.

Myopic laser treatments can induce asthenopic symptoms or worsen existing ones. The accommodative spasm can show up as recurrent myopia. Routine pre and postoperative orthoptic evaluation can unmask the problem. These patients benefit from binocular vision therapy.<sup>[4]</sup>

Myopes are prone to develop presenile cataracts. Nuclear sclerosis manifests as index myopia much before visible lens changes or drops in vision happen.<sup>[5]</sup> Sophisticated lens imaging, if accessible, can confirm this. When cataract advances,

Access this article online	
Quick Response Code:	Website: www.ijjo.in
	DOI: 10.4103/ijjo.IJO_1937_20

Department of Refractive Surgery, Medical Research Foundation, Sankara Nethralaya, Chennai, Tamil Nadu, India

**Correspondence to:** Dr. Radhika Natarajan, Sankara Nethralaya, Medical Research Foundation, 18 College Road, Nungambakkam, Chennai - 600 006, Tamil Nadu, India. E-mail: 100radsam@gmail.com

Received: 18-Jun-2020

Revision: 16-Jul-2020

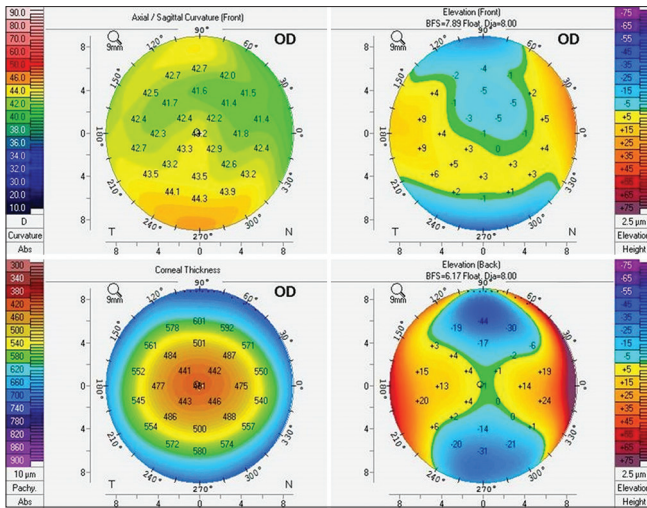
Accepted: 17-Aug-2020

Published: 23-Nov-2020

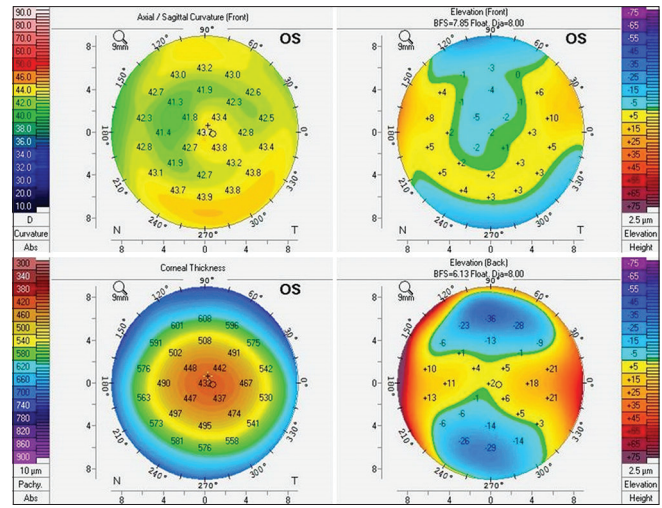
This is an open access journal, and articles are distributed under the terms of the Creative Commons Attribution-NonCommercial-ShareAlike 4.0 License, which allows others to remix, tweak, and build upon the work non-commercially, as long as appropriate credit is given and the new creations are licensed under the identical terms.

**For reprints contact:** WKHLRPMedknow\_reprints@wolterskluwer.com

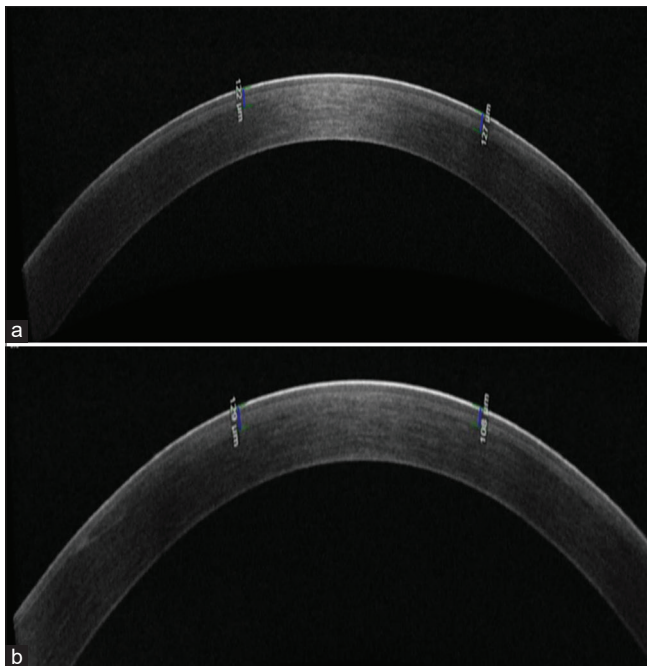
**Cite this article as:** Natarajan R, Paul RS. Recurrent refractive error after myopic laser-assisted *in situ* keratomileusis – What could be the reason? Indian J Ophthalmol 2020;68:3048-50.



**Figure 1:** Post-LASIK corneal tomography of the right eye (OCULUS Pentacam 2, Optikgeräte GmbH)



**Figure 2:** Post-LASIK corneal tomography of the left eye (OCULUS Pentacam 2, Optikgeräte GmbH)



**Figure 3:** (a) Interface haze seen in the ASOCT of the right eye (TOMEY SS-1000 CASIA OCT). (b) Interface haze seen in the ASOCT of the left eye (TOMEY SS-1000 CASIA OCT)

surgery can be done for vision and refractive solutions. Rarely in pathological myopia, the axial length can go on increasing even in adults.<sup>[6]</sup> Serial biographic documentation in high myopes would offer evidence.

Iatrogenic ectasia is a rare but dreaded complication following LASIK even when all rules are respected. Increasing corneal steepness causes a myopic shift first much like keratoconus. Collagen cross-linking treatment is done to stabilize the cornea followed by refractive correction with contact lenses.<sup>[7]</sup> Epithelial hyperplasia after surface ablation and rarely after LASIK which had epithelial disturbance can mimic

corneal ectasia.<sup>[8]</sup> Epithelial mapping on OCT can help diagnose this condition. Relevant history, examination, and investigations did not reveal any of the above problems in our patient.

Regression of myopia after laser vision correction can sometimes happen due to a healing response to the ablation.<sup>[8,9]</sup> The “in-situ” location of the “keratomileusis” invites a far less healing response in LASIK as opposed to surface ablative treatments which is the unique selling point of the procedure. However, when it does happen, the regenerative tissue can lead to blurred vision and can bring back some myopia. “Haze” is due to the resultant scar while “regression” is the recurrence of refractive error. Though an exaggerated healing response is a cause for both, the former affects the quality while the latter affects the quantity of uncorrected vision and the two terms cannot be interchanged. Regression has been linked with older laser types, larger ablations, and interfaces inflammation.<sup>[10]</sup> It can show up 1 to 3 months after treatment and can slowly progress for some years. The interface may show scarring which when subtle can be picked up on anterior segment OCT and Pentacam densitometry as in our patient. Treatment can be conservative with glasses or contact lenses. After watching for stability, surface ablation with mitomycin C or LASIK enhancement can be contemplated after thorough testing and due counseling.

### Conclusion

Our patient had regression of myopia after LASIK. There are multiple causes for recurrence of refractive error after myopic laser vision correction. It is important to identify the relevant reason as the treatment and prognosis for each of these is different.

### Declaration of patient consent

The authors certify that they have obtained all appropriate patient consent forms. In the form the patient(s) has/have given his/her/their consent for his/her/their images and other clinical information to be reported in the journal. The patients understand that their names and initials will not be published and due efforts will be made to conceal their identity, but anonymity cannot be guaranteed.

### Financial support and sponsorship

Nil.

### Conflicts of interest

There are no conflicts of interest.

### References

1. Bohac M, Koncarevic M, Pasalic A, Biscevic A, Merlak M, Gabric N, *et al.* Incidence and clinical characteristics of post LASIK ectasia: A review of over 30,000 LASIK cases. *Semin Ophthalmol* 2018;33:869-77.
  2. Zhou J, Gu W, Li S, Wu L, Gao Y, Guo X. Predictors affecting myopic regression in -6.0D to -10.0D myopia after laser-assisted subepithelial keratomileusis and laser *in situ* keratomileusis flap creation with femtosecond laser-assisted or mechanical microkeratome-assisted. *Int Ophthalmol* 2020;40:213-25.
  3. Lim SA, Park Y, Cheong YJ, Na KS, Joo C-K. Factors affecting long-term myopic regression after laser *in situ* keratomileusis and laser-assisted subepithelial keratectomy for moderate myopia. *Korean J Ophthalmol* 2016;30:92-100.
  4. Prakash G, Sharma N, Sharma P, Choudhary V, Titiyal JS. Accommodative spasm after Laser-assisted *in situ* keratomileusis (LASIK). *Am J Ophthalmol* 2006;141:1163-4.
  5. Pokroy R, Mimouni M, Sela T, Munzer G, Kaiserman I. Myopic laser *in situ* keratomileusis retreatment: Incidence and associations. *J Cataract Refract Surg* 2016;42:1408-14.
  6. Saka N, Moriyama M, Shimada N, Nagaoka N, Fukuda K, Hayashi K, *et al.* Changes of axial length measured by IOL master during 2 years in eyes of adults with pathologic myopia. *Graefes Arch Clin Exp Ophthalmol* 2013;251:495-9.
  7. Sharif W, Ali ZR, Sharif K. Long term efficacy and stability of corneal collagen cross linking for post-LASIK ectasia: An average of 80 mo follow-up. *Int J Ophthalmol* 2019;12:333-7.
  8. Spadea L, Giovannetti F. Main complications of photorefractive keratectomy and their management. *Clin Ophthalmol* 2019;13:2305-15.
  9. Moshirfar M, Desautels JD, Walker BD, Murri MS, Birdsong OC, Hoopes PCS. Mechanisms of optical regression following corneal laser refractive surgery: Epithelial and stromal responses. *Med Hypothesis Discov Innov Ophthalmol* 2018;7:1-9.
  10. Sridhar MS, Rao SK, Vajpayee RB, Aasuri MK, Hannush S, Sinha R. Complications of laser-in-situ-keratomileusis. *Indian J Ophthalmol* 2002;50:265-82.
-