

Successful Treatment of Life-Threatening COVID-19 Infection in a Face Transplant Recipient

Demetrius M. Coombs, MD,^a Grzegorz J. Kwiecien, MD,^a Christine Koval, MD,^b Bijan Eghtesad, MD,^c Francis A. Papay, MD,^a Maria Siemionow, MD, PhD,^d and Brian R. Gastman, MD^a

Abstract: Recent literature suggests that severe COVID-19 is associated with an exaggerated immune response during viral infection, resulting in cytokine storm. Although elevated plasma interleukin 6 (IL-6) has been reported in severe COVID-19 infections, and treatment with anti-IL-6 (tocilizumab) has demonstrated promising outcomes both domestically and abroad, reports remain limited and therapeutic regimens vary considerably. Furthermore, research pertaining to transplant recipients, COVID-19 infection, and anti-IL-6 therapy remains underdeveloped. Herein, we report the successful treatment of the only reported facial vascularized composite allograft (VCA) recipient who contracted severe COVID-19 and the first reported VCA recipient with COVID-19 infection that received anti-IL-6 immunotherapy resulting in an excellent recovery despite his multiple preexisting and COVID-19-related comorbidities—adult respiratory distress syndrome, acute renal failure requiring hemodialysis, and concomitant sepsis due to extensive drug-resistant bacterial pneumonia upon presentation. To date, he has not demonstrated any anti-IL-6 drug-related adverse effects. This preliminary report also suggests that our immunosuppressed VCA patients can indeed demonstrate a robust cytokine response during COVID-19 infection and may also respond favorably to emerging anticytokine immune therapies. We hope that our experience proves helpful to other centers that might encounter critically ill VCA recipients in the ongoing COVID-19 pandemic and in the years to follow.

Key Words: COVID-19, coronavirus, face transplant, vascularized composite allograft, VCA, interleukin 6, IL-6, anti-IL-6, tocilizumab, cytokine storm, immune therapy, outcomes

(*Ann Plast Surg* 2021;87: 105–106)

Recent literature suggests that COVID-19 case severity is associated with an uncontrolled immunologic response to viral infection (eg, cytokine storm), and elevated plasma interleukin 6 (IL-6) has been reported in severe COVID-19 infections.^{1,2} Treatment with monoclonal antibody immunotherapy targeting IL-6 (tocilizumab) has demonstrated promising outcomes within the United States, Europe, and China^{1,3}; however, reports remain limited and therapeutic regimens vary considerably.^{2,4} The growing body of research pertaining to COVID-19 infection and anti-IL-6 therapy is less developed with regard to transplant patients—a subset at high risk of developing devastating infections due to chronic immunosuppression.^{5,6} This report highlights the successful treatment of a facial vascularized composite allograft (VCA) recipient with significant comorbidities, who received anti-IL-6, and survived the worst morbidities of COVID-19, including adult respiratory distress syndrome (ARDS), acute renal failure requiring hemodialysis, and septic shock in the setting of extensive drug-resistant bacterial pneumonia.

Based on our review, this case is also the first such report within the plastic surgery and VCA-related literature.

PATIENT PRESENTATION

In review, this is a 51-year-old man, who, after a motor vehicle accident, was diagnosed with granulomatosis with polyangiitis, formerly known as Wegener granulomatosis. A substantial amount of time passed before identification of his underlying disease, during which a tremendous amount of soft tissue necrosis occurred, including components of the skull base. Ultimately, the patient was started on immunosuppression and underwent a maxilla-containing facial VCA in 2014. In addition, his medical history included morbid obesity, hypertension, and diabetes.

The patient experienced numerous episodes of rejection in the years after transplant; however, these episodes were successfully managed with alterations in immunosuppression (tacrolimus and prednisone). Five years after the transplant, he was admitted to an outside facility with pneumonia and subsequently transferred to our institution. He was promptly identified as having a duodenal perforation that required open repair complicated by fistula formation and need for total parenteral nutrition. After months of hospitalization, including intensive care unit (ICU) transfers, tracheostomy due to prolonged ventilatory requirements, and an extremely high risk of mortality given the nature of the admission and preexisting comorbidities, he recovered sufficiently to meet criteria for transfer to an outside skilled nursing facility. The tracheostomy remained in place.

There he developed COVID-19 infection and was admitted to an outside hospital ICU. After discussion with the outside intensivist, our infectious disease colleagues, and after careful consideration by our plastic surgery team, the patient was promptly transferred to our institution for initiation of anti-IL-6 therapy. He was in septic shock upon arrival, afebrile with a leukocytosis of 19.08 k/uL, and requiring vasopressors for hemodynamic support. Ventilator settings included 100% FiO₂ and positive end-expiratory pressure 20 cmH₂O. Serum IL-6 was 438 pg/mL, and he received 400 mg of tocilizumab intravenously on the second day of admission. He also received stress-dose steroids and broad-spectrum antibiotics (piperacillin-tazobactam and vancomycin). Hydroxychloroquine was initiated at the outside facility and continued upon admission. He received azithromycin before arrival. Initial plain films revealed slight subsegmental atelectasis of the midright lung, mild increase in atelectasis of the medial bases (left greater than right), concern for superimposed infiltrates/infection, and small left pleural effusion (Fig. 1).

Anti-interleukin 6 therapy did not immediately improve the patient's condition. Bronchoalveolar lavage cultures revealed drug-resistant *Pseudomonas aeruginosa* and *Corynebacterium striatum*, and he received combination antibiotic therapy (ceftolozane/tazobactam, inhaled colistin, and vancomycin). After ongoing care in our COVID ICU, he improved to the point that criteria were met for transfer to a skilled nursing facility. At the time of transfer, on hospital day 24, C-reactive protein had decreased from 36.5 to 3.4 mg/dL. He had modest ventilatory requirements, but repeat plain films were notable for stable-to-improved right middle and lower lung airspace opacities (Fig. 2).

Received August 27, 2020, and accepted for publication, after revision January 14, 2021. From the Departments of ^aPlastic Surgery, ^bInfectious Disease, ^cGeneral Surgery, Transplant Division, The Cleveland Clinic, Cleveland, OH; and ^dDepartment of Orthopaedics, University of Illinois at Chicago, Chicago IL.

Supported by the grant from the Department of Defense Armed Forces Institute for Regenerative Medicine (W81XWH-08-2-0034).

Reprints: Brian R. Gastman, MD, The Cleveland Clinic, 9500 Euclid Ave/A60, Cleveland, OH 44195. E-mail: gastmanb@ccf.org

Copyright © 2021 Wolters Kluwer Health, Inc. All rights reserved.

ISSN: 0148-7043/21/8701-0105

DOI: 10.1097/SAP.0000000000002790

We did not cease immunosuppression during the acute phases of this admission but did manage him with reduced tacrolimus dosing. He did not develop any signs of rejection while hospitalized or after transfer. He resolved from the standpoint of renal injury with laboratories revealing a near-normal serum creatinine (1.40 from 5.13 mg/dL). Our team remains in close conversation with his outside physicians, and he was recently decannulated and preparing for discharge to home; repeat COVID nasopharyngeal swab was negative by polymerase chain reaction.

CONCLUSIONS

We report the successful treatment of the only reported facial VCA recipient who contracted severe COVID-19, and the first reported VCA recipient with COVID infection who received anti-IL-6 immunotherapy resulting in recovery—despite ARDS, acute renal failure requiring hemodialysis and concomitant sepsis upon presentation. To date, he has not demonstrated any drug-related adverse effects, and this preliminary report suggests that our immunosuppressed VCA patients can indeed demonstrate a robust cytokine response during COVID-19 infection but may also respond favorably to emerging anticytokine immune therapies. This picture is an interesting dichotomy, as prior literature suggests that immunosuppression may protect against

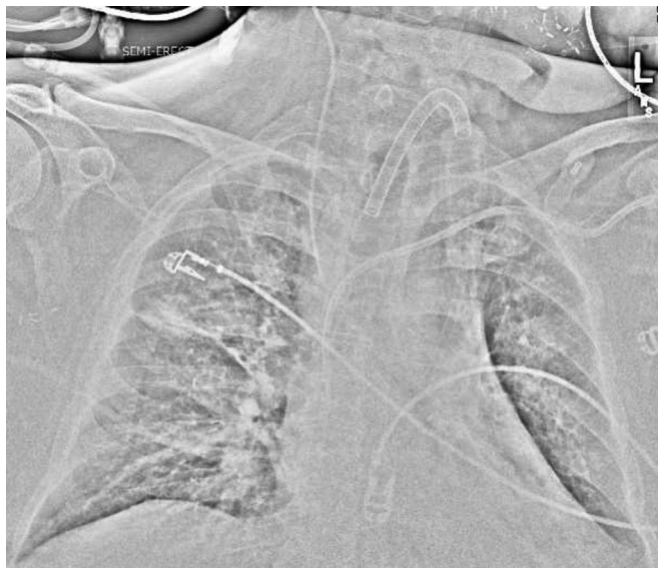

FIGURE 1. Plain film of the chest upon admission to our institution. Note the slight subsegmental atelectasis of the midright lung, mild increase in atelectasis of the medial bases (left greater than right), and concern for superimposed infiltrates/infection and small left pleural effusion.

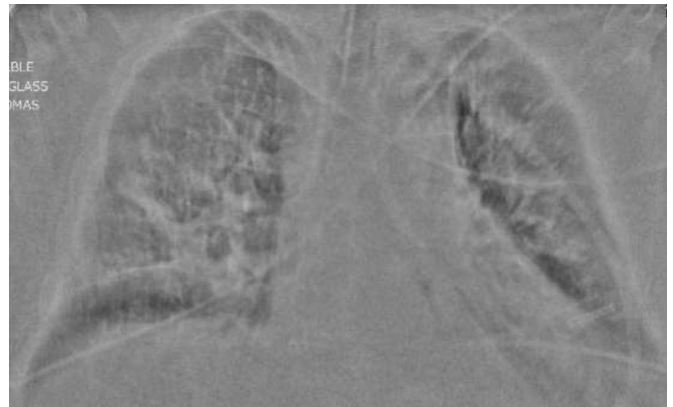


FIGURE 2. Plain film of the chest before transfer from our institution to a skilled nursing facility. Note the stable to improved right middle and lower lung airspace opacities.

COVID-related hyperinflammatory responses.⁷ Our institution has reported success with anti-IL-6 therapy,⁵ and we now share the details of our experience with this novel therapy when treating severe COVID-19 in the setting of prior facial VCA. In a broader sense, the beneficial effects of immune therapy in these patients remain unclear and randomized controlled trials are pending. Similarly, the timing of anti-IL-6 use in relation to the onset of ARDS and the need for invasive ventilation is debated. Although other studies have treated patients before overt cytokine activation,⁸ we waited until afterward. More data are urgently needed to better delineate the immune response and long-term effects of coronavirus infections in this unique patient population.

REFERENCES

1. Alijotas-reig J, Esteve-valverde E, Belizna C, et al. Immunomodulatory therapy for the management of severe COVID-19. Beyond the anti-viral therapy: a comprehensive review. *Autoimmun Rev.* 2020;19:102569.
2. Antwi-amoabeng D, Kanji Z, Ford B, et al. Clinical outcomes in COVID-19 patients treated with tocilizumab: an individual patient data systematic review. *J Med Virol.* 2020;92:2516–2522.
3. Convertino I, Tuccori M, Ferraro S, et al. Exploring pharmacological approaches for managing cytokine storm associated with pneumonia and acute respiratory distress syndrome in COVID-19 patients. *Crit Care.* 2020;24:331.
4. Michot JM, Albiges L, Chaput N, et al. Tocilizumab, an anti-IL-6 receptor antibody, to treat COVID-19-related respiratory failure: a case report. *Ann Oncol.* 2020;31:961–964.
5. Morillas JA, Canosa FM, Srinivas P, et al. Tocilizumab therapy in 5 solid and composite tissue transplant recipients with early ARDS due to SARS-CoV-2. *Am J Transplant.* 2020;20:3191–3197.
6. Meziyerh S, Zwart TC, Van etten RW, et al. Severe COVID-19 in a renal transplant recipient: a focus on pharmacokinetics. *Am J Transplant.* 2020;20:1896–1901.
7. Mehta P, McAuley DF, Brown M, et al. COVID-19: consider cytokine storm syndromes and immunosuppression. *Lancet.* 2020;395:1033–1034.
8. Kewan T, Covut F, Al-Jaghbeer MJ, et al. Tocilizumab for treatment of patients with severe COVID-19: a retrospective cohort study. *EClinicalMedicine.* 2020;24:100418.