

# Clinical Features and Treatment of Fibrous Histiocytomas of the Tongue: A Systematic Review

Austin Nguyen<sup>1</sup> Adam Vaudreuil<sup>1</sup> Paul Haun<sup>2</sup> Gabriel Caponetti<sup>2</sup> Christopher Huerter<sup>1</sup>

<sup>1</sup>Division of Dermatology, Creighton University School of Medicine, Omaha, Nebraska, United States

<sup>2</sup>Department of Pathology and Laboratory Medicine, University of Pennsylvania Perelman School of Medicine, Philadelphia, Pennsylvania, United States

Address for correspondence Austin Nguyen, MS, Division of Dermatology, Creighton University School of Medicine, 2500 California Plaza, Omaha, NE 68178, United States (e-mail: ahn30605@creighton.edu).

Int Arch Otorhinolaryngol 2018;22:94–102.

## Abstract

**Introduction** Benign fibrous histiocytomas are common lesions of the skin that rarely affect the tongue. Such cases are available in the literature exclusively as case reports. Similarly, malignant fibrous histiocytoma, now classified as undifferentiated pleomorphic sarcoma, is exceedingly rare in the tongue and not fully understood.

**Objectives** This study systematically reviews the available literature discussing the clinical and pathological features of malignant and benign fibrous histiocytomas.

**Data Synthesis** A total of 20 cases were included in this review. Patient-level data were extracted from cases to include clinical presentation, workup, treatment, and outcome.

**Conclusion** Benign fibrous histiocytomas are consistent in clinical and histopathologic presentation. Surgical treatment provides excellent outcome, with no recurrence in all excised cases. Malignant tumors have a more aggressive clinical and pathological presentation. Surgical treatment with possible adjuvant radiotherapy resulted in recurrence in 40% of cases (follow-up of 24 months), and death due to disease in 47% of patients (follow-up of 19 months).

## Keywords

- ▶ dermatofibrosarcoma
- ▶ dermatofibroma
- ▶ fibrous histiocytoma
- ▶ tongue neoplasm

## Introduction

Fibrous histiocytomas can be classified as benign and malignant. Benign fibrous histiocytomas (BFHs) can be further sub-divided by tissue of origin, either dermal or deep (subcutaneous). Cutaneous benign fibrous histiocytoma, or dermatofibroma, is localized to the dermis and characterized by an assortment of spindle and/or rounded cells.<sup>1</sup> It is a common lesion seen in many age groups, with predominance in the 3rd and 4th decades of life, and gender distribution varying by population.<sup>1</sup> The majority of lesions are found on the extremities, with lesions rarely arising on the face.<sup>1</sup> Clinically, BFHs present as single, round lesions, appearing

reddish early on, and transitioning to more brown or skin-colored with time. They are moderately well circumscribed, and produce the characteristic “dimpling” sign when squeezed between the examiners fingers.<sup>1</sup> Benign fibrous histiocytomas have a variable immunohistochemical profile and multiple histologic subtypes: aneurysmal, epithelioid, cellular, angiomatoid, etc. These lesions are considered benign, and tend to recur only with incomplete excision.<sup>1</sup> Deep BFHs generally involve subcutaneous tissue, and affects adults over 25 years, with a mean age of 40 years.<sup>2,3</sup> Similar to BFHs, the majority of deep BFHs are on the extremities, but may also occur in the head and neck region.<sup>2</sup> Clinically, deep BFH lesions are seen as painless, slowly enlarging masses,

received  
October 31, 2016  
accepted  
March 9, 2017  
published online  
May 2, 2017

DOI <https://doi.org/10.1055/s-0037-1602819>.  
ISSN 1809-9777.

Copyright © 2018 by Thieme Revinter Publicações Ltda, Rio de Janeiro, Brazil

License terms



and are more well circumscribed/encapsulated than the cutaneous form.<sup>2</sup> Metastasis has yet to be reported.

Malignant fibrous histiocytoma (MFH) was first described by O'Brien and Stout in 1964.<sup>4</sup> Malignant fibrous histiocytoma was historically thought to be the malignant and undifferentiated counterpart of the BFH. Recent advances have changed our understanding of their cell origin, resulting in reclassification as undifferentiated pleomorphic sarcoma. However, many clinicians continue to use the broader term MFH. In adults, MFH is the second most common soft tissue sarcoma (STS), with an incidence of 0.88 cases per 100,000 annually.<sup>5</sup> It occurs more commonly in men (2:1, Male: Female), and the incidence increases with age.<sup>5,6</sup> Malignant fibrous histiocytoma is one of the most commonly diagnosed sarcomas in patients with prior radiation exposure in the head or neck region.<sup>7</sup> The most common locations of these tumors in order are the head and neck, the extremities, the trunk, and the retroperitoneum.<sup>8</sup> Those occurring on the head and neck might exhibit a more aggressive course; one study reported a 5-year overall survival of 48% for patients with head and neck tumors compared with 77% for patients with trunk or extremity tumors.<sup>9</sup>

The clinical presentation typically involves a painless, enlarging nodule that can become painful if enlarging rapidly.<sup>8</sup> Identification often involves histologic and immunohistochemical evaluations. Treatment typically involves wide local excision, en bloc resection with 2cm margins of uninvolved tissue, or Mohs surgery.<sup>8,10</sup> However, local recurrence rates are high, ranging from 25 to 75%.<sup>5,8</sup> Additional treatment with adjuvant radio- or chemotherapy should be considered on an individual case basis.<sup>11</sup>

Malignant or benign fibrous histiocytoma involvement of the tongue is considerably rare, and offers additional symptomatology, such as difficulty speaking or swallowing.<sup>12,13</sup> Our review of the available literature identified 20 published cases. Thus, the present review serves to comprehensively describe previously published cases of BFH and MFH involving the tongue and aggregate information involving the rare presentation of this tumor entity.

## Review of the Literature

### Literature Search

The National Library of Medicine PubMed database was searched for articles discussing dermatofibromas and dermatofibrosarcomas, or fibrous histiocytomas affecting the tongue. The following search terms were used: *tongue* and *lingual* combined with *undifferentiated pleomorphic sarcoma*, *dermatofibroma*, *fibrous histiocytoma*, and *dermatofibrosarcoma*. The articles were screened for relevance based on title and abstract. Potentially relevant articles were subsequently reviewed in full-text for final inclusion decision. Additionally, the references of each included article were screened for additional potentially relevant articles. Potentially relevant articles were case reports or case series or studies discussing fibrous histiocytomas affecting the tongue that described patient-level data and met the inclusion criteria. The inclusion criteria were: articles discussing the clinical course of cases of

lingual fibrous histiocytoma, including presentation, diagnostic workup, treatment, and outcome. Articles were excluded if they did not contain patient-level data and/or original data (that is, literature reviews), did not pertain to the present topic, or were published in a language other than English. Of the included articles, patient-level data was extracted and discussed in the present review.

The search of the PubMed database through September 2016 (►Fig. 1) returned 234 articles. Screening by title and abstract left 18 potentially relevant articles for full-text review. Upon full-text review, two studies were excluded for having diagnoses that did not meet the inclusion criteria (that is, a diagnosis other than fibrous histiocytoma). Two additional articles were found to meet the inclusion criteria upon the screening of the article citations. Ultimately, a group of 18 articles, describing 20 cases, was included in this review. These cases included 15 malignant<sup>12,14–25</sup> and 5 benign<sup>13,26–29</sup> fibrous histiocytomas affecting the tongue.

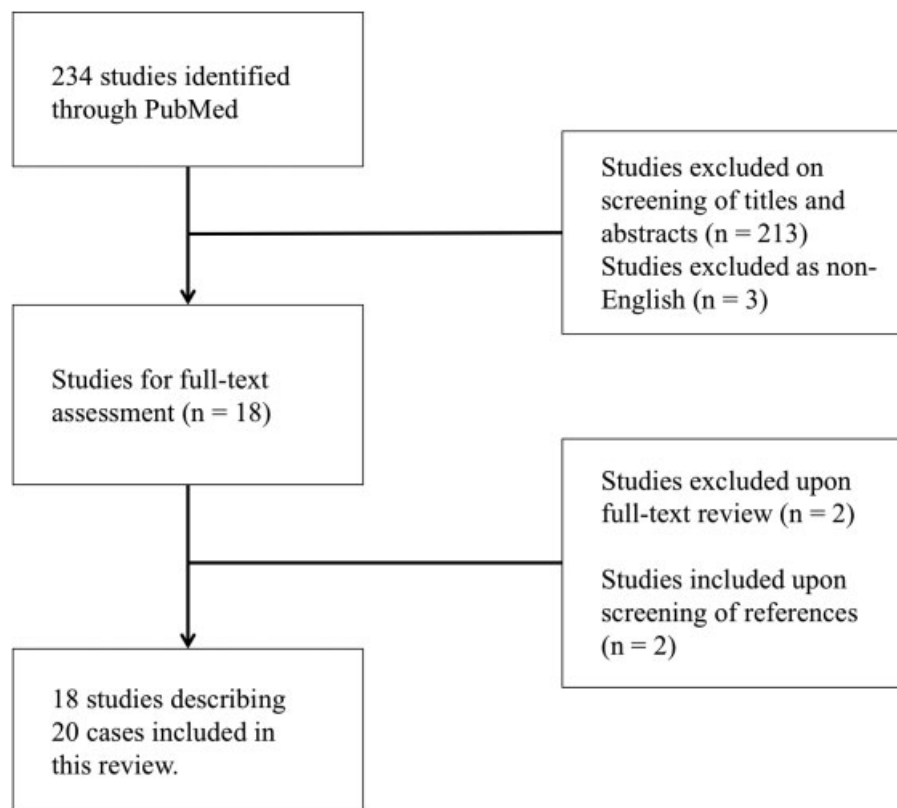
### Clinical Presentation

The demographic profiles of fibrous histiocytomas, summarized in ►Table 1, were markedly different between the benign and malignant tumors. The mean patient age for BFH was 25.8 (range, 8–51) years, whereas MFH appears to affect an older population, with a mean age of 46.6 (range, 0.4–72) years. Additionally, the benign form reportedly had a marked predilection for females, with 80.0% of cases involving female patients versus 40.0% of cases involving female patients in the malignant form.

The cases generally presented as a gradually progressive, painless nodule on the tongue with a firm and/or rubbery, elastic texture. The benign cases demonstrated no overt epithelial disruption. The malignant tumors were slightly larger than the benign ones, with an average diameter of 2.92 cm and 2.48 cm respectively. The malignant cases often presented as gray/white, ulcerated, or fungating lesions ( $n = 8$ ; 53.3%) that may have affected tongue movement ( $n = 2$ ; 13.3%). Single cases reported physiologic effects of the tumor, such as dysphagia, hoarseness, and sore throat. Cervical lymphadenopathy was not reported in any benign or malignant cases. However, constitutional symptoms such as weight loss and fever were reported in single cases. The duration of the symptoms was 3.6 (range, 0–12) months on average for the malignant cases. Benign cases presented later, at 5.0 (range, 2–7) months.

### Workup

Blood chemistry values were rarely reported and otherwise generally unremarkable. Diagnostic imaging studies were reported in two malignant cases, and minimally discussed. The diagnosis was made with histopathologic evaluation in all cases. Tissue was usually procured through excisional or incisional biopsy, though one case employed the use of fine needle aspiration (FNA). Histopathological evaluation was the primary diagnostic modality; the most commonly observed histopathologic features are summarized in ►Table 2. On the histopathologic evaluation (►Fig. 2), BFH lesions were predominantly composed of plump spindle-shaped fibroblasts arranged in a storiform pattern. Scattered histiocytes



**Fig. 1** Systematic search and review strategy of the PubMed database. The initial search returned 234 articles. After screening the titles and abstracts, 18 articles were reviewed in full-text for final inclusion. Of these, two articles were excluded for not meeting the inclusion criteria. Two additional articles were included after screening the references of the included cases. A final group of 18 articles describing 20 cases was included in this review.

were present and demonstrated pale and/or round nuclei, though occasional mitotic figures were present in two cases. The MFH cases exhibited pleomorphic cells that were haphazardly arranged with occasional storiform foci. Mitotic figures were present in the majority of cases ( $n = 8$  of 13, 61.5%). The spindle-shaped fibroblasts cells were reported to have ovoid, elongated nuclei with dense clumped chromatin. The histiocyte-like cells were hyperchromatic with lobulated nuclei and a granular or foamy cytoplasm. Multinucleated giant cells were present in 8 cases (61.5%), and exhibited pleomorphic nuclei.

The immunohistochemistry results (summarized in ► **Table 2**) were reported in 4/5 BFH and in 6/15 MFH cases, and were primarily valuable for diagnostic exclusion. The reported immunostains were as follows:  $\alpha 1$ -antitrypsin,  $\alpha 1$ -antichymotrypsin, CD117, CD31, CD34, CD68, carcinoembryonic antigen (CEA), cytokeratin, desmin, factor VIII, keratin,  $K_i$ -67 protein, Leu7, S100, smooth muscle actin, and vimentin. One to two malignant and benign cases were reported to have  $\alpha 1$ -antitrypsin,  $\alpha 1$ -antichymotrypsin, CD34, CD68, smooth muscle actin, and vimentin immunoreactivity. Benign and malignant cases were both consistently negative for desmin and S100 staining.

### Treatment and Outcome

The treatment and outcomes of the included cases are summarized in ► **Table 3**. All BFHs were treated surgically

with local excision ( $n = 4$ , 80.0%) or CO<sub>2</sub> laser excision ( $n = 1$ , 20%). The single recurrent case, initially excised with CO<sub>2</sub> laser, was treated with subsequent hemiglossectomy. No cases of benign tumors received radiation or chemotherapy. At an average follow-up of 44.6 months, all benign cases were reported to be disease free.

Malignant tumors were primarily treated with surgery. Resection/excision was performed in 4 cases ( $n = 4$ ; 26.7%). Partial or hemiglossectomy was performed in 6 cases ( $n = 6$ ; 40.0%); Total glossectomy was performed in 1 case ( $n = 1$ ; 6.7%). Neck dissection was performed in 4 (26.7%) cases to evaluate the cervical lymph nodes for possible metastasis. Adjuvant radiotherapy was administered in 8 (53.3%) cases, often for recurrent disease or for suspicion of metastasis, with various modalities: iridium or radium implant/brachytherapy, telecobalt therapy, or unspecified external beam radiotherapy, and the results varied. Adjuvant chemotherapy was administered in 4 (26.7%) cases, also often for recurrence or metastasis. Combination chemotherapy regimens included doxorubicin + dacarbazine, actinomycin D + vincristine sulfate + cyclophosphamide, or cyclophosphamide + vincristine + doxorubicin + dacarbazine (CYVADIC). Recurrence occurred in 6 (40.0%) cases. At an average follow-up of 24.1 (range, 9–37) months, 8 (53.3%) cases were disease-free. In 7 (46.6%) cases, the patients succumbed to disease at an average of 19 (range, 9–34) months. All cases are summarized in ► **Table 4**.

**Table 1** Patient Demographics and Clinical Presentation of Fibrous Histiocytoma of the Tongue

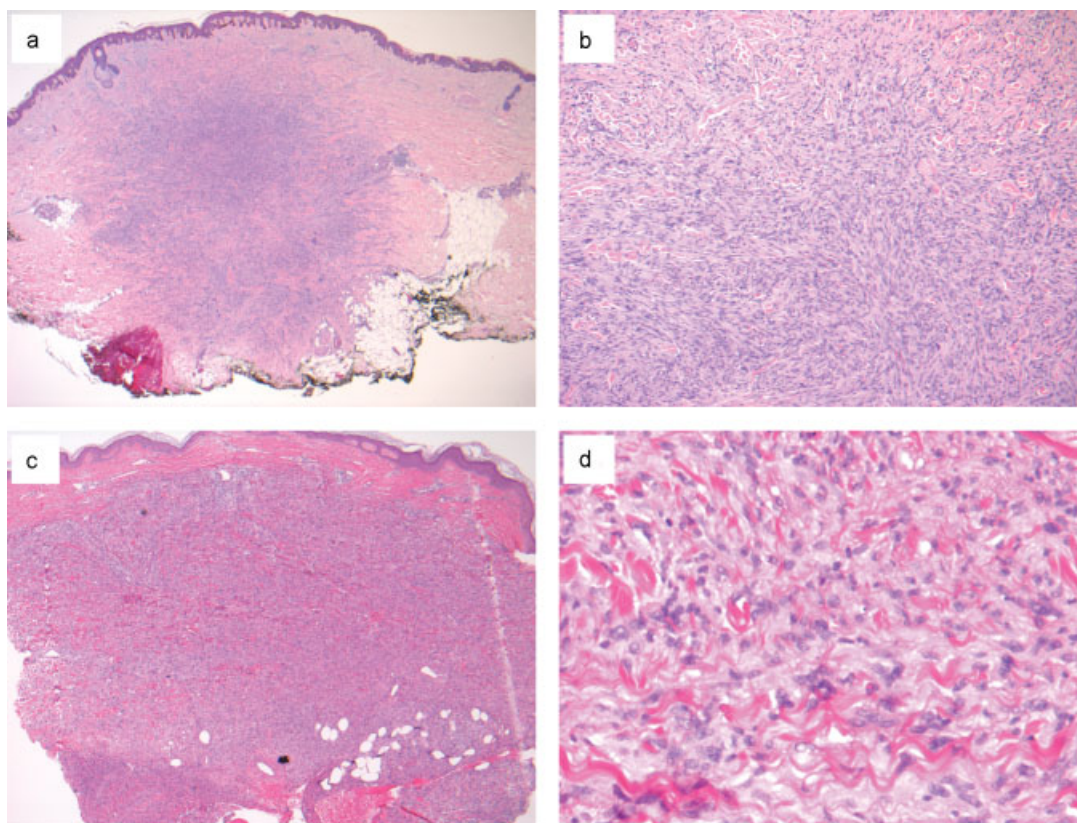
Characteristic	Benign Fibrous Histiocytoma, n (%)	Malignant Fibrous Histiocytoma, n (%)
<b>Demographics</b>		
Mean, range of age (years)	25.8, 8–51	46.6, 0.4–72
Female	4 (80.0)	8 (40.0)
Male	1 (20.0)	9 (60.0)
<b>Presentation</b>		
Mean, range of tumor diameter (cm)	2.5, 0.4–5.5	2.9, 1–5.6
Duration of symptoms (months)	5.0	3.6
Painful*	0 (0.0)	2 (13.3)
Firm*	4 (80.0)	2 (13.3)
Epithelial disruption (gray/white, ulcerated, fungating)*	0 (0.0)	8 (53.3)
<b>Location</b>		
Anterior	1 (20.0)	2 (13.3)
Posterior	0 (0.0)	3 (20.0)
Left lateral	2 (40.0)	6 (40.0)
Right lateral	1 (20.0)	3 (20.0)
Base	1 (20.0)	2 (13.3)
Dorsal	2 (40.0)	3 (20.0)
Ventral	1 (20.0)	0 (0.0)
Unspecified	0 (0.0)	2 (13.3)

Notes: \*Presence/absence of each finding not reported in all cases. Percent is out of total number of cases. Total benign fibrous histiocytoma cases:  $n = 5$ . Total malignant fibrous histiocytoma cases:  $n = 15$ .

**Table 2** Histologic characteristics of fibrous histiocytoma of the tongue

Characteristic	Benign Fibrous Histiocytoma, n (%)	Malignant Fibrous Histiocytoma, n (%)
<b>Histologic finding*</b>		
Pleomorphic	2 (40.0)	8 (61.5)
Mitotic figures	2 (40.0)	8 (61.5)
Storiform pattern	3 (60.0)	10 (76.9)
Spindle, fibroblast-like cells	5 (100.0)	13 (100.0)
Histiocyte-like cells	5 (100.0)	12 (92.3)
Multinucleated giant cells	0 (0.0)	8 (61.5)
<b>Immunohistochemical expression</b>		
$\alpha$ -chymotrypsin	1 (25.0)	2 (33.3)
CD34	2 (50.0)	0 (0.0)
Cytokeratin	0 (0.0)	0 (0.0)
Desmin	0 (0.0)	0 (0.0)
Keratin	0 (0.0)	0 (0.0)
S100	0 (0.0)	0 (0.0)
Vimentin	2 (50.0)	1 (16.7)

Notes: \*Malignant fibrous histiocytoma histologic findings are shown as percent out of 13 cases with available histologic data. †Immunostain not reported in all cases. Percent positivity is out of the total number of cases with immunostain data available.



**Fig. 2** Benign fibrous histiocytoma histology (a-b) showing spindle-shaped fibroblasts arranged in a storiform pattern with scattered histiocytes. Malignant fibrous histiocytoma histology (c-d) demonstrates spindle-shaped to pleomorphic cells haphazardly arranged with occasional mitotic figures (Courtesy of Dr. Paul L. Haun, M.D.).

**Table 3** Treatment and Outcome of Fibrous Histiocytoma of the Tongue

	Benign Fibrous Histiocytoma, n (%)	Malignant Fibrous Histiocytoma, n (%)
<b>Treatment</b>		
Resection/excision	4 (80.0)	4 (26.7)
Partial/hemiglossectomy	1 (20.0)	6 (40.0)
Total glossectomy	0 (0.0)	1 (6.7)
Neck dissection	0 (0.0)	4 (26.7)
Chemotherapy	0 (0.0)	4 (26.7)
Radiotherapy	0 (0.0)	8 (53.3)
CO <sub>2</sub> laser excision/debulking	1 (20.0)	2 (13.3)
<b>Outcomes</b>		
Recurrence	1 (20.0)	6 (40.0)
Disease free	5 (100.0)	8 (53.3)
Death due to the disease	0 (0.0)	7 (46.6)
Mean, range of follow-up (months)	44.6, 1–144	21.7, 9–37

Notes: Percent may add up to more than 100 due to patients receiving multiple treatment modalities. Reported case numbers (n) may add up to more than the total number of cases (BFH = 5; MFH = 15) due to patients receiving multiple treatment modalities.



Table 4 Case data

Article	Age (Years) Ethnicity Gender	Tumor	Size	Chief Complaint	Duration of Symptoms	Prior radiation	Treatment	Results	Follow-up
Chen et al 2001	16-year-old Chinese Female	MFH	2 × 2.5cm	Enlarging painless swelling	5 days	None	Hemiglossectomy with modified radial neck dissection	Negative margins and nodes	Free of disease at 3 years
Geist et al 1990	60-year-old Caucasian Male	MFH in thorax, metastasis to tongue	1.5 × 0.5cm	Progressive weakness and fatigue with painful enlarging mass in tongue	2 months of weakness and fatigue, 1–2 weeks of tongue mass	None	Doxorubicin hydrochloride and DTIC chemotherapy followed by surgical resection with adjuvant radiation for lung persistence and chemo with fludarabine for metastasis	Disease continued to spread	Died of disease. 16 months after presentation
Lin et al 1994	57-year-old Taiwanese Male	MFH	–	Painful mass	1 month	2.5 years ago	Total glossectomy and partial mandibulectomy followed by subtotal excision with palliative chemotherapy for recurrence	Recurred 6 months after primary surgery	Died at 26mo
Lopez et al 2011	8-year-old Caucasian Female	BFH	0.4 × 0.4cm	Asymptomatic nodule noticed by parents	6 months	None	Excision	Clearance	No recurrence at 3 years follow-up
Mahajan et al 1989	28-year-old German Female	MFH	–	Pain and trismus progressing to hoarseness and decreased tongue mobility	7 months	None	Neoadjuvant chemo, modified neck dissection, partial mandibulectomy, partial glossectomy, and pharyngoglossectomy with adjuvant radiotherapy and chemotherapy	Clearance with negative lymph nodes	No recurrence at 15 months
Manni et al 1986	61-year-old Caucasian Male	MFH	9 × 5 × 3cm	Progressive tongue swelling, bleeding, and swallowing difficulties	6 months	None	Hemiglossectomy with supraomohyoid neck dissection		No recurrence at 2 years
McMillan et al 1986	42-year-old Female	MFH	2.5cm	Enlarging symptomless swelling	8 weeks	None	Excisional biopsy followed by left hemiglossectomy after histologic diagnosis		No recurrence at 9 months
Pandey et al 2013	26-year-old Indian Male	BFH	6 × 5cm	Slow growing mass	5 months	None	Excision and blunt dissection		Disease-free at 1 month f/u
Priya et al 2013	30-year-old Indian Female	BFH	3 × 3cm	Nodular mass causing speech difficulty	7 months	None	Excision under local anesthesia	Tongue function improvement	No recurrence at 3 years
Rapidis et al 2005	24-year-old Caucasian Male	MFH	3 × 2 × 1cm	Slowly enlarging painless swelling	5 months	None	Surgical resection with 1 cm tumor-free margins		Disease-free at 18 months
Restrepo et al 1987	5-month-old Caucasian Male	MFH	–	Difficulty bottle feeding	–	None	Partial glossectomy with adjuvant iridium implants and 2 years of actinomycin D, vincristine sulfate, cyclophosphamide chemo	Unremarkable metastatic workup	Disease free at 18 months after diagnosis (7 months after therapy completion)
Velez et al 1986	14-year-old African American Female	Atypical FH	3.2 × 2 × 0.7cm	Rapidly growing non-tender mass	2 weeks	None	Excised with CO <sub>2</sub> laser under general anesthesia followed by hemiglossectomy after recurrence	Local recurrence within several weeks. Tumor-free margins on hemiglossectomy	Patient died 6 months later due to Cystic Fibrosis

(Continued)

Table 4 (Continued)

Article	Age (years) Ethnicity Gender	Tumor	Size	Chief Complaint	Duration of Symptoms	Prior radiation	Treatment	Results	Follow-up
Takimoto et al 1990	51-year-old Japanese Female	FH	2 × 1.5 × 1cm	Sore throat with globus sensation	"several months"	None	Elliptical excision with 5 mm margins		Asymptomatic with no evidence of recurrence at 12 years
Young et al 1989	67-year-old Taiwanese Female	MFH	—	Rapidly growing protruding mass	—	5 years ago	Tumor debulking by CO2 laser followed by excision with tongue flap push back reconstruction and adjuvant radiation for recurrence		No evidence of recurrence at 3 years after excision
Young et al 1989	52-year-old Taiwanese Male	MFH	—	Globus sensation	—	12 years ago	Tumor debulking by CO2 laser	Neck metastasis found 1 month after debulking	Died of disease 16 months after diagnosis
Zapater et al 1995	71-year-old Caucasian Male	MFH	4 × 2cm	Painful gum mass	3 months	None	Telecobaltherapy of the tongue and oral cavity and then curietherapy on the primary lesion	No evidence of tumor macroscopically	Recurrence at 8 months, patient died of disease one month later
Bras et al 1987	72-year-old Caucasian Male	MFH	—	Painless swelling	3 months	—	Radium implants initially followed by local surgery and modified radical neck dissection for recurrence	Partial response, recurrence	Died of disease after 12 months
Bras et al 1987	65-year-old Caucasian Male	MFH	—	Found on follow-up from prior irradiation for SCC of the tongue	—	10 years ago	Initial resection followed by surgery for local recurrence and radiotherapy + CYVA-DIC chemo for lung metastasis		Died of disease after 20 months
Barnes et al 1988	21-year-old Female	MFH	3cm	Asymptomatic mass	12 months	None	Partial right glossectomy with right modified radical neck dissection	Negative lymph nodes	No evidence of disease at 37 months
Hiasa et al 1986	63-year-old Japanese Female	Right pleural MFH metastasis to the tongue and other organs	5 × 4 × 3cm	Swelling of the right edge of the tongue	—	1 year ago	Partial resection with adjuvant radiation to primary tumor. Followed by radiation to metastases		Died of disease at 34 months

Abbreviations: BFH benign fibrous histiocytoma; CYVADIC, cyclophosphamide + vincristine + doxorubicin + dacarbazine; DTIC, dacarbazine; FH, fibrous histiocytoma; MFH, malignant fibrous histiocytoma; SCC, squamous cell carcinoma.  
Note: - = not reported.

## Discussion

Benign fibrous histiocytomas of the tongue are consistent in clinical presentation and course. The mean patient age is 25.8 years, with 80% of cases affecting females. The cases presented as painless, gradually growing, firm masses. Surgical excision of benign lesions demonstrated excellent prognosis. The single case using CO<sub>2</sub> laser required subsequent hemiglossectomy due to recurrence. In early oral cancers, this modality is potentially an effective and functionally advantageous approach to therapy.<sup>30</sup> However, in the case of BFH of the tongue, incomplete resection, and thus subsequent recurrence, is of concern. Further study is warranted to validate the efficacy of the CO<sub>2</sub> laser as monotherapy for BFH of the tongue. This modality could also have use in tumor debulking, or may be indicated for smaller lesions.

Accurate histopathological diagnosis of these tumors is critical, considering the large differences in treatment and outcome, based on tumor pathology and, subsequently, malignant potential. The differential diagnosis for BFH and MFH is broad, and includes the following: fibroma, fibrosarcoma, dermatofibrosarcoma protuberans, neurofibroma, Kaposi sarcoma, among others.

Considering the high innervation, functional importance, and cosmetically sensitive nature of the tongue, tissue-preserving technique could be considered for excision of tumors in this location. Mohs micrographic surgery techniques may be of interest for BFH or MFH of the tongue. A case series of Mohs surgical excision of squamous cell carcinomas affecting the tongue demonstrated promising results, with no recurrence evident at a follow-up of 12–34 months.<sup>31</sup> If appropriate, application of this technique could reduce the need for disfiguring glossectomies. Further evaluation of its efficacy is warranted.

The current World Health Organization guidelines for tumors historically called MFH now classifies them as undifferentiated pleomorphic sarcoma. Tumors should be classified as such only after all recognizable lines of differentiation have been excluded.<sup>32</sup> The nomenclature of MFH subtypes was also changed to the following: storiform-pleomorphic MFH/undifferentiated high-grade pleomorphic sarcoma, giant cell MFH/undifferentiated pleomorphic sarcoma with giant cells, and inflammatory MFH/undifferentiated pleomorphic sarcoma with prominent inflammation. These 3 subtypes remained within the “so-called fibrohistiocytic tumors” category, while myxoid MFH/myxofibrosarcoma, now a separate entity, has been moved to the myofibroblastic tumor category.<sup>2</sup>

## Final Comments

The present review of the available literature returned 5 cases of BFH and 15 cases of MFH. The BFH cases demonstrated an apparent predilection for female (80.0% versus 40.0% in MFH) and younger (25.8 versus 46.6 in MFH) patients than MFH. The benign cases presented as a slowly growing, asymptomatic nodule with a firm, rubbery and elastic texture. The lesions were diagnosed by histopathologic evaluation with immunostaining used primarily for diagnostic exclusion. Of the BFH cases treated with first-line surgical excision, no recurrences

were reported, whereas the case treated with initial CO<sub>2</sub> laser required subsequent hemiglossectomy for tumor recurrence.

Malignant tumors presented as gray/white, ulcerated, fungating lesions with an average diameter of 2.92 cm. A minority of cases reported physiologic effects of the tumor, including affected tongue motility, dysphagia, hoarseness, and sore throat. The histopathologic workup demonstrated pleomorphic cells with occasional storiform patterns. Mitotic figures were present, with a mix of spindle-shaped fibroblast-like cells, histiocyte-like cells, and multinucleated giant cells. The surgical treatment is first-line, and adjuvant radiotherapy may be considered. Combination chemotherapy regimens vary. Recurrence occurred in 40.0% of cases (follow-up of 24.1 months), with death due to disease in 46.6% of patients (follow-up of 19.0 months).

### Conflicts of Interest

No conflicts of interest to disclose.

### Funding Sources

No funding obtained.

## References

- 1 LeBoit PE, Burg G, Weedon D, Sarasin A. World Health Organization Classification of Tumours. Pathology and Genetics. Skin Tumours Lyon: IARC Press; 2006
- 2 Fletcher CDM, Unni KK. World Health Organization Classification of Tumours Pathology and Genetics of Tumours of Soft Tissue and Bone. Cancer 2002;177:1365–76
- 3 Fletcher CD. Benign fibrous histiocytoma of subcutaneous and deep soft tissue: a clinicopathologic analysis of 21 cases. Am J Surg Pathol 1990;14(09):801–809
- 4 O'Brien JE, Stout AP. MALIGNANT FIBROUS XANTHOMAS. Cancer 1964;17:1445–1455
- 5 Toro JR, Travis LB, Wu HJ, Zhu K, Fletcher CDM, Devesa SS. Incidence patterns of soft tissue sarcomas, regardless of primary site, in the surveillance, epidemiology and end results program, 1978–2001: An analysis of 26,758 cases. Int J Cancer 2006;119(12):2922–2930
- 6 Marcet S. Atypical fibroxanthoma/malignant fibrous histiocytoma. Dermatol Ther (Heidelb) 2008;21(06):424–427
- 7 Xi M, Liu MZ, Wang H-X, et al. Radiation-induced sarcoma in patients with nasopharyngeal carcinoma: a single-institution study. Cancer 2010;116(23):5479–5486
- 8 Henderson MT, Hollmig ST. Malignant fibrous histiocytoma: changing perceptions and management challenges. J Am Acad Dermatol 2012;67(06):1335–1341
- 9 Sabesan T, Xuexi W, Yongfa Q, Pingzhang T, Ilankovan V. Malignant fibrous histiocytoma: outcome of tumours in the head and neck compared with those in the trunk and extremities. Br J Oral Maxillofac Surg 2006;44(03):209–212
- 10 Nascimento AF, Raut CP. Diagnosis and management of pleomorphic sarcomas (so-called “MFH”) in adults. J Surg Oncol 2008; 97(04):330–339
- 11 von Mehren M, Benjamin RS, Bui MM, et al. Soft tissue sarcoma, version 2.2012: featured updates to the NCCN guidelines. J Natl Compr Canc Netw 2012;10(08):951–960
- 12 Manni JJ, van den Broek P, van Haelst UJ, Slooff JP, Bruaset I. Malignant fibrous histiocytoma of the tongue. J Maxillofac Surg 1986;14(02):103–107



- 13 Priya NS, Rao K, Umadevi HS, Smitha T. Benign fibrous histiocytoma of the tongue. *Indian J Dent Res* 2013;24(05):635–638
- 14 Chen YK, Lin LM, Lin CC. Malignant fibrous histiocytoma of the tongue. *J Laryngol Otol* 2001;115(09):763–765
- 15 Geist J, Azzopardi M, Domanowski A, Plezia R, Venkat H. Thoracic malignant fibrous histiocytoma metastatic to the tongue and skin of the face. *Oral Surg Oral Med Oral Pathol* 1990;69(02):199–204
- 16 Lin SK, How SW, Wang JT, Liu BY, Chiang CP. Oral post-radiation malignant fibrous histiocytoma: a clinicopathological study. *J Oral Pathol Med* 1994;23(07):324–329
- 17 Mahajan H, Kim EE, Lee YY, Goepfert H. Malignant fibrous histiocytoma of the tongue demonstrated by magnetic resonance imaging. *Otolaryngol Head Neck Surg* 1989;101(06):704–706
- 18 McMillan MD, Smillie AC, Ferguson JW. Malignant fibrous histiocytoma of the tongue: report of a case and ultrastructural observations. *J Oral Pathol* 1986;15(05):255–260
- 19 Rapidis AD, Andressakis DD, Lagogiannis GA, Douzinas EE. Malignant fibrous histiocytoma of the tongue: review of the literature and report of a case. *J Oral Maxillofac Surg* 2005;63(04):546–550
- 20 Restrepo JP, Handler SD, Saull SC, Raney RB Jr. Malignant fibrous histiocytoma. *Otolaryngol Head Neck Surg* 1987;96(04):362–365
- 21 Young YH, Hsieh T. Malignant fibrous histiocytoma of the head and neck: report of 5 cases. *Taiwan Yi Xue Hui Za Zhi* 1989;88(06):606–609
- 22 Hiasa Y, Shimoyama T, Kitahori Y, et al. Malignant fibrous histiocytoma with widespread metastasis and pulmonary cancer. *Acta Pathol Jpn* 1986;36(01):113–122
- 23 Zapater E, Bagán JV, Campos A, Martorell M, Basterra J. Malignant fibrous histiocytoma of the head and neck. Case report. *Bull Group Int Rech Sci Stomatol Odontol* 1995;38(3–4):121–124
- 24 Bras J, Batsakis JG, Luna MA. Malignant fibrous histiocytoma of the oral soft tissues. *Oral Surg Oral Med Oral Pathol* 1987;64(01):57–67
- 25 Barnes L, Kanbour A. Malignant fibrous histiocytoma of the head and neck. A report of 12 cases. *Arch Otolaryngol Head Neck Surg* 1988;114(10):1149–1156
- 26 López-Jornet P, Camacho-Alonso F, Gómez-García FJ. Oral lesion on dorsum of tongue. *J Can Dent Assoc* 2011;77:b117
- 27 Pandey NK, Sharma SK, Banerjee S. A rare case of fibrous histiocytic tumor of the tongue. *Indian J Surg* 2013;75(01, Suppl 1):1–5
- 28 Velez-Torres R, Owen LG, Hodge SJ, McMurray GT, Roe E. Atypical fibrous histiocytoma of the tongue. A case report. *Int J Dermatol* 1986;25(10):656–657
- 29 Takimoto T, Ishikawa S, Umeda R. Fibrous histiocytoma of the tongue base. *Auris Nasus Larynx* 1990;16(04):233–236
- 30 Goodson ML, Thomson PJ. Management of oral carcinoma: benefits of early precancerous intervention. *Br J Oral Maxillofac Surg* 2011;49(02):88–91
- 31 Gauthier P, Audet N, Guertin L, et al. Complete frozen section margins (with measurable 1 or 5 mm thick free margin) for cancer of the tongue: part 2: clinical experience. *J Otolaryngol Head Neck Surg* 2010;39(01):20–27
- 32 Jo VY, Fletcher CDM. WHO classification of soft tissue tumours: an update based on the 2013 (4th) edition. *Pathology* 2014;46(02):95–104