

Lingual thyroid gland: it's time for awareness

Nicolás Cruz-Dardíz¹, Nadyeschka Rivera-Santana¹, Marina Torres-Torres²,
Héctor Cintrón-Colón², Shayanne Lajud³, Ernesto Solá-Sánchez¹,
Michelle Mangual-García¹ and Alex González-Bóssolo¹

¹Endocrinology Department, ²Internal Medicine Department, San Juan City Hospital, San Juan, Puerto Rico, and
³Otolaryngology Head and Neck Surgery, University of Puerto Rico, Medical Science Campus, San Juan, Puerto Rico

Correspondence
should be addressed
to N Cruz-Dardíz
Email
nicocruz85@hotmail.com

Summary

Lingual thyroid (LT) gland is the most common type of ectopic thyroid tissue, but it is an extremely rare presentation. We present a case of a 41-year-old Hispanic female patient complaining of dysphonia and dysphagia. As part of the evaluation, fiber optic flexible indirect laryngoscopy (FIL) was performed which revealed a mass at the base of the tongue. The morphological examination was highly suspicious for ectopic thyroid tissue and the diagnosis was confirmed with neck ultrasound and thyroid scintigraphy. Although the patient presented subclinical hypothyroidism, levothyroxine therapy was initiated with a favorable response which included resolution of symptoms and mass size reduction. Our case portrays how thyroid hormone replacement therapy (THRT) may lead to a reduction in the size of the ectopic tissue and improvement of symptoms, thus avoiding the need for surgical intervention which could result in profound hypothyroidism severely affecting the patients' quality of life.

Learning points:

- Benign LT and malignant LT are indistinguishable clinically and radiographically for which histopathology is recommended.
- THRT, radioactive iodine 131 (RAI) therapy, and surgical excision are potential management options for LT.
- THRT may lead to size reduction of the ectopic tissue and resolution of symptoms avoiding surgical intervention.

Background

The thyroid gland is the first endocrine gland to develop, occurring around the 24th day of gestation (1). Studies have determined that gene transcription factors NKX2-1, FOXE1, and PAX-8 are crucial for thyroid morphogenesis and differentiation for which it is presumed that mutation in these genes leads to abnormal thyroid migration (1, 2). Among ectopic thyroid tissue, LT accounts for the majority of cases, resulting in thyroid gland migration aberrancy from the foramen caecum to its final pre-tracheal position (3). The prevalence is approximately 1 per 100 000–300 000 patients and it is found with higher frequency in females (1, 4). LT carcinoma is a very uncommon entity, as reported by Massine *et al.*, and fewer than 30 cases have been reported in the literature (5). Here, we display a

case of an asymptomatic patient with sublingual thyroid gland and subclinical hypothyroidism that was managed with THRT.

Case presentation

This is the case of a 41-year-old Hispanic female, without a prior medical condition that presented to the Otolaryngology-Head and Neck Surgery clinics complaining of dysphonia and dysphagia of 3 weeks of evolution. The patient denied other constitutional signs or symptoms suggestive of thyroid dysfunction. Family history was noncontributory. Surgical history was remarkable for tonsillectomy. Physical examination

showed a mass at the base of the tongue and no palpable thyroid tissue at the anterior neck. FIL was performed, remarkable for an inflamed and vascular mass at the base of the tongue highly suspicious for ectopic thyroid tissue (Figs 1 and 2). A neck CT scan with IV contrast (Fig. 3) showed a hyperdense lesion at the base of the tongue measuring 2.6×1.9 cm on the axial plane exerting some mass effect at the valleculae, thus raising suspicion of ectopic thyroid tissue. Neck and thyroid ultrasound were distinctive for absent thyroid tissue at the expected anatomic position. Thyroid scan was performed with radioactive iodine 131 (RAI), which failed to identify functional thyroid tissue at the expected anatomical location and found an area of focal increased uptake on the superior lingual region (Fig. 4). The patient was referred to Endocrinology clinics for further evaluation. Laboratories during the initial evaluation were significant for TSH at 6.3 mIU/L, total T4: 6.89 mIU/L and negative TPO antibodies, consistent with subclinical hypothyroidism. Fine needle aspiration (FNA) cytology was performed revealing follicular like cells in sheets with thick colloid material and abundant squamous cells, without any malignant process. To exclude extrathoracic obstruction, a pulmonary function test was performed which resulted in normal spirometry.

Investigation

- TSH of 6.3 mIU/L (0.358–3.74 mIU/L)
- Total T4: 6.89 μ g/dL (5.2–12.5 μ g/dL)
- TPO antibody: 0.32 IU/mL (<2.0 IU/mL)
- Neck CT scan: Hyperdense lesion at the base of the tongue measuring 2.6×1.9 cm on the axial plane. Thyroid gland not visualized.
- Thyroid ultrasound: No thyroid tissue identified in the scanned sections of the neck. Normal lymph nodes, no necrotic or calcified lymphadenopathy.

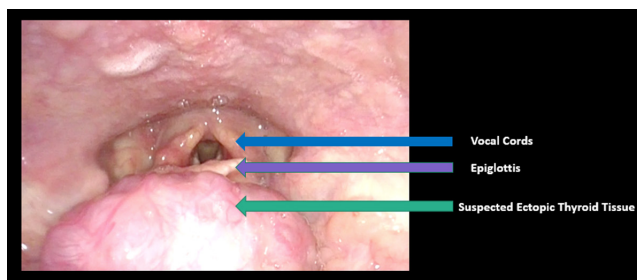


Figure 1
FIL showing evidence of an inflamed and vascular ectopic thyroid tissue at the base of the tongue.

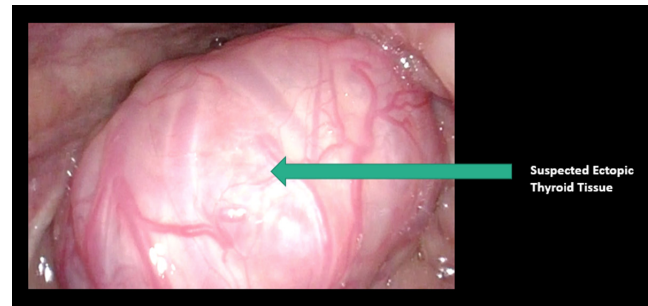


Figure 2
FIL showing evidence of an inflamed and vascular ectopic thyroid tissue at the base of the tongue.

- Thyroid scan: Scintigraphic evidence of sublingual thyroid gland
- Sublingual thyroid FNAB: Negative for malignancy
- Spirometry test: Normal spirometry

Treatment

Upon initial Endocrinology clinic evaluation, the patient was diagnosed with subclinical hypothyroidism not requiring total hormone replacement therapy (THRT). At follow-up visit 3 months later, new laboratories were remarkable for TSH at 9.60 mIU/L and Free T4 at 0.9 mIU/L (0.76–1.46 ng/dL). Given continued symptoms and increasing TSH, the patient was started on THRT, levothyroxine 50 μ g oral daily. Subsequently, dose titration was performed according to laboratories and clinical findings. After 5 months of THRT, there was

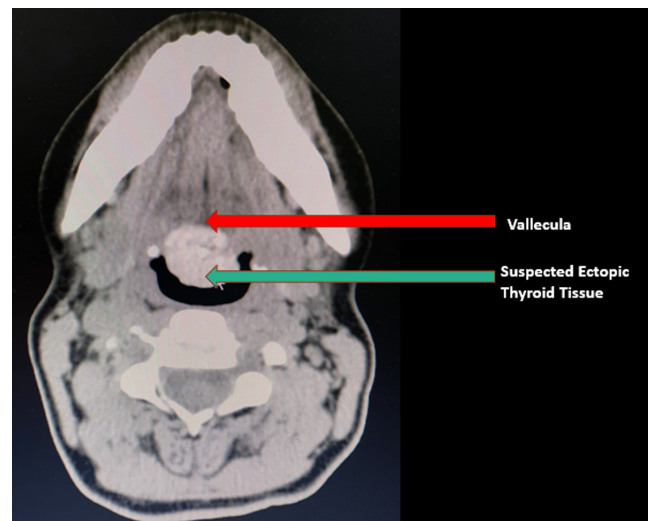


Figure 3
CT Scan of neck with IV contrast prior THRT. Note hyperdense lesion at the base of the tongue measuring 2.6×1.9 cm on the axial plane. Lesion is exerting some mass effect at the vallecula.

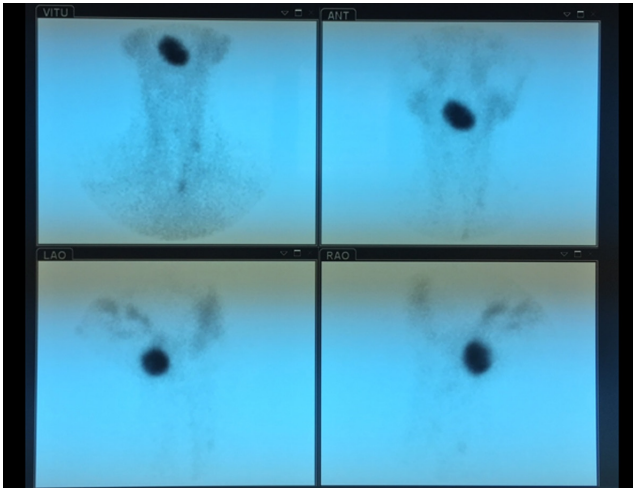


Figure 4
Thyroid uptake scan performed with RAI. Radioiodine evidence of a large area of focal increased uptake on the superior lingual region.

complete resolution of symptoms and TSH was 1.2 mIU/dL, within the established target range. Currently, she continues on levothyroxine 75 µg oral daily.

Outcome and follow-up

The patient has been closely followed-up since her initial presentation by an interdisciplinary group of physicians including otolaryngology, endocrinology, and pulmonary medicine. The patient's symptoms of dysphonia and dysphagia resolved after THRT. She has remained clinically and chemically euthyroid. Neck CT scan with IV contrast (Fig. 5) was repeated 8 months after initiating

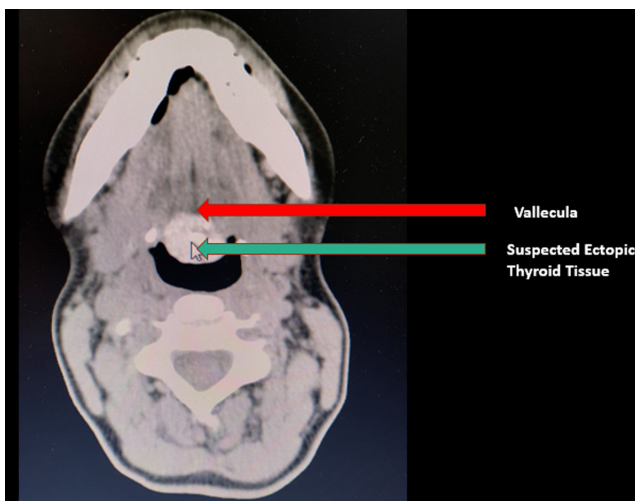


Figure 5
CT Scan of neck with IV contrast after THRT. Hyperdense lesion at the base of the tongue measuring 2.0 × 1.5 cm on the axial plane.

THRT. Although there was a persistence of the hyperdense mass at the base of the tongue, a size decrease of about 25% was noted (2.0 × 1.5 cm) leading to the resolution of the documented mass effect.

Discussion

As mentioned, LT is an uncommon entity. The majority of cases are asymptomatic and when symptoms occur these are often determined by mass size. Studies have determined that clinical manifestations peak at a mean age of 40 years (1) as is seen in our case. Common symptoms include fullness sensation, dysphagia, dyspnea, dysphonia, and hemorrhage (6). There have been reports of patients with LT that present with complications of respiratory tract obstruction and obstructive sleep apnea (OSA) (1, 7). Barnes *et al.* documented a case of a 49-year-old nonobese female with severe OSA caused by large LT which required surgical resection (7). A multidisciplinary approach should be considered during the evaluation.

In cases of suspected ectopic thyroid tissue, thyroid function test should be performed. As pointed out by Ibrahim, 70% of patients with LT without co-existing ectopic thyroid tissue will develop subclinical hypothyroidism (1) as it was seen in our patient. The cause of subclinical hypothyroidism in this patient is indeterminate but could be explained by an aberrant migratory pathway, location, and possible inadequate blood supply of the rudimentary thyroid gland, which may impair normal thyroid function. In these cases, the secreted amount of thyroid hormone may not be enough during periods of increase in hormone demand.

RAI is among the most important diagnostic techniques used in the recognition of ectopic thyroid tissue, as it determines its localization and it helps determine if there is any co-existing ectopic thyroid gland (1, 8). As detailed by Yoon *et al.*, it is noteworthy to identify if there is other functioning thyroid tissue before resection of ectopic tissue (4). Among imaging tools that aid in the diagnosis of ectopic thyroid, ultrasound is favored during initial assessment given that it is non-invasive, cost-effective, and safe as well as aids in the localization of ectopic tissue (1). FNA cytology is part of the diagnostic approach. As reported by Massine *et al.*, benign LT and LT carcinoma present in identical fashion clinically and radiographically for which biopsy is indispensable (5).

THRT, RAI, and surgical excision are different treatment modalities available for LT. The treatment of choice should be guided by symptoms, size, thyroid function status, and histological findings (1). Management with THRT has been



associated with ectopic tissue size reduction (6). It has also been proposed that, in asymptomatic euthyroid patients, THRT should be considered to prevent hypothyroid state and progressive growth (1, 9, 10). Our patient was managed with levothyroxine despite presenting with subclinical hypothyroidism. This conservative management led to ectopic tissue size reduction, as well as the complete resolution of symptoms. In patients that do not respond to THRT, other treatment modalities may be considered. Surgical intervention is indicated when the patient presents with severe respiratory tract obstruction, limited size-reduction despite THRT, bleeding, ulceration, or malignancy (1, 3, 4, 9). In contrast, RAI may be considered for patients who are not surgical candidates (1, 9). Further research regarding evaluation, monitoring, and follow-up of ectopic thyroid tissue is necessary for better assessment of possible malignant transformation.

Our case portrays how conservative management with THRT resulted in significant size reduction of the ectopic tissue as well as resolution symptoms, thus avoiding surgical intervention, which could potentially lead to profound hypothyroidism, severely affecting patients' quality of life.

Declaration of interest

The authors declare that there is no conflict of interest that could be perceived as prejudicing the impartiality of this case report.

Funding

This case report did not receive any specific grant from any funding agency in the public, commercial, or not-for-profit sector.

Patient consent

A written consent was obtained from the patient for case publication.

Author contribution statement

Drs Cruz-Dardíz, Rivera-Santana, Torres-Torres, and Cintrón-Colón were involved in articles review, manuscript writing, and revision. Dr Lajud was involved in patient care and article reviews. Drs Solá-Sánchez, Mangual-García, and González-Bóssolo are endocrinologists who were involved in patient care and manuscript revision.

References

- 1 Ibrahim NA & Fadeyibi IO. Ectopic thyroid: etiology, pathology and management. *Hormones* 2011 **10** 261–269. (<https://doi.org/10.14310/horm.2002.1317>)
- 2 De Felice M & Di Lauro R. Thyroid development and its disorders: genetics and molecular mechanisms. *Endocrine Reviews* 2004 **25** 722–746. (<https://doi.org/10.1210/er.2003-0028>)
- 3 Cappelli C, Gandossi E, Cumetti D, Castellano M, Pirola I, De Martino E, Agosti B, Micheletti L, Cherubini L, Mattanza C, *et al.* Ectopic lingual thyroid tissue and acquired hypothyroidism: case report. *Annales d'Endocrinologie* 2006 **67** 245–248. ([https://doi.org/10.1016/s0003-4266\(06\)72593-8](https://doi.org/10.1016/s0003-4266(06)72593-8))
- 4 Yoon JS, Won KC, Cho IH, Lee JT & Lee HW. Clinical characteristics of ectopic thyroid in Korea. *Thyroid* 2007 **17** 1117–1121. (<https://doi.org/10.1089/thy.2007.0004>)
- 5 Massine RE, During SJ & Koroscil TM. Lingual thyroid carcinoma: a case report and review of the literature. *Thyroid* 2001 **11** 1191–1196. (<https://doi.org/10.1089/10507250152741055>)
- 6 Elprana D, Manni JJ & Smals AGH. Lingual thyroid: case report and review of literature. *Journal for Oto-Rhino-Laryngology and its Related Specialties* 1984 **46** 147–152. (<https://doi.org/10.1159/000275700>)
- 7 Barnes TW, Olsen KD & Morgenthaler TL. Obstructive lingual thyroid causing sleep apnea: a case report and review of literature. *Sleep Medicine* 2004 **5** 605–607. (<https://doi.org/10.1016/j.sleep.2004.06.005>)
- 8 Kumar LK, Kurien NM, Jacob MM, Menon PV & Kham SA. Lingual thyroid. *Annals of Maxillofacial Surgery* 2015 **5** 104–107. (<https://doi.org/10.4103/2231-0746.161103>)
- 9 Rahbar R, Yoon MJ, Connolly LP, Robson CD, Vargas SO, McGill TJ & Healy GB. Lingual thyroid in children: a rare clinical entity. *Laryngoscope* 2008 **118** 1174–1179. (<https://doi.org/10.1097/MLG.0b013e31816f6922>)
- 10 Kansal P, Sakati N, Rifai A & Woodhouse N. Lingual thyroid diagnosis and treatment. *Archives of Internal Medicine* 1987 **147** 2046–2048. (<https://doi.org/10.1001/archinte.1987.00370110174028>)

Received in final form 2 March 2020

Accepted 28 April 2020