

Primary peritoneal carcinoma presenting as a case of ascites

Ajay K. Jha¹, Ashok Sunder¹, Shweta Kumari², Keertee Dubey¹

¹Department of Medicine, Tata Main Hospital, Jamshedpur, Jharkhand, ²Department of Obst. and Gynaecology, Medica Superspeciality Hospital, Jamshedpur, Jharkhand, India

ABSTRACT

Primary peritoneal carcinoma (PPC) was first described in 1959 by Swerdlow. It is a rare malignant tumor of the peritoneal cavity. Clinically and histologically it is similar to advanced-stage serous ovarian carcinoma that develops from the peritoneum lining the pelvis and abdomen and is characterized by abdominal carcinomatosis, uninvolved or minimally involved ovaries, and no identifiable primary tumor. This cancer spreads widely inside the peritoneal cavity and mostly involves the omentum. There is some thought that the peritoneal cells that give rise to peritoneal cancer may actually be leftover ovarian cells that remained in the abdomen during development. It is almost exclusively found in women. Clinical features include abdominal swelling, constipation, gastrointestinal disorders, nausea, vomiting, anorexia, and weight loss.

Keywords: Abdominal carcinomatosis, Immunohistochemistry, Primary peritoneal carcinoma

Case Study

A 60-year-old postmenopausal woman P₄L₄ was first seen outside the hospital with complaints of abdominal distension, pain, and vomiting which had gradually increased over the past 1 month and was associated with dysphagia to solid food. She was a diagnosed case of Type II diabetes mellitus and hypertension. On admission, she had marked pallor and bilateral pedal edema. Her random blood glucose in emergency department was 38 mg/dl which was immediately corrected. Her Pulse rate was 90 bpm, blood pressure 110/70 mm of Hg, spO₂ 96% on ambient air and respiratory rate 18 per minute. Examination of respiratory system revealed bilateral decreased breath sound in both infrascapular regions. Her abdominal examination showed ascites. Examinations of other system were normal. She was

diagnosed outside the hospital as abdominal tuberculosis and anti-tubercular therapy was started. However the patient was not able to tolerate the drugs and stopped it before being admitted to our hospital. Her blood investigations revealed Hb- 11.1 gram/dl, TLC 8000, platelets count - 198000, Serum sodium- 134 meq/l, Serum potassium- 4.6 meq/l, Serum protein- 5.3 gram/dl, Serum albumin- 2.65 gram/dl, Serum creatinine- 0.67. Her ascitic fluid was blood mixed. Ascitic fluid analysis showed total WBC: 634, polymorphs: 25, lymphocytes: 55, others: 20, ascitic fluid protein: 4.68, albumin: 2.53, adenosine deaminase: 14.9, glucose: 26, LDH: 1437.3, lymphocytes 60%. Ascitic fluid for TB-PCR was negative. Abdominal Ultrasound documented gross ascitis with bilateral pleural effusion and few foci of splenic parenchymal calcification. Both her ovaries were normal. Her CA-125 was elevated (5121 U/ml), CEA- 2.92 ng/ml, LDH- 373.3 and HbsAg, HIV and anti-HCV were negative. Her chest X-ray showed bilateral pleural effusion. Her upper gastrointestinal endoscopy revealed mild antral gastritis. Her ascitic fluid, cell block sent for malignant cell examination which revealed cytological features suggestive of adenocarcinoma [Figure 1]. Her CECT whole

Address for correspondence: Dr. Ajay K. Jha, Consultant, Department of Medicine, Tata Main Hospital, Northern Town, Jamshedpur - 831 001, Jharkhand, India.
E-mail: ajajha107@gmail.com

Received: 20-04-2020

Revised: 10-06-2020

Accepted: 01-07-2020

Published: 30-10-2020

Access this article online

Quick Response Code:



Website:
www.jfmpc.com

DOI:
10.4103/jfmpc.jfmpc_644_20

This is an open access journal, and articles are distributed under the terms of the Creative Commons Attribution-NonCommercial-ShareAlike 4.0 License, which allows others to remix, tweak, and build upon the work non-commercially, as long as appropriate credit is given and the new creations are licensed under the identical terms.

For reprints contact: WKHLRPMedknow_reprints@wolterskluwer.com

How to cite this article: Jha AK, Sunder A, Kumari S, Dubey K. Primary peritoneal carcinoma presenting as a case of ascites. J Family Med Prim Care 2020;9:5372-4.

abdomen showed exudative ascitis with no obvious mass lesion in adenexa. Her CECT thorax documented moderate bilateral pleural effusion with subsegmental collapse of basal segments. Her immunohistochemistry report of cell block showed WT-1 immunoreactive, score 3+ in atypical cells [Figure 2], Ber-EP4 immunoreactive, Score 4+ in atypical cells, PAX-8 Immunoreactive, Score 4+ in atypical cells, Claudin-4 immunoreactive, Score 4+ in atypical cells. Calretinin and SAT-B2 were non-immunoreactive. So the diagnosis was revised to Primary Peritoneal Carcinoma. Chemotherapy cycle 1 was advised as per the protocol. However, her condition deteriorated (persistent hypotension even after starting ionotropes) and she succumbed to her illness eventually. So for an untrained eye it is very difficult to diagnose a PPC. Only the trained eye can clinch the diagnosis using ascitic fluid cell block and the immunohistochemistry reports.

Discussion

A PPC is referred to by many names including an extra-ovarian primary peritoneal carcinoma (EOPPC), primary peritoneal serous carcinoma, Serous surface papillary carcinomamesothelioma, papillary carcinoma of the peritoneum, serous surface papillary carcinoma, and extraovarian papillary serous carcinoma; these names reflect a debate on the histogenesis and clinical behavior of the tumor. PPC is occurring in only around 6.78 cases per 1,000,000 individuals^[1] Histologically, it is indistinguishable from primary epithelial ovarian carcinoma and is diagnosed in the absence of other identifiable primary sites.^[2] People who are diagnosed with PPC tend to be older than those with ovarian cancer.^[3] Surgical exploration provides a diagnosis, staging evaluation, and treatment of patients with PPC. Histopathological and cytological characteristics of the tumor are predominantly the serous type.^[4] The treatment of a PPC is based on cytoreductive surgery and platinum based

chemotherapy. Optimal cytoreduction is the primary goal of the surgical procedure. Excision of all visible implants is the hallmark of the cytoreductive surgery.^[5] The use of platinum-based chemotherapeutic regimens improves patient survival; long-term survival can be achieved in some patients with the use of platinum-based chemotherapy.^[6] Bloss *et al.*^[7] in a phase II trial demonstrated that a PPC was similar to an epithelial ovarian carcinoma in response to treatment, toxicity and overall survival. Currently, the CA-125 antigen is considered the most effective tumor marker for a PPC. Similar to ovarian cancer, patients with PPC have CA-125 values that are useful for diagnosis and follow-up of response to therapy. However, it should be noted that not all primary peritoneal carcinomas exhibit increasing levels of CA-125; there is report where CA-125 testing did not detect a PPC before bulky widespread dissemination.^[8] The most common presenting symptoms were abdominal distension and pain. Ascites was the most common sign. Elevated serum albumin levels have been associated with a more favourable prognosis. Metastasis usually occurs transperitoneally. The median survival was between 11.3 and 17.8 months. Additional studies are needed to confirm these findings.

Conclusions

Very often refractory ascites is thought to be carcinoma ovaries especially in the face of a high CA-125 level, but very rarely the cause lies elsewhere and one must look beyond carcinoma ovaries if the CECT pelvis proves it to be negative. The rarity of PPC and its diagnostic difficulty because of nonspecific symptoms, refractory ascites and elevated CA-125 in presence of normal ovaries makes it more challenging. The median survival rate in PPC is less than 2 years. In most cases, cytoreduction followed by cisplatin-based multiagent therapy is the mainstay of treatment. So its management should be multidisciplinary and must be discussed by a panel of physicians in a specialised center.

Declaration of patient consent

The authors certify that they have obtained all appropriate patient consent forms. In the form the patient(s) has/have given his/her/their consent for his/her/their images and other clinical information to be reported in the journal. The patients understand that their names and initials will not be published and due efforts will be made to conceal their identity, but anonymity cannot be guaranteed.

Financial support and sponsorship

Nil.

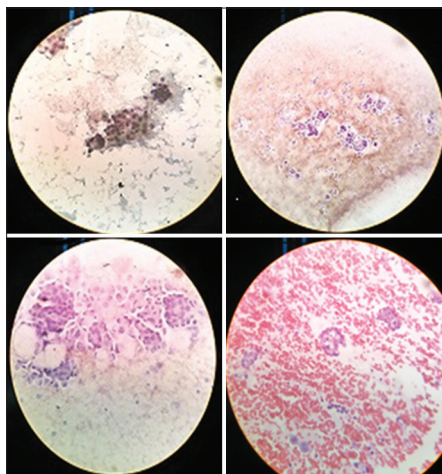


Figure 1: Microscopic examination: Ascitic fluid- cytology and cell block Cytology preparation are found to be cellular with cohesive clusters of mesothelial cells and few clusters of atypical cells in papillary fragments. Individual cells show high N: C ratio, hyperchromatic nuclei, occasional prominent nucleoli and scant cytoplasm. Background is hemorrhagic. Cytological features are highly suspicious of Adenocarcinoma

IHC CUSTOM PANEL (Immunohistochemistry)	
IHC MARKER(S)	RESULT
Calretinin	Non-immunoreactive, Score 0 in atypical cells
WT-1	Immunoreactive, Score 3+ in atypical cells
Ber-EP4	Immunoreactive, Score 4+ in atypical cells
PAX-8	Immunoreactive, Score 4+ in atypical cells
Claudin-4	Immunoreactive, Score 4+ in atypical cells
SAT-B2	Non-immunoreactive, Score 0 in atypical cells

Figure 2: Immunohistochemistry Report

Conflicts of interest

There are no conflicts of interest.

References

1. Yun WS, Bae JM. Primary peritoneal serous carcinoma, an extremely rare malignancy: A case report and review of literature. *Oncol Lett* 2016;11:4063-5.
2. Altaras MM, Aviram R, Cohen I, Cordoba M, Weiss E, Beyth Y. Primary peritoneal papillary serous adenocarcinoma: Clinical and management aspects. *Gynecol Oncol* 1991;40:230-6.
3. Gao B, Lindemann K, Anderson L, Fereday S, Hung J, Alsop K, *et al.* Australian Ovarian Cancer Study Group. Serous ovarian and primary peritoneal cancers: A comparative analysis of clinico- pathological feature molecular subtypes and treatment outcome. *Gynecol Oncol* 2016;142:458-64.
4. Weiss NS, Homonchuk T, Young JL Jr. Incidence of the histologic types of ovarian cancer: The U.S. Third National Cancer Survey, 1969-1971. *Gynecol Oncol* 1977;5:161-7.
5. Chu CS, Menzin AW, Leonard DG, Rubin SC, Wheeler JE. Primary peritoneal carcinoma: A review of the literature. *Obstet Gynecol Surv* 1999;54:323-35.
6. Chen KT, Flam MS. Peritoneal papillary serous carcinoma with long-term survival. *Cancer* 1986;58:1371-3.
7. Bloss JD, Brady MF, Liao SY, Rocereto T, Partridge EE, Clarke-Pearson DL; Gynecologic Oncology Group Study. Extraovarian peritoneal serous papillary carcinoma: A phase II trial of cisplatin and cyclophosphamide with comparison to a cohort with papillary serous ovarian carcinoma-A Gynecologic Oncology Group Study. *Gynecol Oncol* 2003;89:148-54.
8. Karlan BY, Baldwin RL, Lopez-Luevanos E, Raffel LJ, Barbuto D, Narod S, *et al.* Peritoneal serous papillary carcinoma, a phenotypic variant of familial ovarian cancer: Implications for ovarian cancer screening. *Am J Obstet Gynecol* 1999;180:917-28.