

# Role of lymphoscintigraphy in diagnosis and management of patients with leg swelling of unclear etiology

Tek Chand Kalawat, Ravi Kumar Chittoria<sup>1</sup>, Praveen Kumar Reddy<sup>1</sup>, Batchu Suneetha, Ravishwar Narayan, Parthasarthi Ravi

Departments of Nuclear Medicine, <sup>1</sup>Plastic Surgery, Sri Venkateswara Institute of Medical Sciences, Tirupati, Andhra Pradesh, India

## ABSTRACT

**Background:** To study the utility of lymphoscintigraphy in detection of lymphatic obstruction in patients with leg swelling of unclear etiology, selection of site for nodo venous shunt procedure, and follow-up lymphoscintigraphic documentation of improved lymph flow in surgically treated limb. **Materials and Methods:** Twenty four consecutive patients with leg swelling, 10 male, 14 female with mean age 47 years, range from 13 years to 74 years underwent lymphoscintigraphy. All patients were referred from Department of Plastic Surgery, after initial work-up, and routine investigations to rule out the other causes of leg swelling. Both clinical and scintigraphic staging performed for all patients. All clinically and scintigraphically positive patients treated with decongestive lymphatic therapy (DLT). In addition to the DLT, those patients positive for unilateral or bilateral lymphedema, consented for surgical intervention, nodo venous shunt (NVS) in their only affected or one of the two affected lower limbs. Follow-up lymphoscintigraphy performed in operated cases after 3 months to 6 months of surgery, lymphoscintigraphy images of each patient in pre and post-surgery compared. **Results:** In 20/24 cases (83%) of clinically positive leg swelling were found to be positive for lymphedema on lymphoscintigraphy and remaining, 4/24 were scintigraphically normal. Based on the clinical and lymphoscintigraphy staging, 03/20 cases (15%) had Grade I lymphedema, 01/20 (5%) Grade II lymphedema, 06/20 (30%) Grade III and remaining 10/20 (50%) had Grade IV lymphedema. 11/20 cases of Lymphedema (55%) were managed conservatively by only DLT and in remaining 09/20 cases (45%), who were case of Grade IV, lymphedema (five patients with unilateral and four patients with bilateral disease) initially treated with DLT, and on completion of DLT, undergone for NVS procedure, in their unilaterally affected lower limb or one of the two diseased lower limbs. All nine patients showed remarkable clinical improvement in leg swelling and their follow-up lymphoscintigraphy showed normal visualization of lymphatic channels. No patient developed any recurrence. **Conclusion:** Pre-operative functional evaluation of lymphatic channels using lymphoscintigraphy, is a widely available, simple imaging test and highly useful for documentation of lymphedema in patients with leg swelling of unclear etiology and also for exact localization of inguinal lymph nodes to perform the NVS procedure. Further, it can play important role for follow-up of patients receiving DLT or DLT with surgical intervention that provides early relief from clinical symptoms.

**Keywords:** Leg swelling, lymphedema, lymphoscintigraphy, nodo venous shunt

## INTRODUCTION

Leg swelling or edema is defined as a palpable swelling in the leg caused by an increase in interstitial fluid volume.<sup>[1]</sup> A common challenge for primary care physicians is to determine the

cause and find an effective treatment for the leg edema of unclear etiology.<sup>[2]</sup> Lymphedema consists of excess protein-rich interstitial fluid within the skin and subcutaneous tissue resulting from lymphatic dysfunction.<sup>[3]</sup> Lymphedema is one of the common cause of leg swelling in the Southern part of India. Besides clinical diagnosis, lymphoscintigraphy is useful imaging modality to rule out lymphedema as a cause of leg swelling.<sup>[4]</sup> However, there is no internationally agreed standardized technique. This article considers role of lymphoscintigraphy in the diagnosis of leg swelling of unclear etiology and its clinical application in selection of treatment modality and determining the recurrence of disease in follow-up.

### Access this article online

#### Quick Response Code:



Website:  
www.ijnm.in

DOI:  
10.4103/0972-3919.115392

#### Address for correspondence:

Dr. Tek Chand Kalawat, Department of Nuclear Medicine, Sri Venkateswara Institute of Medical Sciences, Tirupati - 517 507, Andhra Pradesh, India.  
E-mail: kalawat.svims@gmail.com

## MATERIALS AND METHODS

In this retrospective study, twenty-four consecutive patients, 10 male, 14 female with mean age 47 years, range from 13 to 74 referred for lymphoscintigraphy from January 2010 to July 2011 were recruited to find the cause of leg swelling of clinically unclear etiology. Before sending for scintigraphy, all patients were clinically examined and investigated using routine baseline tests to find out the cause of leg swelling. When the clinical and routine test results were unremarkable patients labeled as leg swelling with unclear etiology and referred for lymphoscintigraphy. Informed consent was taken for lymphoscintigraphy from all patients.

Technetium-99m-sulfur colloid (unfiltered), injections were prepared as per the recommendations provided along with the cold kits, supplied by board of radio-isotope technology, India. All patients received subcutaneous injection of 20 MBq of tracer dose, in 0.2 ml volume, using 26-gauge needle and 01 cc volume tuberculin syringe. Radiotracer was injected into the first and second interdigital space in both feet. Whole body serial images, starting from feet to head were taken after the injection of radiotracer immediately to 24 h with reference time points, immediately after injection, 1 h, 4 h and 24 h in anterior and posterior view using a dual head Symbia E Gamma Camera with Syngo workstation Siemens, Germany.

Routinely after injection of radiotracer no exercise was carried out. However, in cases where no groin activity is seen in post injection, more than 30 min image, then patient was asked to do exercise for 20 min. Lower extremity exercise stress maneuvers include walking or limb massage; serial immediate post injection, 1 h, 4 h, and 24 h images of all patients viewed by displaying them on single template in the comparative mode. Following features of the lymphatic system were noted in each qualitative

lymphoscintigraphy study:

1. The number and course of lymphatic vessels.
2. The symmetry and intensity of uptake and number of regional nodes visualized.
3. The timing of appearance of regional nodes. First inguinal node visible by 30 min was considered as "normal." Non or poor visualization of inguinal nodes 30 min even after exercise was considered as "abnormal".
4. The presence of "dermal backflow," or dermal collateral flow (an abnormal feature).
5. The presence of abnormal deep collateral flow, e.g. the appearance of popliteal nodes following a subcutaneous injection of radiotracer into the first interdigital space in the foot.
6. Malformations and lymphocoeles, which connect with the lymphatic system.
7. "Extravasation" at tracer sites of lymphatic damage, e.g, following cellulites.
8. Thoracic duct obstruction/leaks.
9. Reflux flow down lymphatic vessels (valvular incompetence).

Lymphedema staging was carried out for all patients clinically [Table 1] and scintigraphically [Table 2] as described by Lee and Bergan.<sup>[5]</sup> All patients diagnosed with lymphedema; clinically and scintigraphically, were treated with decongestive lymphatic therapy (DLT), a combination of all the following: compression, manual lymphatic drainage, exercises, and skin care and 3 weeks course of diethyl Carbamazepine. Patients who agreed for surgery, besides conservative management with DLT, benefit of drainage procedure nodo venous shunt (NVS) was given to improve the lymph drainage. For assessment of treatment response, documentation of lymph flow through the lymphatic channels after NVS, a follow-up lymphoscintigraphy performed after 3 months to 6 months of surgery. Any post-operative complication related to NVS surgery was recorded.

**Table 1: Lymphedema clinical staging**

Feature	Grade I	Grade II	Grade III	Grade IV
Edema	Mild, easily reversible	Moderate, reversible with effort	Moderate to severe, minimally reversible or irreversible	Severe, irreversible
Skin changes	None, no DFS	None to minimal, no DFS	Moderate with DFS	Severe with advanced DFS
Sepsis	None	None to occasional	<4 times/year	≥4 times/year
Limitation of daily activity	None	Occasional and/or moderate	Frequent and significant	Constant and severe
Quality of life	Good with minimal/occasional limitation	Fair with moderate limitation	Poor with significant limitation	Bad with severe limitation

NB: A minimum of three or more clinical findings are required for clinical staging; DFS: Dermato-fibrosclerosis

**Table 2: Lymphoscintigraphy staging of lymphedema**

Feature	Grade I	Grade II	Grade III	Grade IV
Degree of lymph node uptake		None	None	None
Presence of dermal back flow	None	Present in: (a) < half of each limb (b) > half of each limb	Present	Poor or no visualization
Visualization of collateral lymphatics	Good	Decreased	Poor	None visualized
Visualization of main lymphatics	Decreased	Poor to no visualization	None visualized	None visualized
Clearance of tracer from injection site	Decreased	Greater decrease	No clearance	No clearance

NB: A minimum of two or more findings are required for staging

## RESULTS

Of the 24 cases, 20 cases (83%) of limb swelling were found to be of lymphedema. Based on the clinical and lymphoscintigraphy staging, out of 20 cases of lymphedema, 3 cases (15%) had Grade I lymphedema, 1 case (5%) Grade II lymphedema, 6 (30%) Grade III and remaining 10 (50%) cases had Grade IV lymphedema. Table 3, shows the demographic profile, clinical, scintigraphic staging and treatment given to all patients.

Among these 20 cases, 11 (55%) lymphedema patients were managed conservatively by DLT and in remaining 09/20 cases (45%), who were case of Grade IV, lymphedema (five patients with unilateral and four patients with bilateral disease) initially treated with DLT, on completion of DLT, undergone for NVS procedure, either for unilaterally affected or one of the bilateral affected lower limbs. No complication related to NVS surgery was noted. Patients were followed clinically and with lymphoscintigraphy after 3 months to 6 months, all nine patients, showed remarkable clinical improvement in leg swelling and their follow-up lymphoscintigraphy showed normal visualization of lymphatic channels. No patient developed any recurrence. Eleven patients who received DLT showed only partial clinical improvement. In two patients, who were clinically unilateral lymphedema, lymphoscintigraphy showed, Grade I lymphedema in their contra lateral normal lower limb. Four patients, who were clinically positive for leg swelling, but scintigraphically negative considered as case of early disease with patent lymphatic channels and kept in close follow to monitor any progression of the disease.

## DISCUSSION

Lymphoscintigraphy is widely considered to be the main investigation to establish the diagnosis of lymphedema and visualize peripheral lymphatics.<sup>[6,7]</sup> However, the indications for its use vary throughout the world. In some centers it is advocated for virtually all patients with lymphedema, whereas in others it is rarely used. This study looks at various technical aspects of lymphoscintigraphy and its usefulness in the assessment and management of patients with leg swelling of unclear etiology. Lymphoscintigraphy relies on one of the essential functions of the lymphatic system that is to transport large molecules from the interstitial space back to the vascular compartment. Therefore, if a large molecule such as a protein or colloid with a radioactive label e.g., Tc-99m is injected into the interstitial space, its transport through the initial lymphatics, the collectors and region lymph nodes, can be followed using the gamma camera to detect the radioactivity. This provides a picture of lymphatic function and pathways, but does not give the degree of fine anatomical detail, which may be seen with direct X-ray lymphography.<sup>[8]</sup> Although the lymphoscintigraphy technique relies upon the normal function of the lymphatic system in removing macromolecules from the interstitial space, different molecules are handled in different ways and this can therefore affect the appearances of the lymphoscintigram.

There are two main types of preparations used: Macromolecules and colloidal suspensions.<sup>[9]</sup> The radiolabel attached to these to make them detectable is usually Tc-99m-colloids are cleared more slowly from the injection site than macromolecules and

**Table 3: Demographic profile of patients, clinical, lymphoscintigraphy staging and treatment given**

Patient	Age	Sex	Lymphedema	Clinical stage	Lymphoscintigraphy stage	Treatment given
PR	59	F	Bilateral	Grade III	Grade III	DLT
SNA	49	M	Bilateral	Grade III	Grade III	DLT
PA	40	F	Unilateral	Grade I	Grade I	DLT
WDN	67	M	Unilateral	Grade I	Grade I	DLT
AS	44	F	Bilateral	Grade IV	Grade IV	DLT+NVS
KNM	54	F	Unilateral	Grade IV	Grade IV	DLT+NVS
PG	55	F	None	None	None	None
GL	20	M	Unilateral	Grade III	Grade III	DLT
AM	65	F	Unilateral	Grade III	Grade III	DLT
KN	65	F	None	None	None	None
BL	26	F	None	None	None	None
BKK	64	F	Unilateral	Grade III	Grade III	DLT
TP	39	F	Unilateral	Grade IV	Grade IV	DLT+NVS
NG	13	M	Unilateral	Grade IV	Grade IV	DLT+NVS
PM	23	F	Unilateral	Grade IV	Grade IV	DLT+NVS
PNS	64	M	Unilateral	Grade IV	Grade IV	DLT+NVS
MP	46	F	None	None	None	None
KM	63	F	Bilateral	Grade IV	Grade IV	DLT+NVS
JE	28	F	Unilateral	Grade I	Grade I	DLT
KS	74	M	Bilateral	Grade III	Grade III	DLT
LRK	65	M	Bilateral	Grade IV	Grade IV	DLT+NVS
S	19	M	Bilateral	Grade IV	Grade IV	DLT+NVS
VNV	19	M	Unilateral	Grade II	Grade II	DLT
KRR	57	M	None	None	None	None

DLT: Decongestive lymphatic therapy; NVS: Nodo venous shunt

therefore do not show the lymphatic vessels as clearly. They are however, trapped more effectively in the lymph nodes and make them more visible on the scan. Qualitative studies primarily aim to demonstrate the morphology of the lymphatic system and so a colloidal preparation, which will outline the lymph nodes and vessels, may be the best choice.<sup>[9]</sup> In our study, Tc-99m-sulfur colloid was used for qualitative lymphoscintigraphy studies. Exercise or massage at the site of injection has been shown to enhance the uptake of the particles into the lymphatics substantially.<sup>[10]</sup> In our study, exercise was carried out when inguinal nodes were not visualized post 30 min images. The rate of uptake of the radiotracer may be influenced by the volume injected as well as the concentration of the tracer. These may affect the local tissue hydrostatic and oncotic pressures at the site of injection. The subcutaneous route used in this study for tracer administration has been recommended in literature for both qualitative and quantitative studies and is considered optimal for the injection of colloids.<sup>[11,12]</sup>

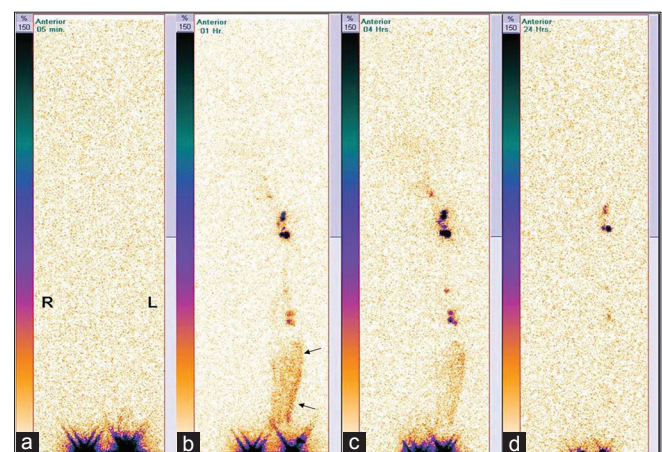
Qualitative lymphoscintigraphy, which aims to image the morphology of the lymphatic system and quantitative lymphoscintigraphy to measure lymphatic flow may be a more sensitive way of diagnosing lymphatic impairment. The reported sensitivity of qualitative lymphoscintigraphy in diagnosing lymphedema is 70% and it improves to 100% when quantitative parameters are added.<sup>[13]</sup> However, a sequence of images taken at different times and following the injected radio-colloid, in qualitative imaging can be used to demonstrate, a delay in lymphatic drainage e.g., by examining the time taken after the injection until the regional lymph nodes are visualized. Study is interpreted as normal or abnormal on the basis of timings of the visualization of regional nodes. Burnand *et al.*, considered it normal, when the inguinal lymph glands were visualized following a subcutaneous injection into interdigital space in the foot within 40 min.<sup>[14,15]</sup> Similarly, in our study, non-visualization of inguinal nodes after 30-40 min after tracer injection was considered as abnormal.

The features of a lymphatic system, which qualitative lymphoscintigraphy can describe are shown in Table 2. However, in the absence of standardized regimens, e.g., when images are taken and whether all patients exercise during the study, it is difficult to compare the results of study from one center with another, indeed, and one patient with another. Visualization of popliteal nodes, suggesting routing of lymph flow from the superficial to the deep system.<sup>[9,12]</sup> However, in another study by Weissleder and Weissleder, showed disagreement to this observation and described the presence of one to three popliteal nodes in their normal subjects following the subcutaneous injection of tracer into the first and second interdigital spaces in the feet.<sup>[13]</sup> In this study, most of the imaging features including visualization of popliteal lymph nodes as mentioned in Table 2 were seen in patients with lymphedema, except thoracic duct obstruction, regional leaks and reflux flow down in lymphatic channels as it may be seen in patients with valvular incompetence of lymph channel.

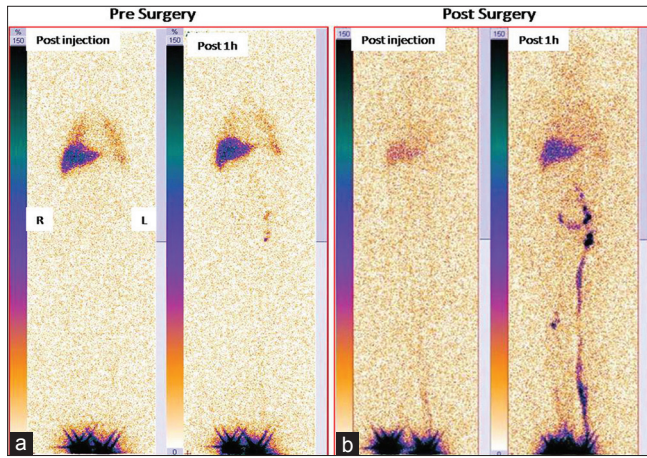
Lymphoscintigraphy may be a useful preoperative investigation; Vaqueiro *et al.* reported the value of lymphoscintigraphy in the selection of patients for micro vascular procedures, lymphovenous anastomoses, by demonstrating the patency of major lymph channels suitable for anastomoses, which could not be predicted on clinical grounds.<sup>[16]</sup> In our study, one of the aims of lymphoscintigraphy besides confirmation of clinical diagnosis was to help in identifying the location of lymph nodes for NVS procedure. Simultaneous, imaging of the normal limb with patients with unilateral lymphedema is highly useful and provides a reference for correlation, it may detect the early stage abnormalities in apparently normal limb, and this is an additional advantage of lymphoscintigraphy, which considers evaluation of both limbs simultaneously. In our study, two patients, presented with unilateral leg swelling, lymphoscintigraphy showed, Grade IV, disease in clinically symptomatic and Grade I, disease in contralateral asymptomatic lower limb [Figure 1].

Lee and Bergan reported the utility of lymphoscintigraphy for prediction of the outcome of treatment.<sup>[5]</sup> They devised a staging system based upon lymphoscintigraphy findings and used it with clinical staging, which includes a simple quality of life measure to predict treatment outcome and decide when additional medical or surgical therapy is indicated [Tables 1 and 2]. In our study, we used the same clinical and lymphoscintigraphy staging, both staging systems were correlated well. Clinical and lymphoscintigraphy staging helped in follow-up of patients, in assessment of response to the given treatment [Figure 2], pre and post-surgery lymphoscintigraphy images of a case of bilateral Grade IV, lymphedema, showed remarkable clinical improvement and normal visualization of lymphatic channels in the left lower limb. Similarly, all the patients responded well to the treatment given.

For evaluation of the patients with lymphedema, other imaging modalities are being developed, these include



**Figure 1:** Serial lymphoscintigraphy, anterior projection images, (a) immediate post injection, (b) 1h, (c) 4 h and (d) 24 h, shows, Grade IV lymphedema in right lower limb (no uptake in lymph nodes and lymphatic channels), incidentally detected Grade I, lymphedema, with "dermal back flow" below knee joint (arrow) and visualization of popliteal nodes in clinically normal left lower limb



**Figure 2:** A case of bilateral Grade IV lymphedema, treated with nodo venous shunt in left lower limb, post-treatment lymphoscintigraphy, 1 h image shows, marked improvement of tracer uptake in inguinal node and visualization of main lymphatic channel

fusion of lymphoscintigraphy/computerized tomography scans to assess the functional and morphological status of lymphatic channels of affected limb<sup>[17]</sup> and interstitial magnetic resonance imaging (MRI) scans, in which a material detectable by MRI is injected subcutaneously and is absorbed into the lymphatics.<sup>[18]</sup> It is too early to judge where these techniques will fit into the assessment of patients with swollen limbs. In the meantime, lymphoscintigraphy remains an important tool in the diagnosis and management of chronic edema.<sup>[19]</sup> The limitations of this study include its retrospective design, fewer numbers of patients and use of Tc-99m-sulfur colloid, which can provide only qualitative analysis of lymphoscintigraphy images.

## CONCLUSION

For functional evaluation of lymphatic channels, lymphoscintigraphy, is a widely available, simple imaging test, highly useful for documentation of lymphedema in patients with the leg swelling of unclear etiology. In this retrospective study, patients with leg swelling of unclear etiology, when evaluated with lymphoscintigraphy showed high incidence of lymphedema. Lymphoscintigraphy not only helped in diagnosis; but, also helped in staging as well as selection of exact localization of inguinal lymph nodes to perform the NVS procedure and follow-up of patients.

## REFERENCES

1. Menzoain JO, Doyle JE. Venous insufficiency of the leg. *Hosp Pract* 1989;24:109-16.
2. Alguire PC, Mathes BM. Chronic venous insufficiency and venous ulceration. *J Gen Intern Med* 1997;12:374-83.
3. Rudkin GH, Miller TA. Lipedema: A clinical entity distinct from lymphedema. *Plast Reconstr Surg* 1994;94:841-7.
4. Topham EJ, Mortimer PS. Chronic lower limb oedema. *Clin Med* 2002;2:28-31.
5. Lee BB, Bergan JJ. New clinical and laboratory staging systems to improve management of chronic lymphedema. *Lymphology* 2005;38:122-9.
6. International Society of Lymphology. The diagnosis and treatment of peripheral lymphedema. Consensus document of the International Society of Lymphology. *Lymphology* 2003;36:84-91.
7. Società Italiana di Linfangiologia. EBM guidelines on the diagnosis and treatment of lymphoedema. *Eur J Lymphol Relat Probl* 2006;16:11-21.
8. Partsch H. Assessment of abnormal lymph drainage for the diagnosis of lymphedema by isotopic lymphangiography and by indirect lymphography. *Clin Dermatol* 1995;13:445-50.
9. Kramer EL. Lymphoscintigraphy: Defining a clinical role. *Lymphat Res Biol* 2004;2:32-7.
10. Ikomi F, Hanna GK, Schmid-Schönbein GW. Mechanism of colloidal particle uptake into the lymphatic system: Basic study with percutaneous lymphography. *Radiology* 1995;196:107-13.
11. Bourgeois P. Critical analysis of the literature on lymphoscintigraphic investigations of limb edemas. *Eur J Lymphol* 1997;6:1-9.
12. Szuba A, Shin WS, Strauss HW, Rockson S. The third circulation: Radionuclide lymphoscintigraphy in the evaluation of lymphedema. *J Nucl Med* 2003;44:43-57.
13. Weissleder H, Weissleder R. Lymphedema: Evaluation of qualitative and quantitative lymphoscintigraphy in 238 patients. *Radiology* 1988;167:729-35.
14. Burnand KG, Mortimer PS, Partsch H. Diagnosis and investigation of lymphoedema. In: Browse NL, Burnand KG, Mortimer PS, editors. *Diseases of the Lymphatics*. London: Arnold; 2003.
15. Larcos G, Foster DR. Interpretation of lymphoscintigrams in suspected lymphoedema: Contribution of delayed images. *Nucl Med Commun* 1995;16:683-6.
16. Vaqueiro M, Glociczki P, Fisher J, Hollier LH, Schirger A, Wahner HW. Lymphoscintigraphy in lymphedema: An aid to microsurgery. *J Nucl Med* 1986;27:1125-30.
17. Pecking AP. The fusion of anatomic and functional images: New development in lymphatic imaging. Presented at international society of lymphology congress, 2005, Sao Paulo, Salvador, Brazil.
18. Ruehm SG, Schroeder T, Debatin JF. Interstitial MR lymphography with gadoterate meglumine: Initial experience in humans. *Radiology* 2001;220:816-21.
19. Keeley V. The use of lymphoscintigraphy in the management of chronic oedema. *J lymphoedema* 2006;1:42-57.

**How to cite this article:** Kalawat TC, Chittoria RK, Reddy PK, Suneetha B, Narayan R, Ravi P. Role of lymphoscintigraphy in diagnosis and management of patients with leg swelling of unclear etiology. *Indian J Nucl Med* 2012;27:226-30.

**Source of Support:** Nil. **Conflict of Interest:** None declared.