

CONGENITAL GRANULAR CELL TUMOUR OF THE NEWBORN: A CASE REPORT OF THE RARE LESION

B.O. Castano¹, A.C. Oluwarotimi², O.A. Adesina³ and A.O.S. Ayodele⁴

1. Department of Family Dentistry, General Hospital Mushin, Lagos.
2. Department of Oral and Maxillofacial Surgery, Lagos University Teaching Hospital, Idi-Araba, Lagos.
3. Department of Oral and Maxillofacial Surgery, Lagos State University Teaching Hospital, Ikeja
4. Department of Oral and Maxillofacial Surgery, General Hospital, Lagos Island.

Correspondence:

Dr. B.O. Castano

Department of Family Dentistry,
General Hospital,
Mushin,
Lagos
E-mail: babaalamu@gmail.com

ABSTRACT

Congenital granular cell tumour [CGCT], a benign soft tissue tumour was a surprise discovery to the parents as well as the obstretical staffs at birth. It developed in the maxillary left canine region causing oral disfigurement and feeding problems. Diagnosis was essentially clinical and confirmed by histology. Surgical excision was done. We describe a case of CGCT in a 3-week old female neonate in the paediatric dentistry unit of LASUTH.

Keywords: Congenital, Gingival granular cell, Maxilla, Neonate.

INTRODUCTION

Congenital granular cell tumour [CGCT] is a rare benign soft tissue tumour found on the gingiva of the anterior dentoalveolar segment of the maxillary arch of the newborn.¹⁻⁴ This tumour was first described in 1871 by a German pathologist, Dr Franz Ernst Christian Neumann and he called it congenital gingival epulis.¹⁻⁴ The term 'epulis' is a Greek word meaning gingival swelling and in dentistry is a nonspecific hyperplastic gingival tissue or gingival mass.³ However, WHO recommended the terms congenital granular cell epulis; other terms used to describe this condition include: Congenital granular cell lesion, congenital epulis of the newborn, gingival granular cell tumour of the newborn, congenital granular cell myoblastoma and granular cell fibroblastoma.³ This lesion usually presents on the alveolar ridge as a smooth surfaced single pedunculated or sessile lesion of 2x2x1cm in dimension but may grow up to 9cm, disturbing respiration, feeding and cause inadequate mouth closure.³⁻⁵ It occurs more in females than males 10:1 and more in maxilla than mandible 3:1.^{3,5} The incidence of this tumour is 0.006% of newborns¹, and the usual location is between the maxillary lateral incisor and canine. Maternal hormone has been implicated in the development of this lesion, which grows rapidly in utero in the third trimester but may cease after birth. There are no associated dental abnormalities or congenital malformationu . Multiple lesions had been reported in 10% of CGCT cases.^{3,4}

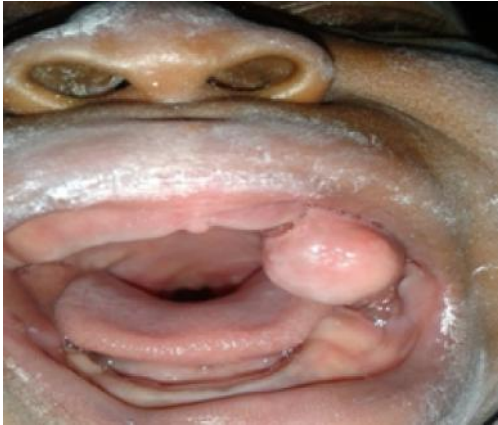The histogenesis of this tumour is unknown, but postulated theories of aetiologic origins include: undifferentiated mesenchymal cells, Schwann cells,

histiocytic, neurogenic, fibroblastic, myofibroblastic, endocrinologic, and odontogenic epithelial cells.⁵⁻⁶ The diagnosis is usually clinical but confirmed by histopathologic evaluation. Definitive treatment is surgical excision¹⁻⁶, although there had been report of spontaneous regression.^{1,6} It rarely recurs even when incompletely excised.

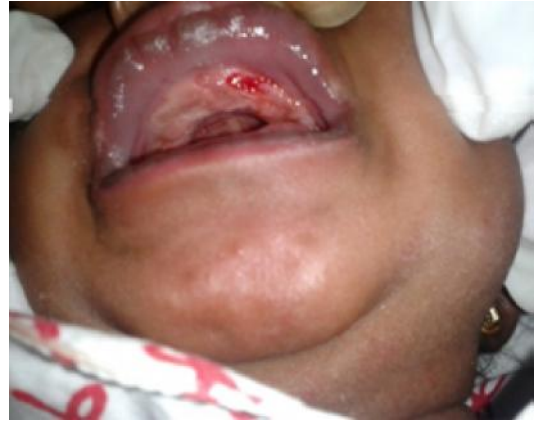We present this rare congenital gingival granular cell tumour in a three-week-old neonate.

CASE REPORT

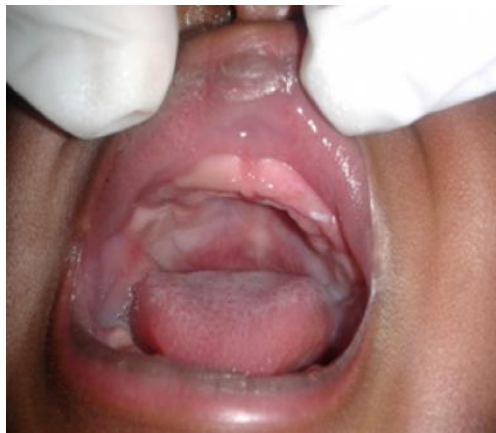A three-week-old female neonate was referred to the paediatric dentistry unit from the oral diagnosis clinic of the Lagos State University Teaching Hospital [LASUTH] on account of swelling on the gum, noticed from birth. The swelling was not increasing in size, nor was it associated with bleeding, pus discharge or ulceration. The patient's mother however, complained of disfigurement and disturbance during breast feeding. Past medical, obstetric and gynaecologic histories were not contributory. Physical examination revealed a healthy-looking female neonate with no facial deformity, and no bony or soft tissue pathoses except for protruding pedunculated soft tissue mass measuring about 2x2cm in its widest diameter in the maxillary right anterior dentoalveolar segment. Mucosa overlying the swelling appeared normal. There was no lobulation observed; neither tenderness nor bleeding on palpation. A diagnosis of congenital epulis was made. Parental apprehension necessitated an immediate clinical intervention. Surgical excision was done under



Pre-operative clinical picture



Immediate intra-operative clinical picture



A month post-operative clinical picture

local anaesthesia and the patient was discharged and followed-up. Histopathologic evaluation revealed the mass to be congenital granular cell tumour of the newborn.

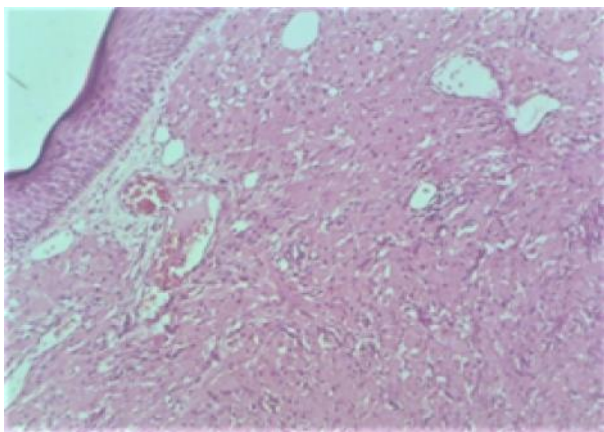


Figure A: Photomicrograph showing a connective tissue composed of large granular cells, surfaced by an atrophic keratinized stratified squamous epithelium devoid of rete ridges, Haematoxylin and Eosin stain, x40 magnification.

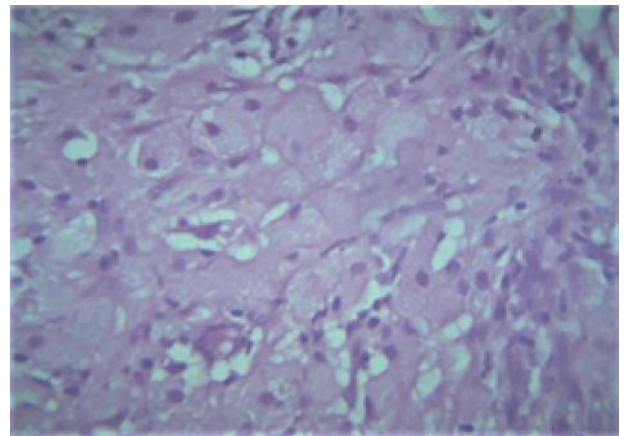


Figure B: Photomicrograph showing connective tissue composed of large polygonal cells with eosinophilic granular cytoplasm and small central nuclei, Haematoxylin and Eosin stain, x400 magnification.

DISCUSSION

Congenital granular cell tumour of the newborn also known as congenital epulis is a rare benign soft tissue lesion that is frequently located in the maxillary anterior dentoalveolar segment usually by a stalk, although some

cases have been reported in the anterior mandibular arch.¹⁻⁵ In this presented case, the lesion was situated between the lateral incisor and canine region of the maxilla and it correlates with the frequent location of all the cases [71.4%] of CGCT reported in the literature.^{1-4,7} Also, a female neonate is affected confirming the higher preponderance of occurrence in female than the male.⁷ It was initially thought that the hormonal influence was responsible for the gender predilection of CGCT, but there is no scientific evidence to support this claim as no detectable oestrogen and progesterone receptors is contained in CGCT.^{8,9} As of year 2015, about 250 cases had been reported in literature.⁴ Salami *et al.*⁷ reported seven cases in four Nigerian tertiary hospitals diagnosed by histology from year 2010 to 2018 by the respective Oral Pathology department; but to the best of our knowledge this present case will be the second of CGCT to be reported in literature in Lagos State hospitals; the first being in General Hospital, Lagos Island by Olojede *et al.*¹⁰, hence, the rarity of this lesion. This present lesion was pedunculated attached by a stalk to the anterior maxilla, which is consistent to the report by Salami *et al.*⁷ where five of these lesions were reportedly attached to the maxilla and two attached to the mandible. Also, two were sessile while the others were pedunculated and lobulated.⁷ In some reported cases, prenatal diagnostic imaging techniques like ultrasound sonography [USS]³ and magnetic resonance imaging [MRI] were employed to diagnose the tumour mass in utero.⁵ This present case, the mother claimed that prenatal USS was done and there was mention of any oral lesion by investigating medical practitioner, but MRI was certainly not done for evaluation of any congenital deformity in the foetus. Prenatal diagnosis is not routinely done in our hospitals and moreso not easily affordable to these patients. Therefore, diagnosis was done post-natally using clinical parameters and histopathology.

In this present case, surgical excision was preferred to conservative treatment [spontaneous regression] by the obviously agitated parents who just wanted to get rid of the mass immediately; having waited three weeks hoping it regressed but failed to do so. This is consistent with the observation by Dhareula *et al.*¹¹ that CGCT does not always regress. The psycho-social impact on the parents occasioned by this disfigurement and queries from relatives might have made the parents comfortable with surgical excision. Besides, the inability of the infant to achieve adequate lip seal during breastfeeding will be frustrating for the infant who may be malnourished and occasionally choked hence, perturbing the parents.

A histologic differential diagnosis is adult granular cell tumour [ACGT] or granular cell myoblastoma, described by Abrikosoff in 1926 and it occurs in the 3rd to 6th decade of life.^{3,8,12} This tumour is commonly located in the tongue and buccal mucosa¹². It is also found more in female than male in ratio 2:1³ but rarely in neonates.⁹ Unlike CGCT, ACGT may recur after surgical excision and recurrence may be between 2-8% and can increase to 20%.¹³⁻¹⁵

Immunohistochemically, CGCT had been reported to generally show no immunoreactivity to S-100, CD31, CD68, chormogranin, keratin and actin^{2,4}; but is positive for vimentin and neuron-specific enolase.³ Adeyemi *et al.*⁸, however, reported a positive immunoreactivity of CGCT to S-100, as well as for vimentin and neurone-specific enolase. AGCT normally have positive staining to S-100, neuron-specific enolase, myelin proteins, periodic acid-schiff with diastase and CD68/kp1.⁴

Histologically, CCGT unlike AGCT presents a vascularised, closely packed cells with fine granular, eosinophilic cytoplasm, eccentric nuclei, and little or no mitotic activity; thin overlying stratified squamous epithelium and atrophy of rete pegs (Figures A and B). Unlike ACGT which present with pseudoepitheliomatous hyperplastic epithelium with fibrous and eosinophilic cytoplasm.^{1,3-5,8,9,15}

Other differential diagnosis of CGCT include melanotic neuroectodermal tumour of infancy, haemangioma, fibroma, malignant granular cell myoblastoma, embryonal rhabdomyosarcoma and Schwannoma¹.

Health caregivers, particularly the dentists should be able to recognise this pathological mass using clinical parameters on presentation and reassure the parents,– thus allaying their fears.

CONCLUSION

Congenital Granular Cell Tumour, though a rare lesion, may be an unexpected discovery at birth in a resource-scarce environment like ours; but good clinical examination with histopathology evaluation offer definitive diagnosis.

REFERENCES

1. **Kumar R**, Jaiswal S, Singhal A, Garg R. Congenital granular cell lesion: A rare tumour of the newborn. *J Oral Maxillofac Pathol.* 2013 Sep-Dec; 17(3): 440-442.
2. **Anderson PJ**, Kirkland P, Schafner K, Moss ALH. Congenital gingival granular cell tumour. *J. R Soc Med* 1996; 89: 53-54.

3. **Conrad R**, Perez CN. Congenital Granular Cell Epulis. Arch Pathol lab Med 2014 Jan; 138 pp 128-131.
4. **Aresdahl A**, Lindell B, Dukic M, Thor A. Congenital granular cell epulis – a case report. Oral and Maxillofacial Surgery Cases. 2015 Apr;1 pp 8-11.
5. **McGuire TP**, Gomes PP, Freilich MM, Sandor GKB. Congenital Epulis : A surprise in Neonate. J Can Dent Assoc 2006 Oct; 72(8): 747-50.
6. **Zerener T**, Sencimen M, Altun C, Altug HA. Congenital granular cell tumour in newborn. Eur J Dent 2013; 7: 497-499.
7. **Salami AS**, Akinshipo AO, Oluwakuyide RT, *et al.* Congenital granular cell epulis: Pattern of presentation in four Nigerian tertiary hospitals. Int J Med Dent Case Rep 2018; 5:1-4.
8. **Adeyemi BF**, Oluwasola AO, Adisa AO. Congenital Epulis. Indian J Dent Res; 2010 Apr-Jun; 21(2):292-294.
9. **Gardner P**, Rozzelle A. Congenital Granular Cell Tumour: Case Report and Review. Case Rep Pediatric; 2018 Sept; 2018: 1-3.
10. **Olojede ACO**, Emmanuel M, Kusamotu AA, *et al.* Congenital granular cell tumour: a case report. Nigeria Dent J 2009, 17 (1):26-29.
11. **Dhareula A**, Jaiswal M, Goyal A, Gauba K. Congenital granular cell tumour of the newborn- Spontaneous regression or early surgical intervention. J Indian Soc Pedod Prev Dent 2018; 36: 319-23.
12. **Roозrokh M**, Ansari G, Jadali F, Kermani N. Granular Cell Tumor of Newborn: A Case Report. Journal of Pediatric Surgical Specialties Cases. 2015; 9(2): 1-52.
13. **Goel G**, Singh N, Gupta R, Jain S. Recurrent benign Cutaneous granular cell tumor: A case report. J. Cytol 2013 Oct-Dec; 30(4): 287-288.
14. **Yilmaz AD**, Unlu RE, Orbay H, Sensoz O. Recurrent granular cell tumor: how to treat. J. Craniofac Surg. 2007 Sept; 18(5): 1187-1189.
15. **Shojaei S**, Zareei H, Zaragaran M. Congenital Granular Cell Tumor of Newborn: A case report. DJH 2011; 3(2): 53-57.