

CD10 and CA19.9 immunohistochemical expression in transitional cell carcinoma of the urinary bladder

Ahmed Salahaldeen Mohammed, Husam Hasson Ali¹, Ban Jumaa Qasim¹, Mohammed Kassim Chalooob
Ministry of Health, ¹Department of Pathology and Forensic Medicine, College of Medicine, Al-Nahrain University, Baghdad, Iraq

Abstract

Background: Transitional cell carcinoma of the bladder is the most common malignancy affecting the urinary tract ranking the 5th among males and the 9th among females' cancers in Iraq. The prognosis depends largely on the histological grade and stage of the tumor at diagnosis; however, there is no reliable parameter predicting the risk of recurrence or progression; molecular and immunological markers may be required to estimate the individual prognosis of patients as well as for effective diagnosis and treatment.

Objectives: To evaluate CD10 and CA19.9 immunohistochemical expression in transitional cell carcinoma of the urinary bladder and to correlate this expression with the grade and stage of the tumor.

Materials and Methods: This study was retrospectively designed. Forty-nine cystoscopy specimens of urothelial carcinoma of the bladder were retrieved from the archival materials of the Specialized Surgical Hospital and Al-Khadhmiya Teaching Hospital in Baghdad for the period from January 2010 to June 2011. Three sections of 5- μ m thickness were taken from each case. One section was stained with Hematoxylin and Eosin; the other two were stained immunohistochemically with CA19.9 and CD10.

Results: Immunohistochemical expression of CA19.9 and CD10 had a significant correlation with WHO 2004 grade of urothelial carcinoma. There was no significant correlation between CA19.9 and CD10 immunohistochemical expression with stage.

Conclusions: CA19.9 and CD10 immunohistochemical expression could be of value in assisting the differentiation between high and low-grade urothelial carcinoma cases and consequently in determining the prognosis in such cases.

Key Words: Transitional cell carcinoma, urinary bladder, CA19.9, CD10

Address for correspondence:

Dr. Ban Jumaa Qasim, Department of Pathology and Forensic Medicine, College of Medicine, Al-Nahrain University, Baghdad, Iraq.

E-mail: dr. banqasim@yahoo.com

Received: 16.12.2011, Accepted: 23.03.2012

INTRODUCTION

Urothelial carcinoma or formerly called transitional cell carcinoma of the urinary bladder is the 7th most common

cancer diagnosed worldwide and the 4th most common cancer diagnosed in males and the 9th most common cancer diagnosed in females in USA.^[1] It represents the 5th most common cancer in males and the 9th most common cancer in females in Iraq,^[2] with a male to female ratio of 3:1.^[3] Nearly 80% of patients are between 50 and 80 years of age.^[4] Approximately 75-85% bladder cancer patients present with disease confined to the mucosa,^[5] have a prolonged clinical course in which the patient experience multiple recurrences after local resection without tumor progression. In contrast, a smaller but significant percentage of patients have advanced and muscle-infiltrative tumor at the time of diagnosis.^[6] The prognosis depends

Access this article online	
Quick Response Code:	Website: www.urologyannals.com
	DOI: 10.4103/0974-7796.110002

largely on the histological grade and the stage of the tumor at diagnosis.^[7] The carbohydrate antigen CA19.9 (Sialyl Le-a) is a blood group-related antigen and its expression requires the expression of Lewis a blood group antigen^[8] which is a cancer-associated phenomenon,^[9] CA19.9 is also known to be a ligand for the cell adhesion molecule called ELAM-1, involved in the extravasation of cells from the bloodstream and of particular importance in the adhesion of human epithelial cancer cells to vascular endothelial cells.^[10] This adhesion is proposed to be involved in the hematogenous metastasis of cancer cells.^[11] CD10 is a surface zinc-dependent enzyme metalloprotease that inactivates various bioactive neuropeptides,^[12] in addition to its enzymatic function, CD10 protein has a direct role in signal transduction pathways that regulate cell growth and apoptosis and because of its structural similarity to the matrix metalloproteases in the stroma, CD10 is thought also to affect invasion and metastatic potential of tumor cells by altering the cellular microenvironment.^[13] Few studies had been published in evaluating CD10 and CA19.9 immunohistochemical expression in urothelial carcinoma of the urinary bladder. The aim of this study is to evaluate CD10 (common acute lymphocytic leukemia antigen) and CA19.9 immunohistochemical expression in transitional cell carcinoma of the urinary bladder and to correlate this expression with various histopathological parameters including grade and stage.

MATERIALS AND METHODS

In this retrospective study, formalin-fixed paraffin-embedded tissue blocks were collected from the archive materials of the Specialized Surgical Hospital and Al-Khadhmiya Teaching Hospital, covering the period from January 2010 to June 2011. The paraffin blocks represent 49 cases of urothelial carcinoma of the bladder removed surgically by transurethral resection of the bladder. Clinicopathological parameters such as the histological type, histological grade and pathological stage, were obtained from the available histopathological reports. An informed consent was taken from patients. An absolute confidentiality of the patients' vital information was maintained for ethical purposes and an ethical approval was obtained from institutions in which the study was carried out.

Three sections of 5- μ m thickness were taken, the first was stained by Hematoxylin and Eosin (H and E) for histopathological reassessment of (staging, grading, histological type) of the tumor; the other two sections were stained immunohistochemically using three steps-indirect streptavidin method for CD10 and CA19.9 monoclonal antibodies manufactured by Dako, Denmark.

Regarding CA 19.9, brown staining of the cytoplasm is considered positive. Each stained urothelial tumor section was

analyzed for both presence and extent of staining. The extent of staining was classified into one of four phases compared with the control tissue samples on the slide:^[8,14]

- (0): When coloration is negative.
- (+1): When coloration is weak, clearly visible only at an intense increase.
- (+2): When coloration is of moderate intensity, clearly visible only at median increase. (+3): when coloration is intensely positive, clearly visible at low increase.

Brown staining of the cell membrane and/or cytoplasm by CD10 was considered positive, with a 5% cut-off point in tumor cells. The extent of immunoreactivity was scored semiquantitatively according to the following criteria:^[12]

- (Negative): <5% positive cells.
- (+1): 5%-50% positive cells.
- (+2): >50% positive cells by counting the maximum number of stained cells (1000 cells) in 10 high-power spots.

For quality control, a negative control had been processed identical to that of patients' samples without adding the primary antibody for (CA19.9 and CD10). For positive control, sections from normal liver were stained for CD10, while sections from colorectal carcinoma were considered as positive control for CA19.9.

Statistical analysis was performed using SPSS v18.00 (statistical package for social sciences) and Microsoft Excel 2007 programs. Data analysis was done using Chi-square test for Tables with frequencies. *P* value is considered statistically significant when it is less than 0.05.

RESULTS

A total of (49) paraffin blocks of transitional cell carcinomas of the bladder were included in this retrospective study. According to the 2004 grading system of urothelial carcinoma of the bladder 26/49 (53.06%) of the cases were of high grade and 23/49 (46.93%) of the cases were of low grade [Figures 1 and 2, Table 1]. The distribution of cases of urothelial carcinoma of the bladder according to the pathological T-stage of urothelial carcinoma according to AJCC/UICC was as follow: Stage Ta was 10/49 (20.4%), Stage T1 was 32/49 (65.3%) and stage T2 was 7/49 (14.3%) [Figure 3].

There was a significant correlation between CD10 immunohistochemical expression and the (WHO 2004) grade of urothelial carcinoma (*P* value 0.003) [Table 2, Figure 4]. A significant correlation was found between immunohistochemical expression of CA19.9 and (WHO 2004) grade of urothelial carcinoma (*P* value 0.021) [Figure 5, Table 2]. There was a significant correlation between CD10

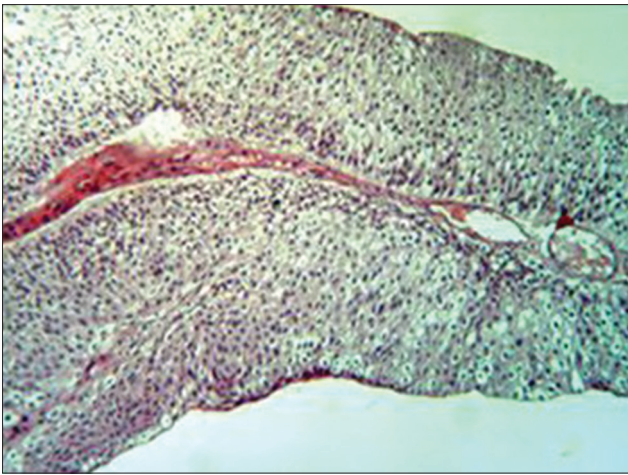


Figure 1: Low-grade papillary urothelial carcinoma of the bladder H and E (×10)

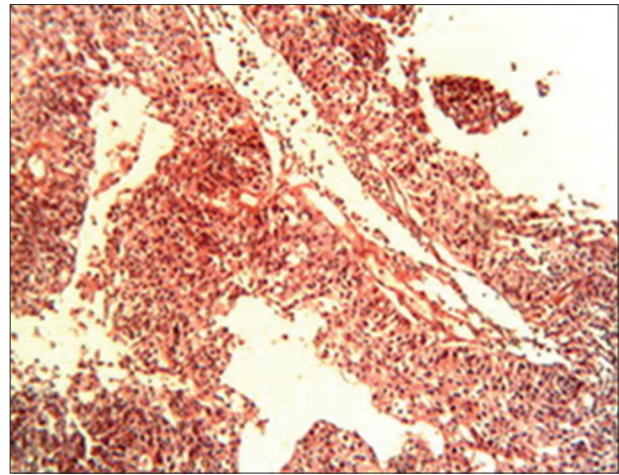


Figure 2: High-grade papillary urothelial carcinoma of the bladder H and E (×10)

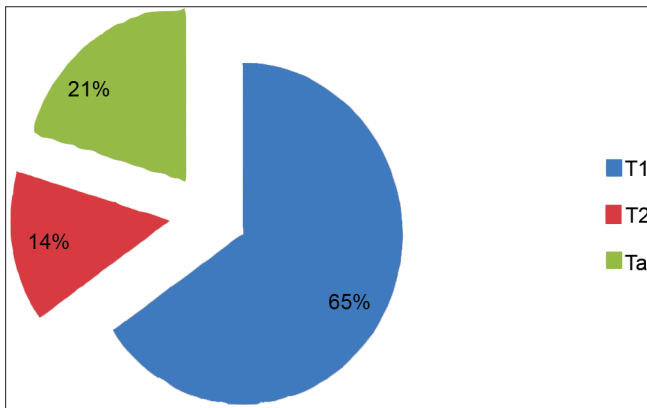


Figure 3: Pie chart showing the distribution of urothelial carcinoma cases according to AJCC/UICC pathological T-stage of the selected cases

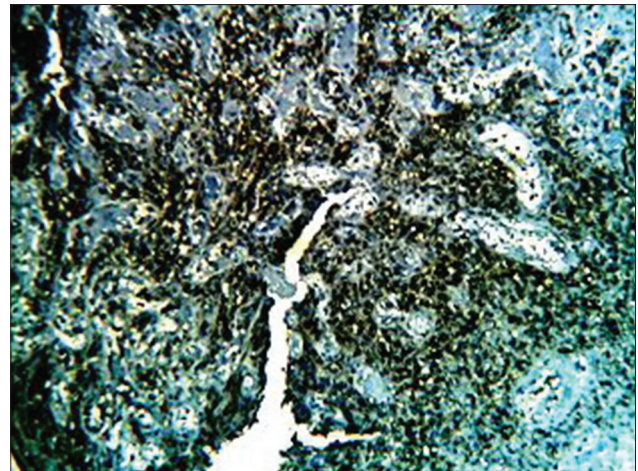


Figure 4: High-grade invasive urothelial carcinoma of the bladder showing intense CD10 immune reaction score +3 (×10)

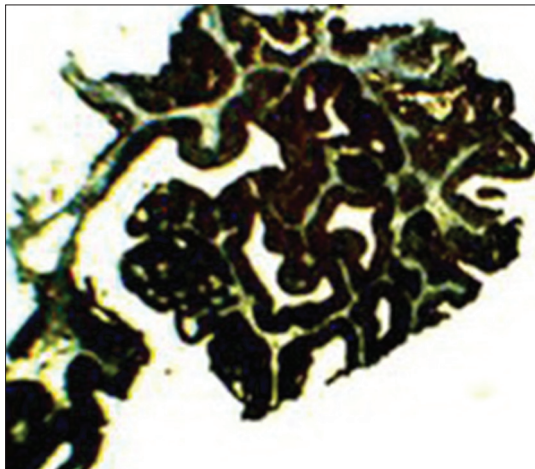


Figure 5: Low-grade papillary urothelial carcinoma of the bladder showing strong (score +3) immunohistochemical reaction of CA19.9 (×4)

immunostaining score and the 2004 urothelial carcinoma grading system (P value 0.002) [Table 3]. However, the correlation between immunohistochemical scoring expression

Table 1: Histological distribution of urothelial carcinoma cases according to 2004 WHO grading system

Grade	Frequency	Percent
Low grade	23	46.93
High grade	26	53.06
Total	49	100.0

Table 2: Distribution of CA 19.9 and CD 10 expression according to the WHO 2004 grading of urothelial carcinoma

CD 10 expression	P		CA 19-9 expression		P
	Low	High	Low	High	
Negative	17	8	5	14	0.021
Positive	6	18	18	12	

Table 3: Immunohistochemical expression score of CD 10 marker in relation with the WHO 2004 grading system of urothelial carcinoma

Grade	CD10 immunoscore			Total	P
	0	1+	2+		
High grade	8	10	8	26	0.002
Low grade	17	6	0	23	
Total	25	16	8	49	

of CA19.9 and the 2004 grading of urothelial tumors was not statistically significant (P value 0.06) [Table 4]. There was no significant correlation between the CD10 and CA19.9 immunohistochemical expression and the AJCC/UICC stage of urothelial carcinoma (P value 0.239) and (P value 0.283), respectively [Table 5]. No significant correlation between CA19.9 and CD10 immunoscore and AJCC/UICC T-staging of urothelial carcinoma (P value 0.18) and (P value 0.472), respectively [Table 6].

DISCUSSION

To the best of our knowledge, this is the first study in Iraq assessing the immunohistochemical expression of CD10 and CA 19.9 in urothelial carcinoma of the bladder using the WHO 2004 grading system of urothelial carcinoma.

The present study revealed a significant correlation between the WHO 2004 grade of urothelial carcinoma cases and the immunohistochemical expression of CA19.9 (P value was 0.021), CA19.9 was over expressed immunohistochemically in low-grade urothelial carcinoma than in high-grade tumors, and these results were supported by studies done by Chuang and Liao^[8] and Kajiwara *et al.*,^[15] on the other hand no significant correlation was found between immunohistochemical scoring of CA19.9 and the WHO 2004 grade of urothelial carcinoma cases; despite that there was a trend toward significance (P value 0.06) in which moderate and strong immunohistochemical scoring of CA19.9 was found more

in low-grade tumors while negative staining was associated with high-grade tumors, taking in consideration that to the best of this knowledge; this study is the only study in which the 2004 grading system of urothelial carcinoma had been used in evaluating CA19.9 immunohistochemical expression. There was a significant correlation between both CD10 immunohistochemical (expression and scoring) and the (WHO 2004) grade of urothelial carcinoma ($P = 0.003, 0.002$ respectively), similar results were obtained by Bahadir *et al.*^[12] Kandemir *et al.*^[16] and Murali *et al.*^[17] The relation between CA19.9 immunohistochemical (expression and score) and the AJCC/UICC pathological T-staging of urothelial carcinoma in our study revealed that there was no significant correlation between such parameter and both CA19.9 immunohistochemical expression and score, these findings were in accordance with Chuang and Liao^[8] and Kajiwara *et al.*^[15] There was no significant correlation between both immunohistochemical (expression and score) of CD10 and the AJCC/UICC pathological T-staging of urothelial carcinoma, which was in agreement with a study done by Kandemir *et al.*,^[16] and disagreed with other studies done by Bahadir *et al.*^[12] and Abdou^[18] who found a significant correlation between immunohistochemical (expression and score) of CD10 and the AJCC/UICC pathological T-staging of urothelial carcinoma. Such discrepancies can be explained by difference in sample size; taking in consideration the small sample size of Abdou AG, moreover, improper staging of the specimens due to subjective errors in assessing the stage or improper transurethral resection technique in which deeper tissues especially the muscular layer had not been taken, may contribute to under or over estimation of staging in these cases which in turn affects the number of cases in each stage,^[19] finally, using a universal immunohistochemical scoring method for evaluating CD10 marker in urothelial carcinoma of the bladder may decrease such discrepancies in results, since each study done on urothelial carcinoma of the bladder with CD10 immunohistochemical marker had used a different scoring method such variations in scoring systems will definitely affect the number of positive cases, ultimately affecting the correlation significance.

In conclusion, this study revealed that CA19.9 and CD10 immunohistochemical expression could be of valuable significance in the differentiation between high and low-grade urothelial carcinoma cases and consequently in determining the prognosis in such cases.

Table 4: Distribution of CA 19.9 immunostaining score according to the WHO 2004 urothelial carcinoma grade

Staining score	CA 19-9 staining score		P
	High grade	Low grade	
0-1	14	5	0.06
2	8	11	
3	4	7	

Table 5: Distribution of the CA19.9 and CD10 expression in urothelial carcinoma cases according to T stage

Stage	CD10			CA 19-9		
	Negative	Positive	Total	Negative	Positive	Total
Ta	7	3	10	2	8	10
T1	16	16	32	13	19	32
T2	2	5	7	4	3	7
Total	25	24	49	19	30	49
	$P=0.239$			$P=0.283$		

Table 6: Relation between CA 19.9 and CD10 immunoscore and the AJCC/UICC stage of urothelial carcinoma

Stage	CA 19.9 immunoscore			Total	P value	Stage	CD10 immunoscore			Total	P value
	0-1	+2	+3				0	+1	+2		
Ta	2	4	4	10	0.472	Ta	7	3	0	10	0.18
T1	13	13	6	32		T1	16	11	5	32	
T2	4	2	1	7		T2	2	2	3	7	
Total	19	19	11	49		Total	25	16	8	49	

REFERENCES

1. Coppola D, editor. Mechanisms of Oncogenesis: An Update on Tumorigenesis. 1st ed. Springer: New York; 2010. p. 279-85.
2. Iraqi Cancer Registry, 2005.
3. Rosai J. Urinary tract. In: Rosai and Ackerman's Surgical Pathology. 9th ed. Philadelphia: Elsevier; 2004. p. 1326-37.
4. Peterson OR, Sesterhenn AI, Davis JC. Urologic pathology. 3rd ed. Philadelphia: Lippincott Williams and Wilkins; 2007. p. 146-22.
5. Babjuk M, Oosterlinck W, Sylvester R, Kaasinen E, Böhle A, Palou J. Guidelines on TaT1 (non-muscle invasive) bladder Cancer. European Association of Urology (EAU): Arnhem, The Netherlands; 2009.
6. Matalka I, Bani-Hani K, Shotar A, Bani Hani O, Bani-Hani I. Transitional cell carcinoma of the urinary bladder: A clinicopathological study. Singapore Med J 2008;49:790-4.
7. Kumar V, Abbas AK, Fausto N, editor. 8th ed. Pathologic Basis of Disease. Elsevier: Philadelphia; 2010. p. 976-80.
8. Chuang CK, Liao SK. Evaluation of CA19-9 as a tumor marker in urothelial malignancy. Scand J Urol Nephrol 2004;38:359-65.
9. Langkilde NC, Wolf H, Meldgård P, Orntoft TF. Frequency and mechanism of Lewis antigen expression in human urinary bladder and colon carcinoma patients. Br J Cancer 1991;63:583-6.
10. Magnani JL. The discovery, biology, and drug development of sialyl Lea and sialyl Lex. Arch Biochem Biophys 2004;426:122-31.
11. Takada A, Ohmori K, Yoneda T, Tsuyuoka K, Hasegawa A, Kiso M, *et al.* Contribution of carbohydrate antigens sialyl Lewis A and sialyl Lewis X to adhesion of human cancer cells to vascular endothelium. Cancer Res 1993;53:354-61.
12. Bahadır B, Behzatoglu K, Bektas S, Bozkurt ER, Ozdamar SO. CD10 expression in urothelial carcinoma of the bladder. Diagn Pathol 2009;4:38.
13. Iwaya K, Ogawa H, Izumi M, Kuroda M, Mukai K. Stromal expression of CD10 in invasive breast carcinoma: A new predictor of clinical outcome. Virchows Arch 2002;440:589-93.
14. Afrem G, Crăițoiu S, Mărgăritescu C, Mogoantă SS. The study of p53 and CA19-9 prognostic molecular markers in colorectal carcinomas. Rom J Morphol Embryol 2010;51:473-81.
15. Kajiwara H, Yasuda M, Kumaki N, Shibayama T, Osamura Y. Expression of carbohydrate antigens (SSEA-1, sialyl-Lewis X, DU-PAN-2 and CA19-9) and E-selectin in urothelial carcinoma of the renal pelvis, ureter, and urinary bladder. Tokai J Exp Clin Med 2005;30:177-82.
16. Kandemir NO, Bahadır B, Gun BD, Yurdakan G, Karadayi N, Özdamar ŞO. CD10 expression in urothelial bladder carcinomas: Staining patterns and relationship with pathologic parameters. Turk J Med Sci 2010;40:177-84.
17. Murali R, Delprado W. CD10 immunohistochemical staining in urothelial neoplasms. Am J Clin Pathol 2005;124:371-9.
18. Abdou AG. CD10 expression in tumour and stromal cells of bladder carcinoma: An association with bilharziasis. APMIS 2007;115:1206-18.
19. Bostrom PJ, van Rhijn B, Fleshner N, Finelli A, Jewett M, Thoms John, *et al.* Staging and staging errors in bladder cancer. European Urology Supplements 2010;9:2-9.

How to cite this article: Mohammed AS, Ali HH, Qasim BJ, Chaloob MK. CD10 and CA19.9 immunohistochemical expression in transitional cell carcinoma of the urinary bladder. Urol Ann 2013;5:81-5.

Source of Support: College of Medicine/Al-Nahrain University and Teaching Laboratories/Al-Khadhmiya Teaching Hospital/Baghdad/Iraq.

Conflict of Interest: None.