

Horner's syndrome secondary to heart surgery in a pediatric patient

Murat Aslankurt, Lokman Aslan

Access this article online

Quick Response Code:



Website:

www.saudijophthalmol.org

DOI:

10.4103/1319-4534.322597

Abstract:

Horner's Syndrome (HS) is a disease characterized by miosis, ptosis, and ipsilateral lack of sweating. It can occur with any injury at the level of the ocular sympathetic system neurons from the hypothalamus to the cervical postganglionic fibers. We present here a case of HS that developed after heart surgery in a 9-year-old boy. Ventricular septal defect, aortic and mitral valves repair, and pacemaker implant procedures were noted in his medical records. Preganglionic HS was diagnosed with bilateral unresponsiveness to a 0.1% adrenaline and positive result in the right eye to 0.5% apraclonidine tests. HS is often related to injuries of the brain stem, upper spinal cord, lung apex tumors and lesions, aortic coarctation, cervical lesions, and carotid lesions have been reported. However, it is rare secondary to heart surgery among the pediatric age group.

Keywords:

Anisocoria, heart surgery, Horner, ptosis

INTRODUCTION

The sympathetic innervation of the eye and adnexa starts in the posterior hypothalamus and descends in the brainstem to terminate in the ciliospinal center of Budge, in the spinal cord at the levels between C8 and T2 (Central fibers). Preganglionic second-order neurons lie between the ciliospinal center and the superior cervical ganglion in the neck. Postganglionic third-order fibers ascend along the internal carotid artery, trigeminal nerve ophthalmic division, and the long ciliary nerve.^[1] Horner's Syndrome (HS) can occur with any injury at the ocular sympathetic system neurons from the hypothalamus to cervical postganglionic fibers, and the disease is characterized by miosis, ptosis, and anhidrosis (ipsilateral lack of sweating). In addition to these cardinal symptoms, other associations such as changes in accommodation and intraocular pressure, and conjunctival injection may occur in HS.

In this article, the aim is to share the case of a pediatric patient who developed HS after cardiac

surgery and evaluation of possible etiological factors.

CASE REPORT

A 9-year-old boy admitted to the ophthalmology clinic with ptosis in his right eye that developed after a heart surgery 2 months before. Anisocoria with mild ptosis of the right eye was present [Figure 1]. Both pupils reacted briskly to light stimulation. Levator function was measured 15 mm in both eyes. Visual acuity was perfect for distance. Intraocular pressure was 12 mmHg in both eyes. Globe movements were free in all directions. Both eyes were unresponsive to 0.1% adrenaline [Figure 2]. The miotic right pupil had a positive response to topical 0.5% apraclonidine (Iopidine; Alcon, Fort Worth, Texas, USA) [Figure 3]. Preganglionic HS was diagnosed with these findings. The Horner pupil becomes dilated with apraclonidine because of the denervation hypersensitivity to alpha agonists. In a preganglionic lesion and normal eyes, the pupil will not dilate with diluted adrenalin because adrenaline is rapidly destroyed by monoamine oxidase, while the postganglionic Horner pupil will dilate because of the absence of monoamine oxidase in the destroyed neuron.

Department of Ophthalmology,
Sütcü Imam University, Faculty
of Medicine KSU Faculty of
Medical, Kahramanmaraş,
Turkey

Address for correspondence:

Prof. Murat Aslankurt,
Department of Ophthalmology,
Sutcu Imam University
Faculty of Medicine, 46050,
Kahramanmaraş, Turkey.
E-mail: maslankurt80@
hotmail.com

Submitted: 11-Aug-2019

Revised: 10-Dec-2019

Accepted: 06-Jan-2020

Published: 29-Jul-2021

This is an open access journal, and articles are distributed under the terms of the Creative Commons Attribution-NonCommercial-ShareAlike 4.0 License, which allows others to remix, tweak, and build upon the work non-commercially, as long as appropriate credit is given and the new creations are licensed under the identical terms.

For reprints contact: WKHLRPMedknow_reprints@wolterskluwer.com

How to cite this article: Aslankurt M, Aslan L. Horner's syndrome secondary to heart surgery in a pediatric patient. Saudi J Ophthalmol 2020;34:303-5.

The medical history revealed the patient had undergone a heart surgery with median sternotomy approach for a ventricular septal defect, and also a diagnosis of an aortic and mitral valve failure. It was learned from medical records that the aortic valve was repaired through an aortotomy, while the mitral valve was repaired via a left atriotomy, the operation terminated with right thoracic and mediastinal drainage tubes performed in a cardiovascular surgery clinic. Drains were removed at the postoperative second day and the pacemaker implantation was done due to third-degree AV block [Figure 4].

Any improvement in the patient's Horner's symptoms was not observed in the 2-month follow-up period.

DISCUSSIONS

In the present case, ptosis and miosis findings were present. The diagnosis was made by pharmacological tests. Ipsilateral anhidrosis, flushing, and conjunctival hyperemia were not observed in this case. These findings, which are usually observed more frequently in the acute phase, were probably absent because the patient presented 2 months after surgery.

Another finding was the accommodation changes. Accommodation is a reflex action carried out by the parasympathetic system. Inclusion of the sympathetic system has with accommodation

changes have been reported in HS cases. However, no accommodation changes were observed in our case.^[2]

Cocaine is highly effective in confirming the diagnosis of HS. Difficulty in obtaining and storing the controlled drug renders this impractical in our clinical settings. Instead, we preferred apraclonidine at a concentration of 0.5% to the recommended 4% cocaine in the diagnostic tests. It has also been shown in a study that the drug had sensitivity and specificity at least similar to cocaine.^[3] During all examinations and during the adrenaline test, the right pupillary diameter remained smaller than the healthy left eye pupil size. After the apraclonidine administration, it became more dilated than the unaffected eye.

Only one case of HS following heart surgery in pediatric patients has been reported in the literature. The case was a left retroesophageal subclavian artery, and patent ductus arteriosus repair through a posterolateral thoracotomy in a 2-month-old girl.^[4] The case differed from our present case in the fact that both having been subjected to thoracotomy that requires working closely to the upper mediastinum and left pleural apex.

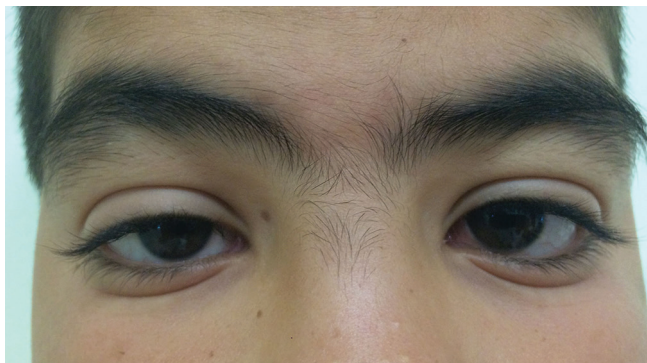

Figure 1: The clinical appearance of the case

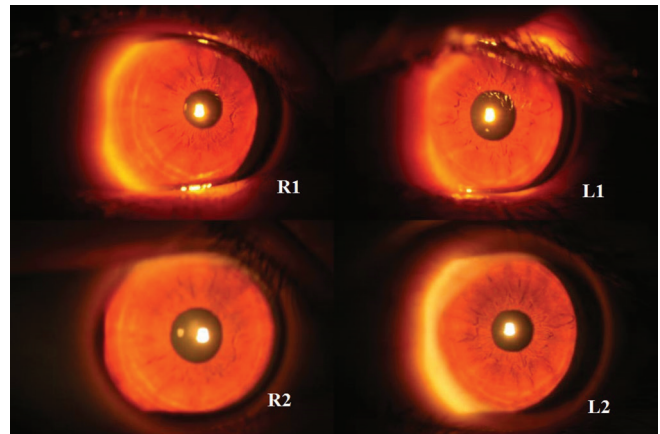


Figure 2: Adrenalin test. biomicroscopic appearance of the pupil: R1, L1 pretest and R2, L2 after 0.1% adrenaline drops

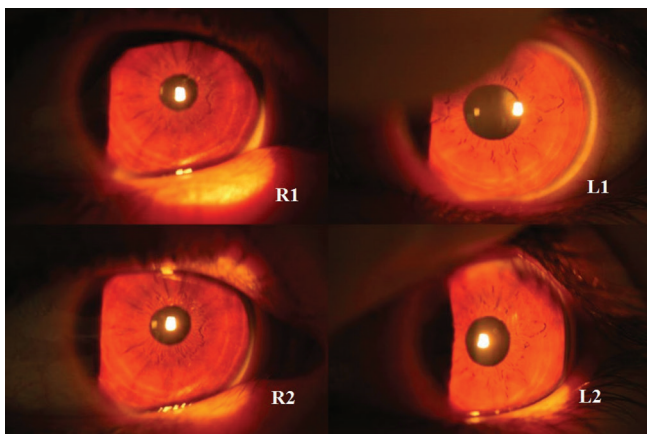


Figure 3: Apraclonidine test. Biomicroscopic appearance of the pupil: R1, L1 pretest and R2, L2 after 0.5% apraclonidine drops

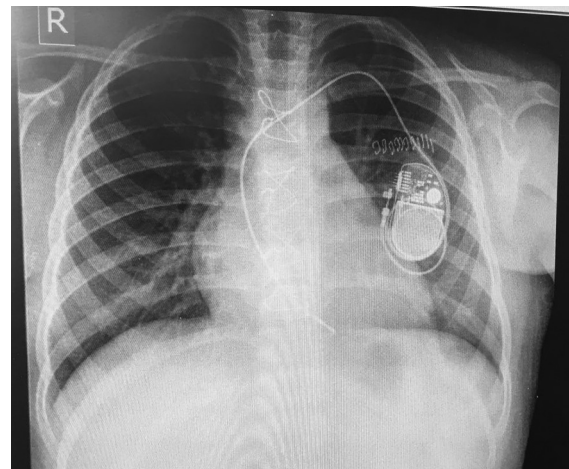


Figure 4: The appearance of the pacemaker in chest X-ray

Oculo-sympathetic nerve injury due to cardiac surgery can be explained by several different mechanisms. One of these is the damage to the cervical sympathetic chain during jugular vein cannulation before or during the operation. Horner's cases, which develop after jugular vein catheterization in intensive care patients, have been commonly reported.^[5-7] Unlike Nasser *et al.*, case,^[4] jugular vein cannulation was not used in the present case as the central line. Extracorporeal circulation (ECC), were provided with cannulation to the aortic root for the arterial system and the superior and inferior vena cava for the venous system.

Considering the fact that the thymus tissue develops in our patient's age group, the upper mediastinal dissection to access the pericardium and great vessels, may be the reason for the damage to the sympathetic fibers. In our case, there had been no major arterial surgery. However, sympathetic damage may have occurred during ECC cannulation or aortic valve repair procedure through aortotomy. In fact, in a series of repair of aortic aneurysm secondary to aortic coarctation, although procedures were made endovascular, HS has been reported to develop in approximately 30% of patients.^[8]

Another possible reason is the damage of the drainage tube, which was left at the end of operations with direct pressure on the nerve leading to inflammation or neuropraxia. There are many reports about HS caused by the chest tube, especially those placed on a higher level of the second intercostal space.^[9-11] They are predominantly externally mounted tubes in thoracic surgery clinics due to pneumothorax, hemothorax, and other similar states. If removed or repositioned at an appropriate level, it has been reported that sympathetic paralysis symptoms recovered partially or complete in the majority of the cases. Although two drainage tubes-a right thoracic and a mediastinal space, was inserted in the present case, the likelihood of sympathetic damage is low because the tubes are inserted under direct sighting in the open heart surgery and the patient does not show any improvement in Horner's findings after its removal on the second postoperative day.

Venous catheterization, mediastinal dissection, great vessel operations in the upper mediastinum, and drainage tubes at the inappropriate location may cause HS in patients with cardiac surgery. Considering the fact that the surgical space

is narrow in pediatric cases and the anatomical variations, careful surgical dissection and avoidance of excessive traction and cauterization may help to prevent the development of this complication.

Declaration of patient consent

The authors certify that they have obtained all appropriate patient consent forms. In the form the patient (s) has/have given his/her/their consent for his/her/their images and other clinical information to be reported in the journal. The patients understand that their names and initials will not be published and due efforts will be made to conceal their identity, but anonymity cannot be guaranteed.

Financial support and sponsorship

Nil.

Conflicts of interest

There are no conflicts of interest.

REFERENCES

1. Kanski JJ. Clinical Ophthalmology. A Systemic Approach. 7th ed. Philadelphia, PA, USA.: International Edition Elsevier; 2011. p. 804-7.
2. Gilmartin B. Review of the role of sympathetic innervation of the ciliary muscle in ocular accommodation. *Ophthalmol Physiol Opt* 1986;6:23-7.
3. Koc F, Kavuncu S, Kansu T, Acaroglu G, Firat E. The sensitivity and specificity of 0.5% apraclonidine in the diagnosis of oculosympathetic paresis. *Br J Ophthalmol* 2005;89:1442-4.
4. Nasser BA, Mesned A, Moazamy YE, Kabbani MS. Horner's syndrome after paediatric cardiac surgery: Case report and review of the literature. *Cardiol Young* 2015;25:569-72.
5. Büyüktortop N, Gürbüz-Köz O, Atalay T, Kural G. A case of postganglionic Horner syndrome after catheterization of internal jugular vein confirmed with pharmacological tests. *Turk J Pediatr* 2008;50:391-4.
6. Ford S, Lauder G. Case report of Horner's syndrome complicating internal jugular venous cannulation in a child. *Paediatr Anaesth* 2007;17:396-8.
7. Williams MA, McAvoy C, Sharkey JA. Horner's syndrome following attempted internal jugular venous cannulation. *Eye (Lond)* 2004;18:104-6.
8. Yazar O, Budts W, Maleux G, Houthoofd S, Daenens K, Fourneau I. Thoracic endovascular aortic repair for treatment of late complications after aortic coarctation repair. *Ann Vasc Surg* 2011;25:1005-11.
9. Levy M, Newman-Toker D. Reversible chest tube horner syndrome. *J Neuroophthalmol* 2008;28:212-3.
10. Kaya SO, Liman ST, Bir LS, Yuncu G, Erbay HR, Unsal S. Horner's syndrome as a complication in thoracic surgical practice. *Eur J Cardiothorac Surg* 2003;24:1025-8.
11. Shen SY, Liang BC. Horner's syndrome following chest drain migration in the treatment of pneumothorax. *Eye (Lond)* 2003;17:785-8.