

## CASE REPORT

## Metastatic right ventricular mass with intracavitary obliteration

Kavitha Kalvakuri, MD<sup>1,2</sup>, Sandeep Banga, MD<sup>1,2\*</sup>, Nalinee Upalakalin, MD<sup>3</sup>, Crystal Shaw, MD<sup>2</sup>, Wilmer Fernando Davila, BSc<sup>2</sup> and Sudhir Mungee, MD, FACC, FSCAI<sup>1,2</sup>

<sup>1</sup>Division of Cardiovascular Medicine, University of Illinois College of Medicine at Peoria, OSF Saint Francis Medical Center, Peoria, IL, USA; <sup>2</sup>Department of Internal Medicine, University of Illinois College of Medicine at Peoria, Peoria, IL, USA; <sup>3</sup>Department of Pathology, University of Illinois College of Medicine at Peoria, Peoria, IL, USA

Metastatic cardiac tumors are more common than the primary cardiac tumors. Cervical cancer metastasizing outside of the pelvis is commonly spread to the lungs, liver, bones and lymph nodes than to the heart. Right-sided metastasis to the heart is more common than to the left side. Intramural spread is more common than intracavitary growth of metastatic cardiac tumors leading to delayed clinical presentation. Intracavitary mass can be confused with intracavitary thrombus which can be seen in the setting of pulmonary embolism. Transthoracic echocardiography plays a major role in the decision making and management of pulmonary embolism, and this modality can also be used to diagnose cardiac masses. Other modalities like TEE, cardiac CT, cardiac MRI and PET-CT scan have further utility in delineating these masses. This may help to plan appropriate management of the right ventricular mass particularly in cases where the patient history and CT pulmonary angiography results favor the diagnosis of pulmonary embolism. We present the case of a 49-year-old woman with a history of supracervical hysterectomy and salpingo-oophorectomy on oral estrogen therapy who was admitted with complaints of pleuritic chest pain and respiratory insufficiency after a long flight. Initial work-up showed sub-segmental pulmonary embolus in the right posterior lower lobe pulmonary artery, and the patient was managed on intravenous heparin. Lack of appropriate response to standard therapy led to further evaluation. Multimodality imaging and biopsies revealed a large right intracavitary ventricular metastatic squamous cell tumor, with the cervix as the primary source.

Keywords: *metastatic right ventricular mass; pulmonary embolism*

\*Correspondence to: Sandeep Banga, Department of Internal Medicine, University of Illinois College of Medicine at Peoria, 530 NE Glen Oak Ave., Peoria, IL 61637, USA, Email: drsbanga@uicomp.uic.edu

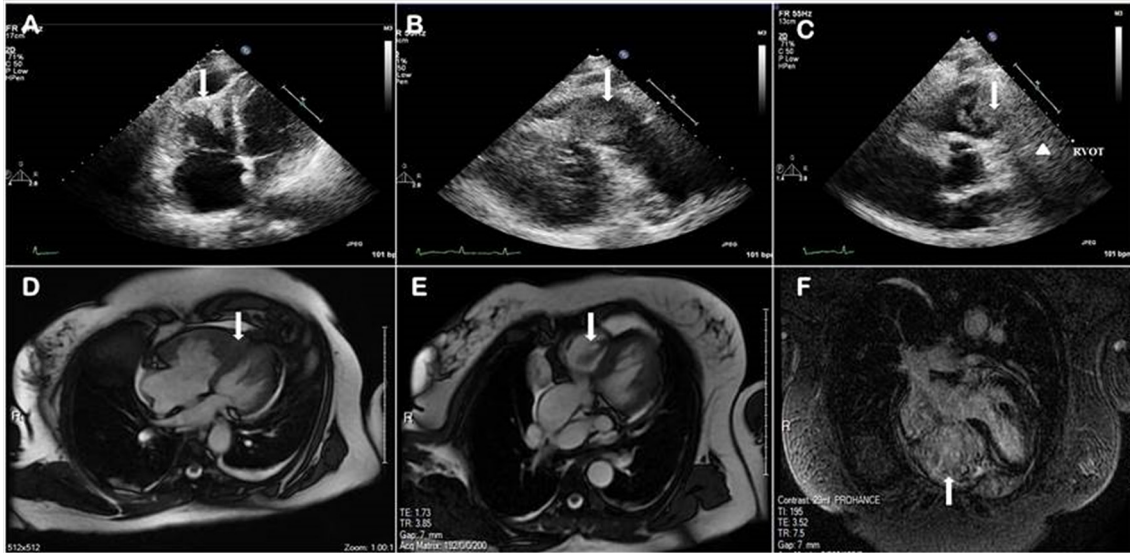
Received: 21 March 2016; Accepted: 22 April 2016; Published: 6 July 2016

The frequency of a primary cardiac tumor is extremely low, accounting for 0.001–0.03% of all cardiac malignancies (1). Metastatic tumors are 30 times more common than the primary tumor of the heart (2). Autopsy series reported lung cancer to be having the highest incidence of metastasis to the heart followed by hematological malignancies and breast cancer (3). Although the overall incidence of malignant melanoma is low, it has the highest tendency to metastasize to the heart (4). Metastasis from gynecological malignancies is not common; furthermore, metastasis from cervical carcinoma is rare. Cervical cancer screening with Papanicolaou test smear is well known for early recognition and prompt management of cervical cancer, which decreases the incidence of morbidity and mortality. Large metastatic cardiac tumor obliterating the right

ventricular cavity was not commonly described and should be considered when evaluating female patients with pulmonary thromboembolism that does not respond to standard guideline-based therapy.

### Case description

A 49-year-old female who was a known smoker and on estrogen supplements presented to the emergency department with acute chronic shortness of breath ongoing for the past 6 months. Her shortness of breath was associated with brief episodes of pleuritic chest pain for the past 2 weeks. She also had three long airplane rides for the past 2 weeks. She had no known prior thromboembolic disease. She denied cough, fever, abdominal pain, nausea, or vomiting. She had a history of robotic supracervical hysterectomy, bilateral salpingectomy, and left oophorectomy



**Fig. 1.** (A) Apical four-chamber echocardiogram showing mass at the right ventricular apex (arrow) with small loculated pericardial effusion. (B) Echocardiogram (RVOT view) showing right ventricular mass in the right ventricular cavity. (C) Echocardiogram in short-axis view showing mass extending from the right ventricular cavity (arrow) to the right ventricular outflow tract (arrowhead). (D) Cardiac MRI oblique four-chamber view with gadolinium contrast showing obliteration of the right ventricular apex (arrow). (E) Cardiac MRI oblique five-chamber view in transverse section with horizontal long axis on gadolinium contrast showing intracavitary mass (arrow). (F) Cardiac MRI showing right ventricular (arrow) and right atrial enlargement.

for menometrorrhagia and left ovarian cyst. The patient had a positive family history of lung cancer in her mother and brother.

Her vital signs were: BP 152/106, pulse rate 113 BPM, afebrile and SpO<sub>2</sub> of 97% on 3 L/min Oxygen via nasal canula with a respiratory rate of 19/min. Her BMI was 28.31 kg/m<sup>2</sup>. On examination, she was in mild respiratory distress, with normal cardio-respiratory findings. She had left leg swelling with pedal edema.

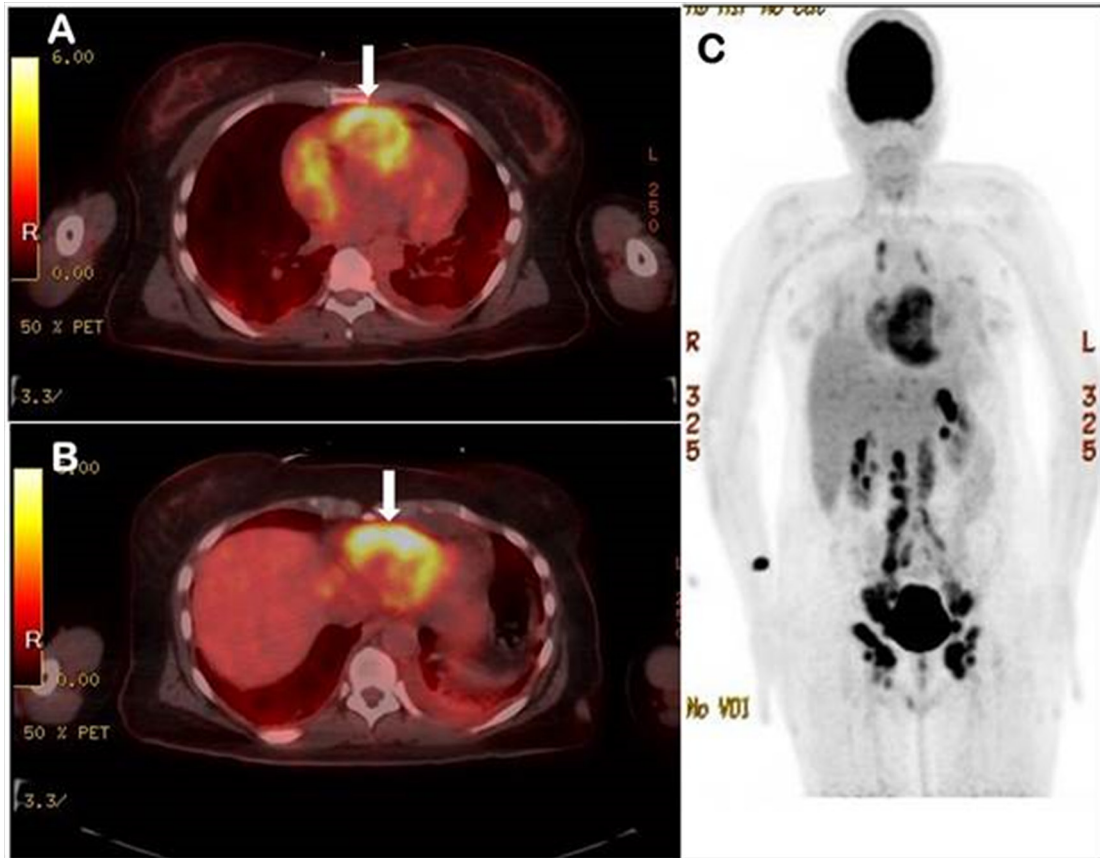
Her initial work-up, including complete blood count (CBC) and basic metabolic profile (BMP), was normal. EKG showed sinus tachycardia, Troponin I was 0.02 ng/ml, and chest X-ray showed an ill-defined nodular opacity in the right mid-lung. Her brain natriuretic peptide (BNP) was elevated at 308 pg/ml. The patient was started on unfractionated heparin (UHF) infusion, with pulmonary embolism suspected.

CT pulmonary angiography showed sub-segmental pulmonary embolus in the right posterior lower lobe pulmonary artery, multiple irregular non-calcified lung nodules suspicious for metastatic neoplasm, and a filling defect within the right ventricle representing either thrombus or an infiltrating mass. The duplex ultrasound of lower extremities venous system showed clots in both popliteal veins below the level of the knees. An echocardiogram revealed normal left ventricle function with ejection fraction of 50%, hypokinetic right ventricle with a thrombus or mass in the right ventricle extending to the outflow tract, and moderate tricuspid regurgitation with right ventricular systolic pressure (RVSP) of 51 mmHg.

Right atrium was dilated and also showed small loculated pericardial effusion at right ventricle apex (Fig. 1A–1C).

Cardiac MRI findings were most consistent with a combination of tumor and thrombus within the right ventricle (Fig. 1D–1F). Full four-chamber fast imaging employing steady-state acquisition (FIESTA) sequence demonstrated a probable mobile thrombus extending to the pulmonary outflow tract to the level of the pulmonic valve. The PET-CT findings showed hypermetabolic activity throughout the right ventricle and to a lesser extent in the right atrium, with minimal uptake in the left ventricle. However, there appeared to be a more focal uptake in the sub-valvular region and near the pulmonary outflow tract, in the areas of concern raised on the MRI (Fig. 2A–2B). The findings also revealed enlarged and hypermetabolic lymph nodes almost diffusely throughout the retroperitoneum and bilateral inguinal regions (Fig. 2C). The possibility of right heart strain with concomitant malignant involvement of the myocardium was also considered.

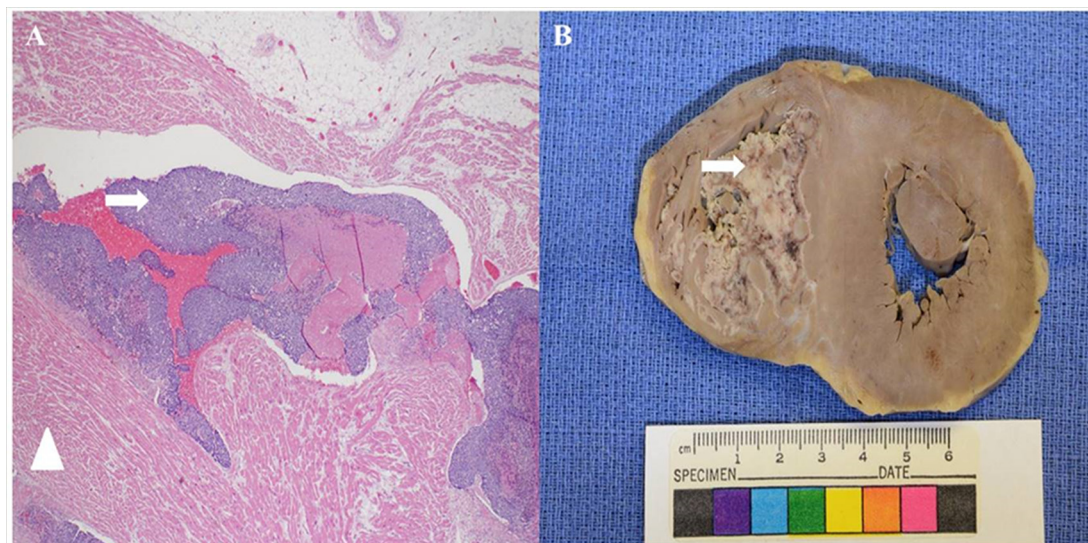
A US-guided biopsy of a right inguinal node was conducted preliminarily to look for any malignancy. Histopathology of lymph node showed squamous cell carcinoma. Oncology was consulted. She was scheduled for resection of right ventricular mass. She became acutely hypotensive and hypoxic, developed pulseless electrical activity (PEA), and did not respond to resuscitation. She was pronounced dead on day six of hospitalization. On autopsy, sectioning the heart revealed a tan mass in the right ventricle measuring 8 × 4 × 2.5 cm. The mass occupied nearly the entire right ventricle, invading the



*Fig. 2.* (A) PET-CT transverse image showing radiotracer uptake in right ventricular apex and right atrium at T4 level. (B) PET-CT transverse image showing radiotracer uptake in right ventricular apex (arrow) at T3 level. (C) PET-CT nuclear scan showing metastatic areas to heart, brain, bilateral paraaortic lymph nodes, and the pelvic region.

ventricular wall and involved the tricuspid valve with the right ventricular outflow tract; histopathology revealed metastatic poorly differentiated invasive squamous cell

carcinoma, most likely originating from the uterine cervix (Fig. 3A–3B). Tumor in the cervix measured 3 cm in greatest dimension.



*Fig. 3.* (A) Microscopic histopathology shows hypercellular neoplastic squamous cells (arrow) and normal myocardial tissue (arrowhead). (B) Gross transverse section of the heart with tumor filling right ventricle (arrow).

## Discussion

Metastasis from gynecological malignancies is rare; furthermore, metastasis from cervical carcinoma is extremely rare. Cervical cancer metastasizing outside of the pelvis is commonly found to spread to the lungs, liver, bones, and lymph nodes but rarely found in the heart. A report shows that only 10.7% cases had metastasis to the heart among 1,029 autopsies of all malignancies, of which only two cases had metastasis to the heart with primary cervical squamous cell carcinoma (5).

Tumors can reach the heart via four pathways: hematogenous spread, lymphatic spread, trans-venous extension, and direct extension (6). Pericardium is the most frequently involved site of cardiac metastasis (64–69%) followed by epicardial involvement (25–34%) and myocardial involvement (29–32%) in descending order. Endocardial and intracavitary metastases are rare, making up 3–5% of cardiac metastases on autopsy as seen in two autopsy series (3, 4). The presentation may vary from non-specific symptoms including chest pain, malaise, weight loss, or features of congestive heart failure secondary to intracardiac obstruction, valvular involvement, or clinical features of pericardial effusion (7). Less commonly, the patients present with arrhythmias due to involvement of conduction system, or embolic events as seen in our case. When the symptoms are out of proportion to the thrombus burden, it is essential to conduct a thorough and prompt investigation to assess for additional factors.

Dyspnea secondary to pulmonary emboli is not an uncommon presentation. It is important to treat patients with stringent protocols and thorough investigations. In our patient, the diagnosis of pulmonary thromboembolism was not surprising, considering her risk factors of prolonged immobility, hormone replacement therapy, and smoking. Our patient had evidence of a pulmonary embolism demonstrated by CT angiography. The patient further decompensated despite recommended therapy. This prompted further investigation with echocardiography, cardiac MRI and PET-CT scanning which revealed a combination of tumor and thrombus.

The clinical presentation in our patient was mimicking pulmonary embolism; however, the discrepancy in clinical course and imaging findings on CT angiography (CTA) led to further investigation. MRI is one of the useful modalities to distinguish a clot from a right ventricular mass which in turn prompts surgical opinion. PET-CT further confirmed the diagnosis of right ventricular mass. Our patient demonstrated a clot superimposed on a squamous cell carcinomatous mass in the right ventricle in all imaging studies.

The prognosis of cardiac metastasis is poor with an average life expectancy less than 6 months after diagnosis (8). In the review of 37 cases by Okamoto et al., in which cardiac metastasis from cervical carcinoma was found

before death, chest symptoms were seen in 81.5% of the patients (8). Although patients have poor prognosis as no well-defined protocol for treatment is available, their immediate outcome can be improved with open-heart surgery and tumor resection as seen in few cases in the past (9, 10). Okamoto et al. concluded that a multimodality approach is necessary for early diagnosis and prompt action (8).

A metastatic cardiac tumor with primary cervical cancer is not commonly reported. Mechanical obstruction of right ventricular outflow tract is life threatening, whereas prompt recognition with multimodality imaging and surgical resection could be lifesaving.

As there are no guidelines on how to manage a patient with sudden onset of symptoms with an obscure history of cardiac metastasis, we believe prompt surgery for mass resection may be the best therapy to prevent clot migration or intracavitary obstruction. It is also important to educate patients that supracerivical hysterectomy does not preclude screening for cervical cancer.

## Conflicts of interest and funding

All authors have none to report. The authors have not received any funding or benefits from industry or elsewhere to conduct this study.

## References

1. Virmani R, Burke A, Farb A. Atlas of cardiovascular pathology. Philadelphia, PA: Saunders; 1996.
2. Al-Mamgani A, Baartman L, Baaijens M, De Pree I, Incrocci L, Levendag PC. Cardiac metastases. *Int J Clin Oncol* 2008; 13: 369–72.
3. Butany J, Leong SW, Carmichael K, Komeda MA. A 30-year analysis of cardiac neoplasms at autopsy. *Can J Cardiol* 2005; 21: 675–80.
4. Bussani R, De-Giorgio F, Abbate A, Silvestri F. Cardiac metastases. *J Clin Pathol* 2007; 60: 27–34.
5. Klatt EC, Heitz DR. Cardiac metastases. *Cancer* 1990; 65(6): 1456–9.
6. Goldberg AD, Blankstein R, Padera RF. Tumors metastatic to the heart. *Circulation* 2013; 128: 1790–4.
7. Byun SW, Park ST, Ki EY, Song H, Hong SH, Park JS. Intracardiac metastasis from known cervical cancer: A case report and literature review. *World J Surg Oncol* 2013; 11: 107. doi: <http://dx.doi.org/10.1186/1477-7819-11-107>
8. Okamoto K, Kusumoto T, Seki N, Nakamura K, Hiramatsu Y. A case of cardiac metastasis from uterine cervical cancer. *Case Rep Obstet Gynecol* 2015; 2015: 703424. doi: <http://dx.doi.org/10.1155/2015/703424>
9. Nakao Y, Yokoyama M, Yasunaga M, Hara K, Nakahashi H, Iwasaka T. Metastatic tumor extending through the inferior vena cava into the right atrium: A case report of carcinoma of the uterine cervix with para-aortic lymph node metastases. *Int J Gynaecol Cancer* 2006; 16(2): 914–16.
10. Schaefer S, Shohet RV, Nixon JV, Peshock RM. Right ventricular obstruction from cervical carcinoma: A rare, single metastatic site. *Am Heart J* 1987; 113(2 Pt 1): 397–9.