


## CASE REPORT

# First report of a de novo iTTP episode associated with an mRNA-based anti-COVID-19 vaccination

Sévérine de Bruijn<sup>1</sup>  | Marie-Berthe Maes<sup>2</sup>  | Laure De Waele<sup>3</sup>  |  
Karen Vanhoorelbeke<sup>3</sup>  | Alain Gadisseur<sup>1,4</sup> 

<sup>1</sup>Department of Hematology, Antwerp University Hospital, Antwerp, Belgium

<sup>2</sup>Department of Clinical Biology, Antwerp University Hospital, Antwerp, Belgium

<sup>3</sup>Laboratory for Thrombosis Research, Interdisciplinary Research Facility Life Sciences, Catholic University of Leuven, Kortrijk, Belgium

<sup>4</sup>Hemostasis and Thrombosis Research Center, Antwerp University Hospital, Antwerp, Belgium

### Correspondence

Alain Gadisseur, Department of Hematology, Antwerp University Hospital, Antwerp, Belgium.  
Email: alain.gadisseur@uza.be

### Abstract

Thrombotic thrombocytopenic purpura (TTP) is a rare but potentially life-threatening thrombotic microangiopathy, characterized by disseminated thrombus formation in the microvasculature, causing severe organ failure. Immune-mediated TTP (iTTP) is occasionally described after vaccination, especially against viral agents. We report a case of a 38-year-old woman with a de novo iTTP after exposure to the mRNA-based anti-coronavirus disease 2019 (COVID-19) vaccine produced by Pfizer-BioNTech. She presented with increased bruising and petechiae starting 2 weeks after receiving the first dose of the anti-COVID-19 vaccine. Laboratory data revealed a severe ADAMTS13-deficiency in combination with a very high autoantibody titer against ADAMTS13. She was successfully treated with plasma exchange, corticosteroids, rituximab, and caplacizumab. To our knowledge, this is the first case report of iTTP after mRNA-based COVID-19 vaccination in a previously TTP-naïve patient.

### KEYWORDS

corticosteroids, COVID-19, plasmapheresis, purpura, thrombotic thrombocytopenic, vaccination

## 1 | INTRODUCTION

Thrombotic thrombocytopenic purpura (TTP) is a rare but potentially life-threatening thrombotic microangiopathy characterized by disseminated thrombus formation in the microvasculature, leading to microangiopathic hemolytic anemia, profound thrombocytopenia, and organ failure.<sup>1</sup> It is caused by a severe deficiency (activity level  $\leq 10\%$ ) of the von Willebrand factor (VWF)-cleaving protease ADAMTS13. In the more rare congenital TTP, ADAMTS13 deficiency is the result of homozygous or compound heterozygous mutations in the ADAMTS13 gene.<sup>2,3</sup> Predominantly, TTP is the result of immune-mediated inhibition and/or clearance of ADAMTS13

(immune-mediated TTP/iTTP), leading to excessive levels of ultra-large VWF multimers, which are responsible for binding and removal of platelets, and ultimately for microthrombosis and thrombocytopenia.<sup>4,5</sup> Because of diffuse tissue ischemia and organ dysfunction, through scattered microthrombi, particularly affecting brain, heart, and kidneys, iTTP has a mortality rate up to 90% if left untreated. With plasma exchange (PEX) and immunosuppressive strategies as the standard of care, the survival rate improved to  $\geq 80\%$ .<sup>2,6</sup> Immune-mediated TTP mainly affects otherwise young and healthy adults and is characterized by a female-to-male ratio of 2:1 to 3.5:1 with peak incidences in the third to fifth decades of life. The reported annual incidence is between 1.5 and 6.0 cases per million

and an average annual prevalence of 10 cases per million in Europe, accounting for more than 95% of all TTP cases.<sup>6,7</sup>

Several events, including malignancies, pregnancy, medication, viral infections, and vaccinations, can trigger production of anti-ADAMTS13 antibodies. To the best of our knowledge, we describe here the first case report of a de novo iTTP associated with an mRNA-based anti-coronavirus disease 2019 (COVID-19) vaccination.

## 2 | CASE REPORT

A 38-year-old Caucasian female, without significant medical history or medication, was referred to the Hematology department because of progressive thrombocytopenia for 1 week, and spontaneous bruising and petechiae for several weeks. Further anamnesis revealed blurred vision in the left eye for 2 weeks. As a care worker, she had already received both doses of the nucleoside modified mRNA BNT162b2 anti-COVID-19 vaccine (Pfizer-BioNTech, [Comirnaty]), respectively, 6 and 3 weeks earlier. The first bruises had been noticed 2 weeks after the first dose of the vaccination, but these had been ascribed to minor traumas from working in the operating theater, and no further action was taken. However, because of increased bruising after the second dose, blood sampling was done, showing a thrombocytopenia of  $57 \times 10^9/L$ . The thrombocytopenia deepened over the following week and the patient was referred to the Antwerp University Hospital. On referral, apart from diffuse ecchymosis, physical examination was normal. However, ophthalmological examination showed signs of central serous chorioretinopathy, caused by platelet-rich microthrombus formation in the choroid vasculature, as an ocular manifestation related to TTP.<sup>8</sup> Initial blood results were also indicative of TTP, with a PLASMIC score of six.

More extensive workup revealed a severe ADAMTS13 deficiency with undetectable levels of ADAMTS13 enzyme activity (Technozym ADAMTS13 activity ELISA kit; Technoclone), confirming the TTP diagnosis. A very high titer of autoantibodies (106 BU) was measured by a functional Bethesda method and confirmed by a general ADAMT13 inhibitor ELISA (Technozym ADAMTS13 INH ELISA kit; Technoclone) showing an antibody titer of  $>1000$  AU/ml. Epitope mapping revealed a "classical" iTTP immunoprofile with only antibodies against the cysteine/spacer (CS) domains of ADAMTS13.<sup>9</sup> Further analysis revealed an open ADAMTS13 conformation (conformation index [CI]  $> 0.5$ ), both spontaneously (CI 2.94) and after addition of activating anti-CUB1 17G2 antibodies (CI 3.08), which is a hallmark of acute iTTP.<sup>10,11</sup> Antibodies to platelet factor 4-heparin complex were negative, using heparin-induced thrombocytopenia (HIT) testing (HemosIL AcuStar HIT IgG assay, Werfen and Zymutest HIA IgG, Hyphen Biomed), ruling out vaccine-induced prothrombotic immune thrombocytopenia (VIPIT/VITT).

Although the polymerase chain reaction on a nasopharyngeal swab and serum antibodies targeting the nucleocapsid domain (Elecys Anti-severe acute respiratory syndrome coronavirus 2 [SARS-CoV-2] assay, Roche) of SARS-CoV-2 were negative at hospital

### Essentials

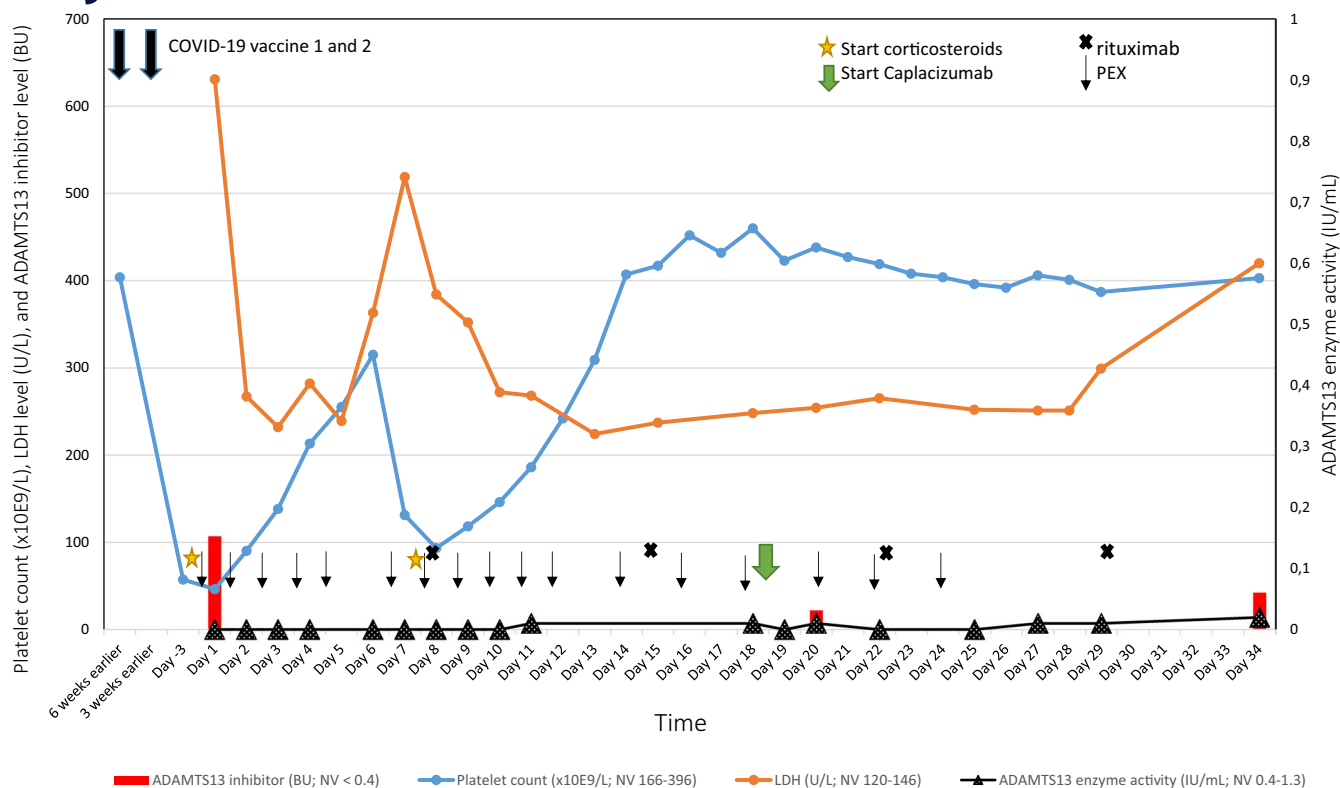
- Potentially fatal iTTP can occur after vaccination with mRNA Covid-19 vaccination.
- VIPIT and iTTP have to be considered in cases of thrombocytopenia and thrombosis after Covid-19 vaccination.

admission, IgG antibodies targeting the S1 receptor binding domain of SARS-CoV-2 (titer 93.8 U/ml; Atellica IM SARS-CoV-2 S assay, Siemens) were remarkably increased. To summarize, the patient had not experienced an active COVID-19 infection, but showed a very high antibody level owing to the recent COVID-19 vaccination.

The patient was urgently admitted for treatment with daily PEX using fresh frozen plasma ( $1.5 \times$  total plasma volume) in combination with methylprednisolone 1000 mg daily for 3 consecutive days. This resulted in prompt normalization of the biochemical parameters, and on day 2 low-dose acetylsalicylic acid was started. Methylprednisolone was stopped on day 3, and on day 5 the daily PEX sessions were reduced to every other day because there were no signs of hemolysis or clinical deterioration and the platelet count was above  $150 \times 10^9/L$  for 2 consecutive days (Figure 1). Unfortunately, on day 8, the platelet count dropped significantly with raised lactate dehydrogenase values, leading to a restart of methylprednisolone 1000 mg daily for 3 consecutive days followed by a corticosteroid tapering schedule, and intensification of PEX therapy (daily) in association with rituximab ( $375 \text{ mg/m}^2$ ) once a week for a total of 4 weeks. This resulted in high and stable thrombocyte levels ( $> 400 \times 10^9/L$ ) but persistently undetectable ADAMTS13 activity. The beneficial effect of PEX was ascribed to removal of ultra-large VWF multimers, rather than to administration of ADAMTS13 in the fresh frozen plasma. PEX was reduced to every other day on day 12 and discontinued on day 25. Given the persistent low ADAMTS13 activity level after 17 PEX sessions, caplacizumab 10 mg was started once daily on day 18, and low-dose acetylsalicylic acid discontinued. On day 20, her titer of autoantibodies had already fallen sharply but still remained high (22 BU). On day 29, after 12 consecutive days of caplacizumab therapy, the patient was discharged from the hospital. Currently, the patient is monitored on an outpatient basis with periodic blood cell counts and is clinically well. However, ADAMTS13 remains undetectable with a high antibody titer (42 BU; Table 1).

## 3 | DISCUSSION

Lately, disturbing hematological phenomena of unusual thromboembolic events and concomitant thrombocytopenia, termed VIPIT/VITT, have been observed after vaccination with the viral vector-based COVID-19 vaccines ChAdOx1 nCoV-19 (AstraZeneca) and Ad26.COV2.S (Johnson & Johnson). This is



**FIGURE 1** Evolution platelet count ( $\times 10^9/L$ ), LDH level (U/L), ADAMTS13 inhibitor level (BU), and ADAMTS13 enzyme activity (IU/ml) starting from day of vaccination and throughout the hospitalization period (d1 = day of admission).

**TABLE 1** Overview of the most important laboratory results arranged chronologically (D1 = day of admission, normal values between brackets)

| Laboratory test                                   | Day 1    | Day 2 | Day 3 | Day 8 | Day 9 | Day 10 | Day 20 | Day 21 | Day 22 | Day 34 |
|---|----------|-------|-------|-------|-------|--------|--------|--------|--------|--------|
| Hemoglobin level (g/dl; NV 11.6–14.4)             | 10.5     | 9.1   | 8.9   | 11.7  | 12.9  | 11.3   | 11.1   | 10.8   | 10.8   | 13.7   |
| Platelet count ( $\times 10^9/L$ ; NV 166–396)    | 46       | 90    | 138   | 93    | 118   | 146    | 438    | 427    | 419    | 403    |
| Leukocyte count ( $\times 10^9/L$ ; NV 4.2–10.3)  | 12.2     | 18.1  | 27    | 20.4  | 33.4  | 20.3   | 22.4   | 20.9   | 20.7   | 18.5   |
| Lymphocyte count ( $\times 10^9/L$ ; NV 4.2–10.3) | 2.03     | 1.3   | 1.89  | 1.53  | 1.2   | 1.4    | 1.9    |        | 2.11   | 0.59   |
| Reticulocyte count ( $\times 10^9/L$ ; NV 24–102) | 263      | 217   | 220   | 283   | 292   | 223    | 111    |        | 108    | 117    |
| Direct antiglobulin test (DAT/direct Coombs)      | Negative |       |       |       |       |        |        |        |        |        |
| Schistocyte count (%; NV < 1)                     | 3        | 3     | 3     | 1     |       | 1      | 0.6    |        | 0.5    | 0.6    |
| D-dimers ( $\mu g/ml$ ; NV < 0.48)                | 1.7      |       | 1.4   | 1.9   | 2.6   | 1.3    | 0.6    |        | 0.6    | 0.2    |
| Haptoglobin level (g/L; NV 0.40–2.80)             | <0.01    | 0.8   | 0.68  | 0.55  | 0.77  | 1.01   |        |        |        |        |
| Creatinine level (mg/dl; NV 0.5–0.8)              | 0.95     | 0.8   | 0.82  | 0.75  | 0.72  | 0.78   | 0.67   | 0.71   | 0.66   | 0.82   |
| LDH (U/L; NV 120–146)                             | 631      | 267   | 232   | 384   | 352   | 272    | 254    |        | 265    | 420    |
| Indirect bilirubin (mg/dl; NV 0.1–1.2)            | 0.63     | 0.44  | 0.23  | 0.29  | 0.29  | 0.22   | 0.22   |        | 0.21   | 0.24   |
| CRP (mg/L; NV < 10.0)                             | 13.9     | 4.8   | <4.0  | 9.7   | <4.0  | <4.0   | <4.0   | <4.0   | <4.0   | <4.0   |
| ADAMTS13 (IU/ml; NV 0.4–1.3)                      | 0        | 0     | 0     | 0     | 0     | 0      | 0.01   |        | 0      | 0.02   |
| ADAMTS13 inhibitor (NV negative or <0.4 BU)       | 106.8    |       |       |       |       |        | 22     |        |        | 42     |

Abbreviations: CRP, C-reactive protein; LDH, lactate dehydrogenase; NV, normal value.

mediated by platelet-activating antibodies against platelet factor 4, clinically resembling autoimmune HIT.<sup>12–15</sup> So far, VITT has not been reported after exposure to the mRNA-based vaccines.

We now describe the first published case of a de novo iTTP after exposure to the mRNA-based vaccine produced by Pfizer-BioNTech (BNT162b2). Interestingly, Sissa *et al.* earlier published

a case of a relapse of iTTP, 6 days after the second dose of the anti-COVID-19 vaccine BNT162b2.<sup>16</sup> Moreover, the UK COVID-19 mRNA Pfizer-BioNTech Vaccine Analysis survey contains five cases of iTTP over a 4-month period, and only one case for the AstraZeneca vaccine, after a combined total of more than 40 million vaccine doses given. Furthermore, the Vaccine Adverse Event Reporting system in the United States managed by the Food and Drug Administration and Centers for Disease Control and Prevention, contains six cases of vaccine-related TTP (two fatal) as of the first of January 2021, all after the anti-COVID-19 vaccine produced by Pfizer-BioNTech. Eventually, a case of an iTTP episode 37 days after receiving the Ad26.COVS COVID-19 vaccine has recently been published.<sup>17</sup>

The pathophysiology of vaccine-related thrombotic microangiopathies is not entirely clear. Already in 1960, Frick *et al.* reported a TTP episode 24 h after typhoid vaccination, suggesting vaccination as triggering factor.<sup>18</sup> Since then, some rare iTTP episodes have been documented after vaccination, particularly against viral agents.<sup>19-25</sup> The causal association was mainly suggested by the fact that no other underlying precipitating causes were present and because of a clear time correlation. The time from vaccination to onset of TTP was between 5 and 14 days in cases of TTP after influenza vaccination<sup>20,23-25</sup> and 15 days after administration of a rabies vaccine and a 23-valent pneumococcal polysaccharide vaccine.<sup>21,22</sup> In the latter, the authors suggest that polysaccharide antigens present in the pneumococcal vaccine or adjuvants may have contributed to the formation of the inhibitor against ADAMTS13 through cross-reactivity.<sup>22</sup>

In the current case, petechiae/bruising gradually occurred 2 weeks after the first dose of the Pfizer-BioNTech mRNA anti-COVID-19 vaccine. Full diagnosis of iTTP was confirmed 3 weeks after second vaccine by the presence of anti-ADAMTS13 antibodies accompanied by the diagnosis of central serous chorioretinopathy. Epitope mapping only showed presence of anti-CS antibodies, and an immunoprofile not different to “classical” iTTP. To our knowledge, this is the first published case report of iTTP post mRNA-based COVID-19 vaccination in a previously TTP-naïve patient. The lack of other possible causes, the chronological sequence, and the very high autoantibody titer against ADAMTS13 in combination with the remarkably increased level of anti-SARS-CoV-2 IgG antibodies, suggests that the anti-COVID-19 vaccine BNT162b2 is almost certainly the triggering factor in the development of iTTP in this patient. Currently, we are waiting for the results regarding possible cross-reactivity of the anti-CS antibodies and the COVID-19 spike protein.

## ACKNOWLEDGMENTS

The authors acknowledge Dr. Bart Peeters, clinical biologist at the Department of Clinical Biology, for his valuable help regarding the COVID-19 serological test results.

## CONFLICT OF INTEREST

The authors declare that they have no conflict of interest.

## AUTHOR CONTRIBUTIONS

S  verine de Bruijn, Marie-Berthe Maes, and Alain Gadisseur participated in drafting the article. All authors revised the manuscript critically for important intellectual content. Marie-Berthe Maes, Laure De Waele, and Karen Vanhoorelbeke conducted the laboratory assays. Alain Gadisseur provided patient care and initiated extended investigations resulting in the manuscript.

## ORCID

S  verine de Bruijn  <https://orcid.org/0000-0002-6905-650X>

Marie-Berthe Maes  <https://orcid.org/0000-0002-0535-4436>

Laure De Waele  <https://orcid.org/0000-0002-6929-9229>

Karen Vanhoorelbeke  <https://orcid.org/0000-0003-2288-8277>

Alain Gadisseur  <https://orcid.org/0000-0001-9419-8772>

## REFERENCES

- George JN. Clinical practice. Thrombotic thrombocytopenic purpura. *N Engl J Med*. 2006;354(18):1927-1935.
- Kremer Hovinga JA, Coppo P, L  mle B, Moake JL, Miyata T, Vanhoorelbeke K. Thrombotic thrombocytopenic purpura. *Nat Rev Dis Primers*. 2017;3(1):17020.
- Alwan F, Vendramin C, Liesner R, et al. Characterization and treatment of congenital thrombotic thrombocytopenic purpura. *Blood*. 2019;133(15):1644-1651.
- Scully M, Hunt BJ, Benjamin S, et al. Guidelines on the diagnosis and management of thrombotic thrombocytopenic purpura and other thrombotic microangiopathies. *Br J Haematol*. 2012;158(3):323-335.
- Joly BS, Coppo P, Veyradier A. An update on pathogenesis and diagnosis of thrombotic thrombocytopenic purpura. *Expert Rev Hematol*. 2019;12(6):383-395.
- Miesbach W, Menne J, Bommer M, et al. Incidence of acquired thrombotic thrombocytopenic purpura in Germany: a hospital level study. *Orphanet J Rare Dis*. 2019;14(1):260.
- Joly BS, Coppo P, Veyradier A. Thrombotic thrombocytopenic purpura. *Blood*. 2017;129(21):2836-2846.
- Bandara A, Matthias AT. Retinal involvement in acute thrombotic thrombocytopenic purpura: a case report. *BMC Ophthalmol*. 2020;20(1):456.
- Thomas MR, de Groot R, Scully MA, Crawley JT. Pathogenicity of anti-ADAMTS13 autoantibodies in acquired thrombotic thrombocytopenic purpura. *EBioMedicine*. 2015;2(8):942-952.
- Roose E, Schelpe AS, Tellier E, et al. Open ADAMTS13, induced by antibodies, is a biomarker for subclinical immune-mediated thrombotic thrombocytopenic purpura. *Blood*. 2020;136(3):353-361.
- Roose E, Schelpe AS, Joly BS, et al. An open conformation of ADAMTS-13 is a hallmark of acute acquired thrombotic thrombocytopenic purpura. *J Thromb Haemost*. 2018;16(2):378-388.
- Thaler J, Ay C, Gleixner KV, et al. Successful treatment of vaccine-induced prothrombotic immune thrombocytopenia (VIPIT). *J Thromb Haemost*. 2021;19(7):1819-1822. <https://doi.org/10.1111/jth.15346>.
- von Hundelshausen P, Lorenz R, Siess W, Weber C. Vaccine-induced immune thrombotic thrombocytopenia (VITT): targeting pathomechanisms with Bruton tyrosine kinase inhibitors. *Thromb Haemost*. 2021. <https://doi.org/10.1055/a-1481-3039>.
- Greinacher A, Thiele T, Warkentin TE, Weisser K, Kyrle PA, Eichinger S. Thrombotic thrombocytopenia after ChAdOx1 nCov-19 vaccination. *N Engl J Med*. 2021;384(22):2092-2101.
- Kadkhoda K. Post adenoviral-based COVID-19 vaccines thrombosis: a proposed mechanism. *J Thromb Haemost*. 2021;19(7):1831-1832. <https://doi.org/10.1111/jth.15348>.

16. Sissa C, Al-Khaffaf A, Frattini F, et al. Relapse of thrombotic thrombocytopenic purpura after COVID-19 vaccine. *Transfus Apher Sci.* 2021;16:103145. <https://doi.org/10.1016/j.transci.2021.103145>.
17. Yocum A, Simon EL. Thrombotic thrombocytopenic purpura after Ad26.COV2-S vaccination. *Am J Emerg Med.* 2021. <https://doi.org/10.1016/j.ajem.2021.05.001>. [Epub ahead of print.]
18. Frick PGHWH. Simultaneous thrombotic thrombocytopenic purpura and agammaglobulinaemia. *The Lancet.* 1960;276(7165):1401-1402.
19. Yavasoglu I. Vaccination and thrombotic thrombocytopenic purpura. *Turk J Haematol.* 2020;37(3):218-219.
20. Brown RC, Blecher TE, French EA, Toghil PJ. Thrombotic thrombocytopenic purpura after influenza vaccination. *Br Med J.* 1973;2(5861):303.
21. Kadikoylu G, Yavasoglu I, Bolaman Z. Rabies vaccine-associated thrombotic thrombocytopenic purpura. *Transfus Med.* 2014;24(6):428-429.
22. Kojima Y, Ohashi H, Nakamura T, et al. Acute thrombotic thrombocytopenic purpura after pneumococcal vaccination. *Blood Coagul Fibrinolysis.* 2014;25(5):512-514. <https://doi.org/10.1097/mbc.0000000000000058>.
23. Ramakrishnan N, Parker LP. Thrombotic thrombocytopenic purpura following influenza vaccination—a brief case report. *Conn Med.* 1998;62(10):587-588.
24. Dias PJ, Gopal S. Refractory thrombotic thrombocytopenic purpura following influenza vaccination. *Anaesthesia.* 2009;64(4):444-446. <https://doi.org/10.1111/j.1365-2044.2008.05823.x>.
25. Hermann R, Pfeil A, Busch M, et al. Very severe thrombotic thrombocytopenic purpura (TTP) after H1N1 vaccination. *Med Klin (Munich).* 2010;105(9):663-668.

**How to cite this article:** de Bruijn S, Maes M-B, De Waele L, Vanhoorelbeke K, Gadisseur A. First report of a de novo iTTP episode associated with an mRNA-based anti-COVID-19 vaccination. *J Thromb Haemost.* 2021;19:2014–2018. <https://doi.org/10.1111/jth.15418>