



Therapeutic Approach to Pulp Canal Calcification as Sequelae of Dental Avulsion

Lucas Borin MOURA, Bibiana Dalsasso VELASQUES, Luis Fernando Machado SILVEIRA, Josue MARTOS, Cristina Braga XAVIER

ABSTRACT

Tooth avulsion represents the most complicated dental injury, and the classic treatment is tooth replantation. The most common sequelae are pulp canal calcification (PCC) and pulp necrosis. The presence of pulp necrosis after PCC is reported in up to 30% of the cases and is a challenge due to the difficulty of endodontic treatment. This case report describes the surgical treatment of a replanted tooth presenting PCC and periapical pathology eight years after the trauma. An endodontic surgery was performed to remove the apical granuloma, to prepare the apical root, and to seal the apical region with an endodontic cement. In a three-year follow-up, there was an absence of inflammatory signs and symptoms or apical lesion. This report shows the importance of close follow-up after dentoalveolar injuries. After the initial dental trauma and its consequences to pulpal tissues, the executed procedures allowed a favourable outcome.

Keywords: Dental pulp calcification, oral surgery, periapical granuloma, tooth avulsion, tooth replantation

HIGHLIGHTS

- This report presents a successful surgical treatment of a replanted tooth presenting PCC and periapical pathology eight years after trauma.
- The effects and consequences for the pulp tissue after a dental trauma.
- The importance of close follow-up after dentoalveolar injuries.

INTRODUCTION

Dental avulsion represents the most complicated dental injury because the support tissues are damaged and the vascular bundle is ruptured (1). The sequelae may appear immediately or many years after the initial trauma (2). Prognosis is dependent on the characteristics of the teeth and treatment, such as the root formation stage, storage media, time between the trauma

and replantation, duration of splint and presence of associated injuries (1, 3). The most common complications are pulp canal calcification (PCC), pulp necrosis and root resorption (1).

Pulp revascularisation in immature teeth may occur in the absence of infection, particularly if the size of the apical foramen is sufficiently great to allow vascular ingrowth (4). If the revascularisation process is successful or in cases of milder injuries to pulp, regressive pulp changes can occur, resulting in accelerated apposition of new hard tissue inside the root canal (5). PCC is present in about 4%-14% of all replanted teeth (6, 7). This complication is characterised by a yellow discoloration of the dental crown and an irregular deposition of hard tissue inside of the root canal space (7). As reported, PCC causes aesthetic damage due to dental crown discoloration; however, this condition may also result in a negative response to the pulp sensibility test and pulp necrosis with periapical lesion (7).

In the initial phase of PCC, particularly during the first three years, apical pathology is very unlikely. However, the development of pulp necrosis and periapical changes may occur as late complications after several uneventful years (8). Pulpal necrosis affects around 33% of all replanted teeth and is responsible for a larger number of failures, especially in teeth with completely root formation (1, 9). Pulp necrosis after PCC is indicated by periapical bone lesion, is reported in 7%-27% of cases and seems to increase with longer observation periods (5-6).

Please cite this article as: Moura LB, Velasques BD, Silveira LFM, Martos J, Xavier CB. Therapeutic Approach to Pulp Canal Calcification as Sequelae of Dental Avulsion. *Eur Endod J* (2017) 2:12.

From the Department of Oral and Maxillofacial Surgery and Maxillofacial Prosthodontics (L.B.M., C.B.X.), Federal University of Pelotas School of Dentistry, Pelotas, Brazil; Department of Semiology Clinics (L.F.M.S., J.M.), Federal University of Pelotas School of Dentistry, Pelotas, Brazil.

Received 26 November 2016, revision requested 16 January 2017, last revision received 28 February 2017, accepted 10 March 2017.

Published online: 7 June 2017
DOI: 10.5152/eej.2017.16060

This work is licensed under a Creative Commons Attribution-NonCommercial 4.0 International License.



Faced with PCC, clinical signs and symptoms and radiographical evaluation dictate the treatment strategy. Although the vital tooth can be managed with monitoring, especially when complete PCC is present, in early PCC, a prophylactic endodontic treatment can be performed to prevent a difficult late endodontic treatment. However, in non-vital teeth the decision between conventional endodontic treatment and endodontic surgery is made according to the degree of calcification and the difficulty of endodontic treatment (7). This case report describes a surgical treatment of a traumatised tooth presenting PCC and periapical pathology.

CASE PRESENTATION

A seven-year-old male patient suffered dental avulsion of upper central incisors 11 and 21. In anamnesis, the patient described that he had suffered a trauma in an anterior-superior direction due to an accidental impact. The patient kept the teeth stored in dry media for 40 minutes, and an open apex was observed. The replantation procedure was made according to the International Association of Dental Traumatology (IADT) guidelines (3). The adopted protocol was the recommended for avulsed teeth with open apex and stored dry less than 60 minutes, and consisted of: root surface and apical foramen cleaning with saline solution; local anaesthesia; alveolar socket evaluation for alveolar fracture (in the reported case it was not present); clot removal and gentle tooth replantation; no suture was necessary due to lacerations; removal of occlusal trauma; flexible splitting (for two weeks); systemic antibiotics; and antitetanic vaccination.

The immediate post-operative period was uneventful (Figure 1a). At six-month follow-up, there were no signs of necrosis or mobility; however, the patient disappeared and returned to our service after five years (Figure 1b).

At a five-year post-trauma evaluation, total apexification, complete PCC and yellow discoloration of the dental crown were observed in both central incisors, with an inconclusive response to pulp tests (Figure 1c). There were no signs of root resorption or pulp necrosis. After two years, tooth 11 showed a widening of the periodontal ligament space with occlusal trauma. At this moment, the probable cause was eliminated

and the treatment chosen was the observation. However, at eight years post-trauma, a radiographically visible apical lesion was diagnosed, and the tooth did not respond to pulp tests and had light sensitivity to percussion (Figure 2a). Left central incisor 21 showed no lesion, symptomatology or signs of pulp necrosis.

Although radiography showed complete PCC, this exam is not the gold standard. A cone beam computed tomography (CBCT) is the indicated exam to evaluate anatomy of the pulp canal and degree of calcification in detail. However, the CBCT exam was not available in our public service. At this moment, there were two treatment plans: to perform a conventional endodontic treatment or to perform a periapical surgery. Faced with the difficulty of executing conventional endodontic treatment due to the extreme calcification of the root canal and the risk of perforation and/or incomplete endodontic treatment, the clinical treatment plan established was periapical surgery and apical root sealing with MTA-based (MTA, Angelus, Londrina, PR, Brazil) endodontic cement. Also, any marginal bone loss due to perforation would have compromised the tooth because of the reduced root height. The patient was informed about the treatment plan and consented to undergo it.

The surgical procedure was performed under local anaesthesia using mepivacaine 3% with epinephrine 1:100,000. An intrasulcular trapezoidal incision was performed to provide an adequate surgical field and access to the apical area. The flap was reflected and spherical burs #5 (Microdent, São Paulo, Brazil) were used to cut and scrape the bone to access the root apical area of tooth 11 (Figure 2b). Periapical curettage was performed in order to remove granulation tissue (Figures 2bd). Due to the decreased length of the root, only a slight apical wear was performed. To prevent root perforation, preparation and regularisation of the apical cavity were performed until intracanal resistance was felt. Therefore, the preparation was limited to the apical third. Retrograde filling was done with MTA.

The mucoperiosteal flap was sutured in position, and a periapical radiograph was taken to confirm the accuracy of the retrograde filling of tooth 11. The post-operative period was un-

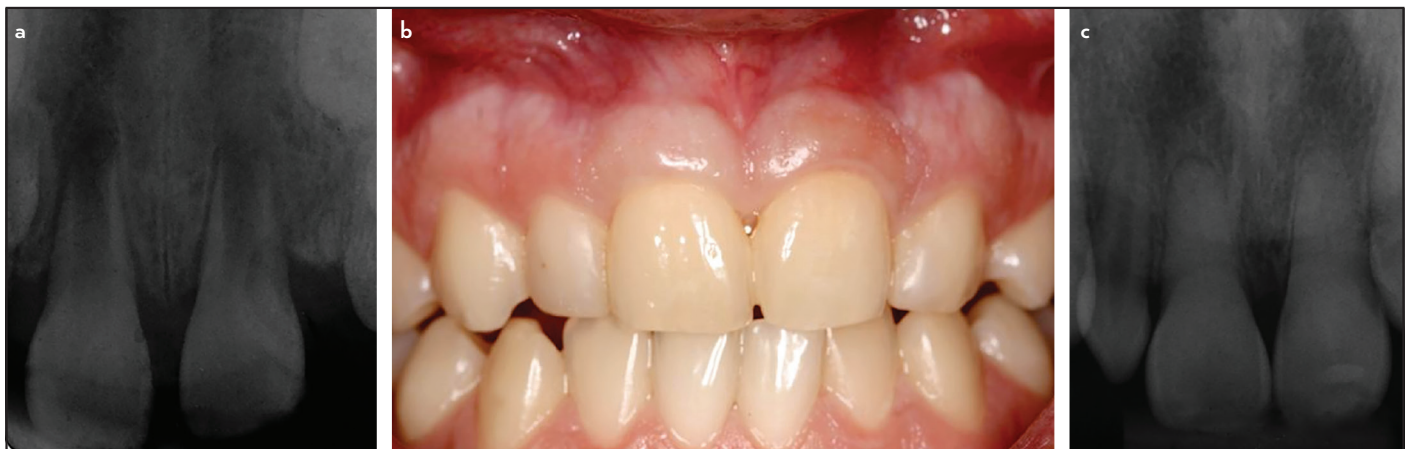

Figure 1. a-c. (a) Initial radiographic exam after dental replantation, (b) clinical aspect of maxillary central incisors at five years post-trauma, (c) radiography evaluation at 60 months

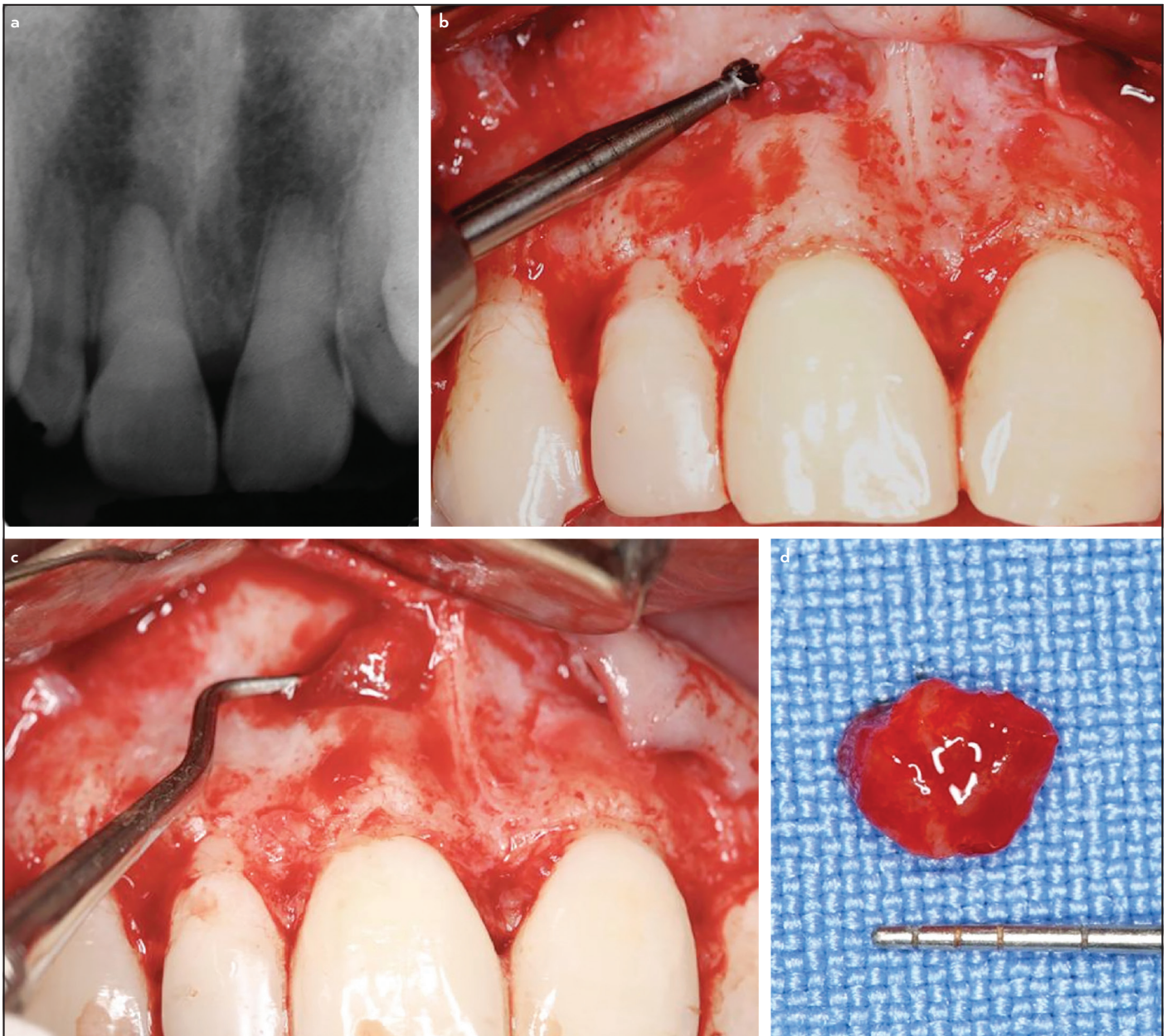


Figure 2. a-d. (a) Radiography at eight years post-trauma, (b) spherical bur to access the root apical area of the 11, (c) apical lesion (granulation tissue) removed from maxillary central incisor, (d) granulation tissue for histopathological analysis

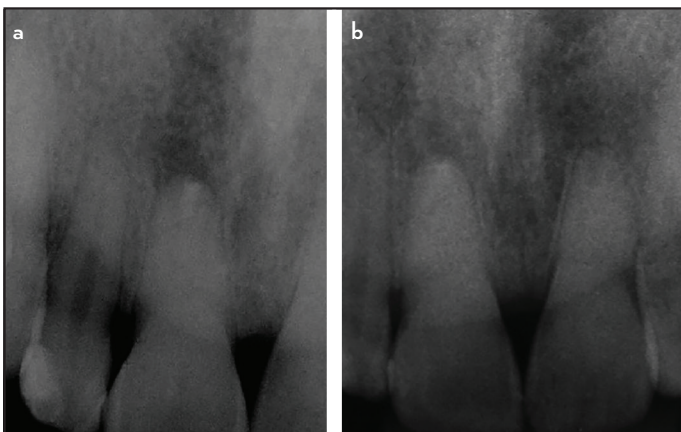


Figure 3. a, b. (a) Radiography at six months after surgical procedure, (b) follow-up radiography at 53 months from surgical procedure

eventful, and the lesion was diagnosed as apical granuloma. In the six-month follow-up, a periapical radiograph showed a slight radiolucency consistent with scar tissue (Figure 3a). At 53 months, no apical lesions, root resorption or bone loss were observed (Figure 3b). In this case report, the periapical surgery was successful. The sensibility disappeared, the lesion decreased and the patient had no complaint. The intraoral evaluation presented periodontal health without mobility or any signs of infection.

DISCUSSION

Dental avulsion has the worst prognosis of all dentoalveolar injuries and represents 3% of these lesions with a high incidence in children between seven to nine years old (10, 11). Even if adequate treatment is performed, a high rate of complications and failures are found (10).

Pulp canal calcification is considered a sign of healing in traumatised teeth; however, due to potential subsequent pulp necrosis, the therapy is widely discussed. The clinical challenge is to perform a prophylactic endodontic therapy in the beginning of PCC before the calcification process makes the root canal difficult to access or to observe until signs and symptoms of pulp necrosis are present (6, 7). In this case, the endodontic therapy was not indicated because the patient was in the rhizogenesis phase, with approximately one-third of the root formed, which could even lead to loss of teeth in a bite support function if root formation was interrupted (3).

Pulp canal calcification may initiate within three months after a dental trauma; however, the dentin deposition on root canal walls commonly is not detected in the first year (1, 7). In the reported case, the patient did not attend post-operative follow-ups in the first five years. When PCC was diagnosed, the root canal was completely filled with dentin, and there was no sign or symptoms of pulpal necrosis, which reinforces the statement that up to one-quarter of all teeth with post-traumatic PCC may develop apical pathology in the long-term.

Usually, the affected teeth are asymptomatic without radiographic changes or sensitivity to percussion. In early stages, vitality tests may be normal; however, in late stages, a negative response is normally present (7, 10). The presence of a negative response of pulp vitality tests, crown discoloration, sensitivity to percussion and apical radiolucency are indicators of pulp necrosis (2, 6, 7, 10). In this case report, both teeth showed inconclusive responses to vitality tests without apical lesions or pulp necrosis symptoms in the first years of evaluation. However, in the eight-year post-trauma follow-up, the patient complained of sensitivity to percussion, and an apical lesion was observed in the radiograph exam, determining pulp necrosis in the upper right central incisor.

A cone beam computed tomography is the best way to determine if the pulp canal is accessible; furthermore, although modern computed tomography scanners use low doses, they are still higher than conventional radiographs (12). Because the diagnosis was made using an image that was not as precise as the CBCT, the decision to perform the surgery was delayed by 1.5 years, during which time we carried out biannual radiographic monitoring and verification of the evolution of apical rarefaction of the right central incisor. It is important to note that the patient always presented with absence of any clinical symptoms.

Pulp necrosis and periapical rarefaction is found in 7%-27% of teeth with PCC. Moreover, the incidence of pulp necrosis is higher in teeth with complete PCC compared with those with partial PCC (7). If complete PCC is present and the conventional endodontic treatment is not possible via traditional endodontic access, endodontic surgery is an alternative treatment. For teeth showing radiographic signs of periapical disease, root canal treatment is indicated; nevertheless, excessive loss of tooth structure and a high risk of perforation may occur in cases of PCC (13). An alternative to orthograde endodontic treatment, apicoectomy with placement of a retrograde filling, may be considered in teeth with PCC and apical pathology. However, identification of the calcified root canal after root-end resection

as well as cleaning of the infected part of the root canal may be challenging in orthograde endodontic treatment.

The filling material chosen was MTA, which has many features including excellent biocompatibility, adhesion, antimicrobial capacity, easy handling and moisture resistance. MTA is the material of choice for root-end, allowing healing and repair of periapical lesions, with an 84-96% success rate in clinical procedures (14). In 53-month radiography, scar tissue can be found associated with a partial apical bone formation with the integrity of the lamina dura. This fact relates to histological findings that show the deposition of cementum on MTA retro-fillings (15).

Although surgical treatment should be considered as a last resource, in our specific case (a traumatised tooth with a small root length and absence of a CBCT exam), the conventional endodontic approach through dental crown was uncertain, and this is one of the classic indications for performing endodontic surgery. The surgical procedure is quite simple and usually results in no complications in the post-operative period. The results in general are quite favourable, with success rates ranging around 95% when an atraumatic surgical technique is performed and new technologies and materials are added to the surgical procedure.

In the last follow-up, the radiographic exam presented scar tissue. This situation was characterised by a decreasing rarefaction with irregular outline. Moreover, the lamina dura may be present between the root apex and the rarefaction. Although it is considered an incomplete healing, the clinical evaluation and radiographic follow-up indicated success. Therefore, cases with scar tissue and no signs and symptoms of inflammation or infection are defined as successful. In our specific case, in a four-year follow-up, the radiographic rarefaction did not increase, which indicates an absence of apical lesions.

CONCLUSION

In conclusion, following the initial dental trauma, its effects and its consequences to the pulp tissue, we can achieve a favourable condition for the patient after all the executed procedures.

Disclosures

Informed Consent: Written informed consent was obtained from patient who participated in this study.

Peer-review: Externally peer-reviewed.

Author Contributions: Concept - L.B.M., L.F.S.M., C.B.X.; Design - L.B.M., B.D.V., J.M., C.B.X.; Supervision - J.M., C.B.X.; Resource - L.B.M., J.M., C.B.X.; Materials - J.M.; Data Collection and/or Processing - B.D.V.; Analysis and/or Interpretation - L.B.M., J.M., C.B.X.; Literature Search - L.B.M., B.D.V.; Writing - L.B.M., B.S.V., J.M., C.B.X.; Critical Reviews - L.F.S.M.

Conflict of Interest: No conflict of interest was declared by the authors.

Financial Disclosure: The authors declared that this study has received no financial support.

REFERENCES

- Soares Ade J, Gomes BP, Zaia AA, Ferraz CC, de Souza-Filho FJ. Relationship between clinical-radiographic evaluation and outcome of teeth re-plantation. *Dent Traumatol* 2008; 24(20):183-8.

2. Rocha Lima TF, Nagata JY, de Souza-Filho FJ, de Jesus Soares A. Post-traumatic complications of severe luxations and replanted teeth. *J Contemp Dent Pract* 2015; 16(1):13-9.
3. Andersson L, Andreasen JO, Day P, Heithersay G, Trope M, Diangelis AJ, et al. International Association of Dental Traumatology guidelines for the management of traumatic dental injuries: 2. Avulsion of permanent teeth. *Dent Traumatol* 2012; 28(2): 88-96.
4. Wang SH, Chung MP, Su WS, Cheng JC, Shieh YS. Continued root formation after replantation and root canal treatment in an avulsed immature permanent tooth: a case report. *Dent Traumatol* 2010; 26(2):182-5.
5. Andreasen FM, Zhijie Y, Thomsen BL, Andersen PK. Occurrence of pulp canal obliteration after luxation injuries in the permanent dentition. *Endod Dent Traumatol* 1987; 3(3): 103-15.
6. Robertson A, Andreasen FM, Bergenholtz G, Andreasen JO, Norén JG. Incidence of pulp necrosis subsequent to pulp canal obliteration from trauma of permanent incisors. *J Endod* 1996; 22(10): 557-60.
7. McCabe PS, Dummer PM. Pulp canal obliteration: an endodontic diagnosis and treatment challenge. *Int Endod J* 2012; 45(2): 177-97.
8. Jacobsen I, Kerekes K. Long-term prognosis of traumatized permanent anterior teeth showing calcifying processes in the pulp cavity. *Scand J Dent Res* 1977; 85(7): 588-98.
9. Andreasen JO. Luxation of permanent teeth due to trauma. A clinical and radiographic follow-up study of 189 injured teeth. *Scand J Dent Res* 1970; 78(3): 273-86.
10. Abd-Elmeguid A, ElSalhy M, Yu DC. Pulp canal obliteration after replantation of avulsed immature teeth: a systematic review. *Dent Traumatol* 2015; 31(6): 437-41.
11. Dewhurst SN, Mason C, Roberts GJ. Emergency treatment of orodental injuries: a review. *Br J Oral Maxillofac Surg* 1998; 36(3): 165-75.
12. Krastl G, Zehnder MS, Connert T, Weiger R, Kühl S. Guided Endodontics: a novel treatment approach for teeth with pulp canal calcification and apical pathology. *Dent Traumatol* 2016; 32(3): 240-6.
13. European Society of Endodontology. Quality guidelines for endodontic treatment: consensus report of the European Society of Endodontology. *Int Endod J* 2006; 39(12): 921-30.
14. von Arx T, Hänni S, Jensen SS. Clinical results with two different methods of root-end preparation and filling in apical surgery: mineral trioxide aggregate and adhesive resin composite. *J Endod* 2010; 36(7): 1122-9.
15. Economides N, Pantelidou O, Kokkas A, Tziafas D. Short-term periradicular tissue response to mineral trioxide aggregate (MTA) as root-end filling material. *Int Endod J* 2003; 36(1): 44-8.