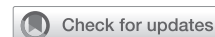

# Early failure of the Trifecta GT bioprosthesis



Lise Tchouta, MD, MSc, Daniel Liesman, BS, Karen Kim, MD, MSc, and Shinichi Fukuhara, MD, Ann Arbor, Mich

From the Department of Cardiac Surgery, University of Michigan Health Systems, Ann Arbor, Mich.

Disclosures: The authors reported no conflicts of interest.

The *Journal* policy requires editors and reviewers to disclose conflicts of interest and to decline handling or reviewing manuscripts for which they may have a conflict of interest. The editors and reviewers of this article have no conflicts of interest.

Received for publication July 29, 2020; revisions received July 29, 2020; accepted for publication Aug 10, 2020; available ahead of print Aug 12, 2020.

Address for reprints: Shinichi Fukuhara, MD, Department of Cardiac Surgery, University of Michigan, 1500 E. Medical Center Dr, Ann Arbor, MI 48109 (E-mail: [fukuhara@med.umich.edu](mailto:fukuhara@med.umich.edu)).

JTCVS Techniques 2020;4:106-8

2666-2507

Copyright © 2020 The Authors. Published by Elsevier Inc. on behalf of The American Association for Thoracic Surgery. This is an open access article under the CC BY-NC-ND license (<http://creativecommons.org/licenses/by-nc-nd/4.0/>).

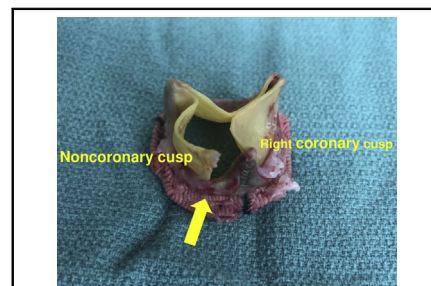
<https://doi.org/10.1016/j.jtc.2020.08.010>

Trifecta bioprosthetic valves with Glide Technology, also known as Trifecta GT (Abbott Vascular, Santa Clara, Calif), were approved by the US Food and Drug Administration in 2016. These are stented valves with a bovine pericardial sheet externally mounted on a titanium stent. There were several reports of early failure involving the first-generation Trifecta that were related to structural valve degeneration secondary to leaflet calcification, pannus formation, and cusps tear presenting less than 7 years after implantation.<sup>1-4</sup> Improvement in the design of Trifecta GT was implemented in response to those vulnerabilities, including Linx anticalcification technology and the Glide Technology for ease of implantation and minimal distortion during implantation.<sup>3</sup> However, despite these changes, we report here 3 cases of early failure involving the newer Trifecta GT.

## CLINICAL SUMMARY

Since the use of Trifecta GT in 2016, we have encountered 3 cases of early failure. Two were implanted at University of Michigan and one at an outside facility. In our own program, 106 Trifecta GTs were implanted between November 2016 and December 2017. The cumulative incidence of valve failure represented 3.3% at 3.5 years after accounting for competing events of prosthetic valve endocarditis (n = 1) and non-cardiac deaths (n = 5).

Written informed consent for publication was obtained from each patient. The mean age at the Trifecta GT implantation was 56.7 years, and 2 were men. Only patient 1 had hypertension and diabetes mellitus. The other 2 patients were otherwise healthy. All patients had a bicuspid aortic valve (Sievers type 1 with fusion of the left and right cusps in all cases). Two were pure stenosis and one was mixed stenosis and aortic insufficiency pathology. Essential clinical data regarding the index Trifecta GT implantation



Explanted Trifecta GT with tear at the stent post between the right and noncoronary cusps.

## CENTRAL MESSAGE

Early failure with cusp fracture was seen in patients with the newer-generation Trifecta GT valves, warranting further investigation.

See Commentary on page 109.

procedure, valve failure, and explantation procedure are summarized in Table 1. These Trifecta GTs were implanted by 3 different surgeons. Valve sizes ranged from 23 to 25 mm, and Cor-Knot (LSI Solutions, Victor, NY) was used in one case. None of implanted valves was oversized. Postoperative course in each case was uneventful.

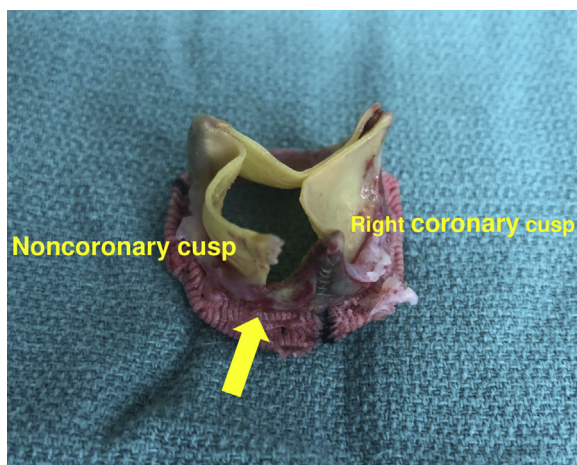
All patients presented with heart failure with newly diagnosed severe aortic insufficiency ranging from 1.9 to 3.2 years after the index procedure. No patients demonstrated clinical signs suspicious for endocarditis. However, due to the extremely sooner-than-expected failure, blood cultures were drawn in all patients to rule out endocarditis and came back negative. All patients underwent redo surgical aortic valve replacement.

Of note, intraoperative findings were consistent with a detached cusp at the stent post between the noncoronary and the right coronary cusps (Figure 1) in all cases. Case 1 also had circumferential pannus formation without significant transvalvular gradient. Leaflets were still pliable without calcifications. Due to the unexpected failure mode with extremely short durability, the explanted Trifecta GTs were sent for culture to rule out occult prosthetic valve endocarditis in 2 patients and both came back

**TABLE 1. Relevant clinical characteristics at index Trifecta GT valve implantation and explantation**

Patient	1	2	3
Age/sex	62 y/male	61 y/female	47 y/male
Year of Trifecta GT implant	2016	2016	2016
Original valve pathology	Bicuspid, AS	Bicuspid, AS	Bicuspid, AS/AI
Body surface area, m <sup>2</sup>	2.27	1.52	1.87
Ascending aorta diameter, mm	35	27	46
Sinus of Valsalva diameter, mm	36	31	38
Annulus diameter, mm	28 × 19	23 × 21	26 × 23
Trifecta GT size, mm	25	23	25
Cor-Knot use	No	No	Yes
Pledget use	Yes	Yes	Yes
Annulus enlargement	Nicks	No	Nicks
Other concomitant procedures	No	No	Ascending aortic replacement
Intraoperative AI	None	None	None
Latest follow-up echocardiography before failure	At 1.6 y Mean gradient 9 mm Hg No AI	At 1.4 y Mean gradient 7 mm Hg No AI	At 3 mo No AI
Year of Trifecta GT explant	2020	2019	2018
Duration between implantation and failure, y	3.2	2.3	1.9
Failure mode	AI	AI	AI
Mean gradient, mm Hg	14	16	20
Notable intraoperative findings	Detached cusp at the stent post between the noncoronary and the right coronary cusps. Circumferential pannus formation.	Detached cusp at the stent post between the noncoronary and the right coronary cusps.	Detached cusp at the stent post between the noncoronary and the right coronary cusps.
Intraoperative culture of the failed Trifecta GT	Negative	Not obtained	Negative

AS, Aortic stenosis; AI, aortic insufficiency; GT, Glide Technology.



**FIGURE 1.** An intraoperative photograph of an explanted 25-mm Trifecta GT (Abbott Vascular, Santa Clara, Calif). There was a detached cusp with a large tear (yellow arrow) at the stent post between the noncoronary cusp and the right coronary cusp. There was no evidence of vegetation or any findings suggestive of prosthetic valve endocarditis.

negative. All patients had an unremarkable postoperative course.

## DISCUSSION

To the best of our knowledge, this represents the first report describing early failure of the newer-generation Trifecta GT. Although an increasing number of studies regarding early failure of the Trifecta have been reported,<sup>1-4</sup> these are exclusively from the results of the first-generation Trifecta. Importantly, the follow-up period of studies with favorable Trifecta results was up to 6 years, whereas studies cautioning the Trifecta durability had more than 7-year follow-up periods.<sup>2,4</sup> In our previous investigation, structural valve degeneration appeared to have occurred abruptly between 5 and 7 years.<sup>2</sup> Some investigators suggest these mixed results might be due to the implant technique causing excessive pressure on the strut base, leading to weakening of the leaflet, oversizing of the valve, or improper Cor-Knot usage causing contact with the

pericardium over time.<sup>5</sup> As mentioned in the present report, these index cases were performed by 3 different surgeons. Cor-Knot was used in only one case. Interestingly, the mode of failure and the location of the cusp tear were identical in all cases. These were common findings in the previous first-generation Trifecta studies.<sup>2</sup>

In the present study, no aortic insufficiency was seen on the index intraoperative or follow-up echocardiograms. While no conclusions can be drawn from this small series, we postulate the unique design of the Trifecta GT might be contributing to the early failure. This is likely multifactorial, including externally mounted leaflet design and mechanical abrasion from the aortic wall at a particular location. The location between the right and noncoronary cusps may represent a specific susceptible anatomic

location. In this context, further investigation with a control group with other stented bioprostheses using standardized methodology is truly needed.

### References

1. Saxena P, Greason KL, Schaff HV. Early structural valve deterioration of the Trifecta aortic valve biological prosthesis: a word of caution. *J Thorac Cardiovasc Surg.* 2014;147:e10-1.
2. Fukuhara S, Shiomi S, Yang B, Kim K, Bolling SF, Haft J, et al. Early structural valve degeneration of trifecta bioprosthesis. *Ann Thorac Surg.* 2020;109:720-7.
3. Eichinger S, Badreldin AMA, Eichinger WB. Early degeneration caused by cusp tear of first-generation trifecta bioprosthesis. *Ann Thorac Surg.* 2018;106:e297-8.
4. Biancari F, Valtola A, Juvonen T, Husso A, Dahlbacka S, Laakso T, et al. Trifecta versus Perimount Magna Ease aortic valve prostheses. *Ann Thorac Surg.* February 12, 2020 [Epub ahead of print].
5. Kilic A. Structural valve deterioration with the trifecta: is it the valve or is it implant technique? *Ann Thorac Surg.* March 5, 2020 [Epub ahead of print].