

Received: 2020.08.20

Accepted: 2020.10.22

Available online: 2020.12.09

Published: 2021.01.24

Traumatic Pneumothorax in a 58-Year-Old Man: A Case Report of a Rare Post-Acupuncture Adverse Event

Authors' Contribution:

Study Design A
Data Collection B
Statistical Analysis C
Data Interpretation D
Manuscript Preparation E
Literature Search F
Funds Collection G

ABCDEF 1,2 **Brittany Smith**
ABCDEF 1,2 **Sungyub Lew**
DEF 1,2 **Prabhjot Manes**

1 Saint George's University School of Medicine, True Blue, Grenada

2 Department of Family Medicine, Brooklyn Hospital Center, Brooklyn, NY, U.S.A.

Corresponding Author: Brittany Smith, e-mail: Bsmith4@sgu.edu**Conflict of interest:** None declared

Patient: Male, 58-year-old
Final Diagnosis: Pneumothorax
Symptoms: Chest pain
Medication: —
Clinical Procedure: Chest tube
Specialty: General and Internal Medicine • Pulmonology

Objective: Unusual clinical course


Background: The prevalence of chronic medical conditions continues to rise, as does the number of patients seeking alternative treatments for them. Chronic pain is a prevalent medical complaint and acupuncture often is used to treat it. The Chinese literature documents several adverse events (AEs) associated with acupuncture, including cardiac tamponade, pneumothorax, infection, and nerve injuries. These complications are rare and may be associated with anatomical characteristics of the patients and deep insertion of the acupuncture needles. Differences in body type, weight, height, sex, and muscle mass contribute to anatomical differences and the depth at which vital organs lie. Having a better understanding of these anatomical differences may alter the occurrence of such AEs.

Case Report: A slim 58-year-old man who was treated for neck pain with acupuncture presented with 2-day history of moderate-severity pleuritic and sharp pain radiating from the left scapula to the midaxillary and retrosternal area. A left-sided pneumothorax was diagnosed on chest X-ray and the patient was treated with a chest tube.

Conclusions: This case underscores that acupuncture can result in complications such as a pneumothorax from puncture of the pleura. These types of AEs from acupuncture can be avoided with a better understanding of anatomical differences, including body mass index and variations in depth associated with body size, musculature, or skeletal structure. When placing the needles, it is crucial for practitioners to know that the depth at which vital organs lie may differ between patients.

MeSH Keywords: Acupuncture • Acupuncture Points • Iatrogenic Disease • Pneumothorax • Body Mass Index • Case Reports

Full-text PDF: <https://www.amjcaserep.com/abstract/index/idArt/928094>




1286



—



2



12



Background

Acupuncture is a well-known, minimally invasive treatment for pain. The technique is predominantly used for headaches and neck and back pain when conventional medical care provides little or no help or if a patient prefers alternative therapy for symptoms. In general, acupuncture has a good safety profile; however, rare adverse events (AEs) have been reported [1]. The Chinese literature documents several severe AEs associated with acupuncture, including spinal cord injury, infection, cardiac tamponade, and pneumothorax. AEs are estimated to occur in 6.71% to 15% of those who receive acupuncture, and in approximately 2.2% of cases, they are severe [2]. Several reports have documented serious injuries associated with acupuncture, one of the most frequent being pneumothorax. This is especially true when patients are being treated for neck, upper back, or shoulder pain [2,3].

Many patients diagnosed with a pneumothorax after acupuncture have few or no comorbidities and present with chest pain and shortness of breath and a body mass index (BMI) in the lower half of the normal range (<22) or below normal (<18.5). In such patients, conservative medical treatment typically is insufficient and thoracostomy tube placement is necessary [3]. Each report in the literature documents a similar trend in anatomical differences in patients and the development of pneumothoraces following acupuncture [2,3]. Understanding how body habitus contributes to risk of AEs from acupuncture can help practitioners prevent these occurrences and enable clinicians to recognize this important history in a patient with chest pain and shortness of breath.

While pneumothorax after acupuncture is a rare AE, its onset tends to be delayed, which can lead to lack of awareness by acupuncturists. With the increasing popularity of alternative medicine, it is crucial that physicians and acupuncturists understand the level of risk associated with the procedure and how a patient's body habitus can contribute to it. The present report is a case of non-tension pneumothorax in a slim 58-year-old man being treated for neck pain with acupuncture.

Case Report

A 58-year-old man with a BMI of 18.6, non-insulin-dependent diabetes mellitus (DM), and sickle cell trait but no history of vaso-occlusive crises or acute chest syndrome presented to the Emergency Department (ED) with a 2-day history of moderately severe pleurisy and sharp pain radiating from the left scapula to the midaxillary and retrosternal area. The patient's symptoms began while he was receiving treatment for neck pain with placement of acupuncture needles and cups on his upper back and around his scapula. He did not present

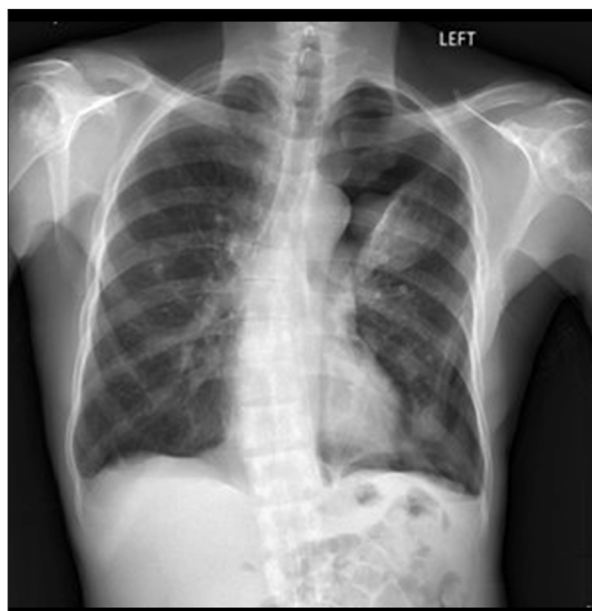


Figure 1. Chest X-ray showing a large left-sided pneumothorax with some associated pleural fluid, left upper-lobe opacity, and round opacity in the anterior aspect of the right upper lobe.

to the ED immediately because he thought what he was experiencing was a normal reaction to acupuncture. His symptoms persisted and he developed mild dyspnea. The patient denied any chest trauma and had never smoked tobacco or used any illicit substances.

On examination, he was alert and speaking in full sentences with no clear signs of respiratory distress. He was normotensive with no tachycardia or tachypnea and his oxygen saturation was maintained on room air. The patient's heart rate and rhythm were normal and he had no murmurs, rubs, or gallops. Examination of his lungs revealed a non-tender chest wall, patent airway, no tracheal deviation, and non-labored respirations. Breath sounds were diminished on the left side, but on the right side, they were clear to auscultation and no intercostal retractions were observed. On the patient's back, there was evidence of ecchymosis from cupping marks.

Initial investigations revealed leukocytosis and mild normocytic anemia. Results of a metabolic panel were within normal limits, except for hyperglycemia, in keeping with the patient's history of DM. His electrocardiogram showed a normal sinus rhythm with normal intervals and no ST-T wave changes. A posteroanterior chest X-ray (**Figure 1**) confirmed the presence of a large left-sided pneumothorax not under tension. On additional questioning, the patient denied any prior history of pneumothorax. He was also not aware that this was a potential complication of acupuncture.

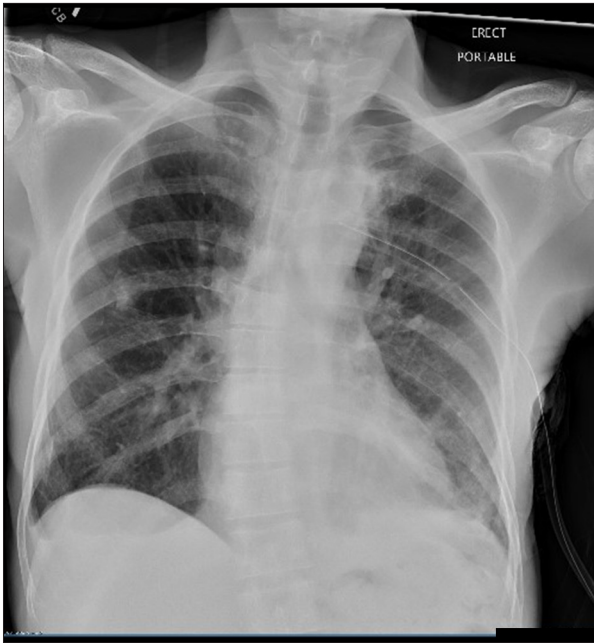

Figure 2. Chest X-ray showing resolution of the pneumothorax after chest tube placement.

Placement of a chest tube resulted in return of breath sounds and good air movement. The patient's vital signs remained stable. A repeat chest X-ray (**Figure 2**) showed resolution of the pneumothorax and re-expansion of the lung. The patient was admitted for chest tube management. On the third hospital day, the tube was removed. On the fourth hospital day, he was discharged home.

Discussion

The present case report discusses a rare but increasingly common AE associated with acupuncture. Acupuncture is performed by inserting fine needles, usually 26- to 32-gauge, into specific sites on the surface of the body. The length of the needles varies from 15 to 50 mm. The depth of insertion varies from a few millimeters to several centimeters, depending on the amount of subcutaneous tissue in the region being manipulated [3]. Acupuncture generally is considered a safe alternative for management of a large variety of conditions and is noted to be increasing in popularity with patients [4–7]. The overall incidence of AEs associated with it is unknown, but systematic reviews indicate that pneumothorax is the most common traumatic injury, and accounts for up to 1% of severe AEs [8–10]. Of the patients who develop a pneumothorax following acupuncture, 2.2% will require a chest tube or hospital admission for management [2].

Patients with acupuncture-associated pneumothorax often have acupuncture needling locations throughout the scapula

and chest [2]. The GB-21 location just medial to the scapula is a common location for placement of an acupuncture needle to treat trapezius muscle spasm and associated neck pain [11,12]. The GB-21 point is associated with up to 64% of acupuncture-induced pneumothoraces [2]. In a study of ultrasound for evaluation of depth from the skin to the pleural line in various patients, the depths of the dominant and non-dominant sides differed, depending on sex, weight, height, and BMI [11]. Sex and BMI also were found to be factors independently associated with the depth of the GB-21 point. Although the study was based exclusively on a Chinese population with normal BMI, there was great variation in the depth of the GB-21 point. Even some participants with higher BMI had very low depth if their muscle mass was very low. If acupuncturists consistently use the same technique without changing the depth of insertion from patient to patient, then the risk of pneumothorax can increase in individuals who have low BMI or muscle mass.

Adequate training and an increased understanding of normal anatomy and anatomical variants ultimately will reduce the incidence of AEs following acupuncture. Our patient had low BMI (18.6) and a slender body habitus, which could have placed him at increased risk for pneumothorax. Anyone who develops chest pain or shortness of breath after an acupuncture procedure should go to the ED immediately and notify their acupuncturist to increase the practitioner's awareness of AEs.

Conclusions

With the increasing use of acupuncture for chronic medical conditions, physicians and practitioners should be aware of potential complications, such as a traumatic pneumothorax. These conditions may be slow to develop or a patient may be unaware of this complication, which can result in a delay in treatment. Further research should be performed to better understand the variation in depth of the pleura and other vital organs and improve the safety of the procedure. Acupuncturists should be aware of the wide variation in depth to vital organs including the lungs, heart, bowel, spinal cord, and nerves, especially in patients with low BMI. Differences in anatomy, including BMI, body size, musculature, and skeletal structure, can alter the depth at which vital organs lie. Having a true understanding of normal anatomy and the anatomical differences between patients can greatly reduce the risk of serious AEs in individuals seeking acupuncture. Physicians also should be aware of these possible AEs following acupuncture and have a high index of suspicion to ensure rapid and appropriate treatment.

Conflicts of interest

None.

References:

1. Mao JJ, Kapur R: Acupuncture in primary care. *Prim Care*, 2010; 37(1): 105–17
2. Zhang J, Shang H, Gao X et al: Acupuncture-related adverse events: A systematic review of the Chinese literature. *Bull World Health Organ*, 2010; 88(12): 915–21C
3. Kim JS, Kim KH, Kim WW: 17 cases of acupuncture related pneumothorax and factors influencing pneumothorax. *Acupunct Electrother Res*, 2016; 41(2): 95–105
4. Petrie JP, Hazleman BL: A controlled study of acupuncture in neck pain. *Br J Rheumatol*, 1986; 25(3): 271–75
5. Motlagh FE, Ibrahim F, Rashid RA et al: Acupuncture therapy for drug addiction. *Chin Med*, 2016; 11: 16
6. Wu J, Yeung AS, Schnyer R et al: Acupuncture for depression: A review of clinical applications. *Can J Psychiatry*, 2012; 57(7): 397–405
7. Grusche F, Egerton-Warburton D: Traumatic pneumothorax following acupuncture: A case series. *Clin Pract Cases Emerg Med*, 2017; 1(1): 31–32
8. Hopton AK, Curnoe S, Kanaan M et al: Acupuncture in practice: Mapping the providers, the patients and the settings in a national cross-sectional survey. *BMJ Open*, 2012; 2(1): e000456
9. Witt CM, Pach D, Brinkhaus B et al: Safety of acupuncture: Results of a prospective observational study with 229,230 patients and introduction of a medical information and consent form. *Forsch Komplementmed*, 2009; 16(2): 91–97
10. Whewey J, Agbabiaka TB, Ernst E: Patient safety incidents from acupuncture treatments: A review of reports to the National Patient Safety Agency. *Int J Risk Saf Med*, 2012; 24(3): 163–69
11. Chen HN, Chang CY, Chen LZ et al: Using ultrasonography measurements to determine the depth of the GB 21 acupoint to prevent pneumothorax. *J Acupunct Meridian Stud*, 2018; 11(6): 355–60
12. McCutcheon L, Yelland M: Iatrogenic pneumothorax: Safety concerns when using acupuncture or dry needling in the thoracic region. *Phys Ther Rev*, 2011; 16(2): 126–32