

Fetal bradycardia associated with left ventricle noncompaction diagnosed as HCN4 mutations

Kosuke Yonehara

Department of Pediatric Cardiology, Nagano Children's Hospital, Nagano, Japan

ABSTRACT

A 35-year-old pregnant woman was referred to our hospital because of fetal bradycardia. Fetal echocardiography revealed a normal fetal heart except for slightly prominent trabeculae in the left ventricle, normal cardiac function, and fetal sinus bradycardia with a heart rate of 100 bpm. Electrocardiography (ECG) after birth revealed sinus bradycardia with a heart rate of 70–80 bpm. Transthoracic echocardiography revealed left ventricular noncompaction localized in the apex with normal cardiac function. A 24-h Holter ECG showed a heart rate range of 62–169 bpm without a pause of more than 2 s. A genome analysis performed during the neonatal period revealed a heterozygous inflame variant p.(Ser672_Asp676del)[chr15:g. 73324203_733242] in HCN4 gene. Fetuses with a heart rate less than the 3rd percentile of the gestational age should be followed and screened for congenital heart disease and cardiomyopathy. In addition, inherited arrhythmia syndrome should be considered.

Keywords: Cardiac channelopathy, fetal echocardiography, HCN4 gene, left ventricle noncompaction cardiomyopathy, sick sinus syndrome

INTRODUCTION

Fetal arrhythmias are reported in 1%–2% of all pregnancies, and most do not require strict follow-up or therapeutic interventions.^[1] Although fetal bradycardia is mainly associated with fetal distress, it can also occur due to congenital heart disease, maternal autoimmune disorders, or long QT syndrome (LQTS). Recently, cases of fetal bradycardia associated with HCN4 mutations have been reported, emphasizing the necessity for close monitoring.^[2,3] Here, we report a case of fetal sinus bradycardia associated with left ventricle noncompaction, with a diagnosis of HCN4 mutation after birth.

CASE REPORT

A 35-year-old pregnant woman was referred to our hospital at 21 weeks of gestation because of fetal bradycardia. The mothers' and fathers' families had no history of

congenital heart disease, cardiomyopathy, or arrhythmia. Routine fetal echocardiography revealed a normal fetal heart except for slightly prominent trabeculae in the left ventricle and normal cardiac function [Figure 1a]. The patient presented with fetal sinus bradycardia with a heart rate of 100 beats/min. No premature contraction of the atrium, ventricle, or atrioventricular block was observed [Figure 1b]. Maternal SS-A and SS-B antibodies were negative. During follow-up, the fetal heart rate was observed to be between 100 and 110 bpm.

The infant was delivered at 38 weeks of gestation. Electrocardiography (ECG) after birth revealed sinus bradycardia with a heart rate of 70–80 bpm, associated with a slightly prolonged QTc of 500. Transthoracic echocardiography showed left ventricular noncompaction (LVNC) localized in the apex with normal

This is an open access journal, and articles are distributed under the terms of the Creative Commons Attribution-NonCommercial-ShareAlike 4.0 License, which allows others to remix, tweak, and build upon the work non-commercially, as long as appropriate credit is given and the new creations are licensed under the identical terms.

For reprints contact: WKHLRPMedknow_reprints@wolterskluwer.com

How to cite this article: Yonehara K. Fetal bradycardia associated with left ventricle noncompaction diagnosed as HCN4 mutations. *Ann Pediatr Card* 2024;17:295-7.

Access this article online

Quick Response Code:



Website:

<https://journals.lww.com/aopc>

DOI:

10.4103/apc.apc_138_24

Address for correspondence: Dr. Kosuke Yonehara, Department of Pediatric Cardiology, Nagano Children's Hospital, Azumino, Nagano 399-8288, Japan.

E-mail: kyonehara19870609@yahoo.co.jp

Submitted: 14-Jul-2024

Revised: 27-Aug-2024

Accepted: 12-Sep-2024

Published: 15-Nov-2024

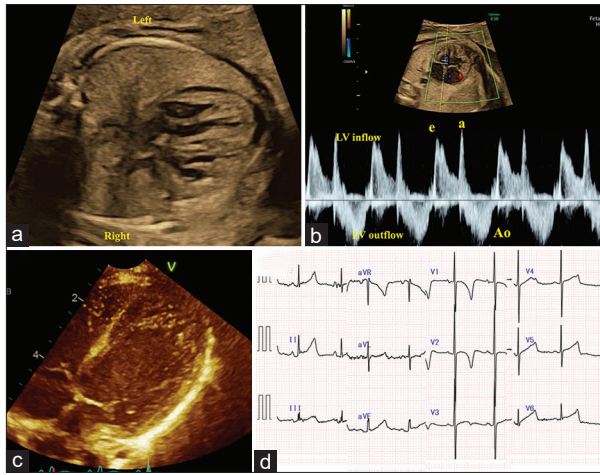


Figure 1: (a) Fetal echocardiography showed a slightly prominent trabeculae. (b) Fetus at 28 weeks gestational age. Pulse Doppler in inflow-outflow of the left ventricle showed sinus rhythm and a fetal heart rate of 91 bpm. (c) Transthoracic echocardiography at 6 months revealed noncompaction of the left ventricle limited in the apex. (d) Electrocardiogram at 6 months showed slightly prolonged QT duration with sinus bradycardia

cardiac function [Figure 1c]. The aortic root was not dilated, and no other congenital heart diseases were observed. A 24-h Holter ECG showed a heart rate range of 62–169 bpm with a mean sinus rate of 98 bpm without a pause of more than 2s.

A genome analysis was performed during the neonatal period, and the heterozygous inflame variant p.(Ser672_Asp676del)[chr15:g. 73324203_733242] in HCN4 was identified. The parents also underwent the same analysis; however, no mutations were observed. Thus, the patient was diagnosed with a *de novo* HCN4 mutation. The child is currently 8 months of age and is doing well without arrhythmia or heart failure. The QTc duration decreased to 400 msec [Figure 1d]. Periodic Holter ECG does not reveal pauses and severe bradycardia.

DISCUSSION

The fetal heart rate is inversely proportional to the gestational age. Fetal bradycardia is traditionally defined as a sustained heart rate of <110 bpm with 1:1 atrioventricular conduction. However, a fetal heart rate less than the 3rd percentile of the gestational age is said to be a more important definition of fetal bradycardia.^[2] In general, fetal bradycardia is considered a marker of LQTS. However, Chaudhry-Waterman *et al.* reported that LQTS, as well as other pathogenic variants, such as RYR2 and HCN4, should be suspected.^[3]

HCN4 encodes hyperpolarization-activated cyclic nucleotide-gated subunit 4, which is 1 of the 4 subunits of the pacemaker “funny” current. HCN4 plays the most crucial role as a channel in the sinoatrial node, being a major decision factor of the cardiac pacemaker

current and playing a vital role in the automaticity of the sinus node through the generation of slow diastolic depolarization during phase four of the cardiac action potential. Thus, this is an important channel for adequate pacemaker activity and conduction system function.^[4] Mutations in the HCN4 gene result in various phenotypes. Brunet-Garcia *et al.* reported a family with HCN4 mutations associated with sinus bradycardia, sick sinus syndrome (SSS), LVNC, and aortic dilation.^[5] Ishikawa *et al.* studied familial SSS cases and reported that SSS patients with HCN4 mutations have early clinical manifestations after adolescence and frequent associations with atrial fibrillation and LVNC.^[6] A small number of cases of fetal bradycardia have been reported to be diagnosed with HCN4 mutations. Wacker-Gusmann *et al.* reported two cases of fetal bradycardia: one patient presented with sinus bradycardia with a heart rate of 118 bpm, and the other patient presented with sinus bradycardia with nonsustained atrial flutter.^[2] Chaudhry-Waterman *et al.* reported 18 cases of fetal bradycardia, two of which were diagnosed as HCN4 mutations associated with ventricular septal defects and LVNC.^[3] In our case, fetal bradycardia was the first finding, and an asymptomatic LVNC was also diagnosed by echocardiography. Owing to the genome analysis, the patient was successfully followed up appropriately. In addition, it is noteworthy that the variant in this case has not been reported so far.

LVNC in children is often accompanied with arrhythmias, including supraventricular tachycardia and sustained or nonsustained ventricular tachycardia.^[7] As Ozawa *et al.* reported, LVNC diagnosed in the fetal period shows poor prognosis; 25% of them died or underwent heart transplantation.^[8] Some patients with HCN4 mutation showed cardiac arrest as an initial event.^[6] For this reason, periodic follow-up of echocardiography or Holter ECG is essential for patients with HCN4 mutation.

In conclusion, we present a case of fetal bradycardia associated with LVNC localized in the left ventricular apex, in which HCN4 mutation was diagnosed after birth. Fetuses with a heart rate less than the 3rd percentile of the gestational age should be followed and screened for congenital heart disease and cardiomyopathy. In addition, inherited arrhythmia syndrome should be considered even if the family history is negative.

Declaration of patient consent

The authors certify that they have obtained all appropriate patient consent forms. In the form, the patient has given her consent for her images and other clinical information to be reported in the journal. The patient understands that her name and initials will not be published and due efforts will be made to conceal identity, but anonymity cannot be guaranteed.

Acknowledgment

The authors thank Dr. Daisuke Nakato, Toshiki Takenouchi and Kenjiro Kosaki for genetic analysis.

Financial support and sponsorship

Nil.

Conflicts of interest

There are no conflicts of interest.

REFERENCES

1. Cotton JL. Identification of fetal atrial flutter by Doppler tissue imaging. *Circulation* 2001;104:1206-7.
2. Wacker-Gusmann A, Oberhoffer-Fritz R, Westphal DS, Hessling G, Wakai RT, Strasburger JF. The missense variant p.(Gly482Arg) in HCN4 is responsible for fetal tachy-bradycardia syndrome. *HeartRhythm Case Rep* 2020;6:352-6.
3. Chaudhry-Waterman N, Dara B, Bucholz E, Londono Obregon C, Grenier M, Snyder K, *et al.* Fetal heart rate <3rd percentile for gestational age can be a marker of inherited arrhythmia syndromes. *J Clin Med* 2023;12:4464.
4. Paszkowska A, Piekutowska-Abramczuk D, Ciara E, Mirecka-Rola A, Brzezinska M, Wicher D, *et al.* Clinical presentation of left ventricular noncompaction cardiomyopathy and bradycardia in three families carrying HCN4 pathogenic variants. *Genes (Basel)* 2022;13:477.
5. Brunet-Garcia L, Odori A, Fell H, Field E, Roberts AM, Starling L, *et al.* Noncompaction cardiomyopathy, sick sinus disease, and aortic dilatation: Too much for a single diagnosis? *JACC Case Rep* 2022;4:287-93.
6. Ishikawa T, Ohno S, Murakami T, Yoshida K, Mishima H, Fukuoka T, *et al.* Sick sinus syndrome with HCN4 mutations shows early onset and frequent association with atrial fibrillation and left ventricular noncompaction. *Heart Rhythm* 2017;14:717-24.
7. Kayvanpour E, Sedaghat-Hamedani F, Gi WT, Tugrul OF, Amr A, Haas J, *et al.* Clinical and genetic insights into non-compaction: A meta-analysis and systematic review on 7598 individuals. *Clin Res Cardiol* 2019;108:1297-308.
8. Ozawa SW, Takarada S, Okabe M, Miyao N, Nakaoka H, Ibuki K, *et al.* Clinical Characteristics and prognosis of fetal left ventricular noncompaction in Japan. *Circ J* 2021;86:98-105.