

# The Lesser Palatine Nerve Innervates the Levator Veli Palatini Muscle

Hideaki Kishimoto, MD\*  
Yoshitaka Matsuura, MD\*  
Katsuya Kawai, MD, PhD\*  
Shigehito Yamada†  
Shigehiko Suzuki, MD, PhD\*

**Summary:** When the lesser palatine nerve (LPN) is supposed to be a branch of the trigeminal nerve and innervate sensation of the soft palate, whether the LPN contains motor fibers is unclear. In this study, we monitored the electromyogram of the levator veli palatini (LVP) muscle on stimulating the LPN during palatoplasty in 3 patients. The electromyogram of the muscles showed the myogenic potential induced by electrostimulation of the LPN. Taken together with the finding from our previous anatomical study that the motor fibers come from the facial nerve, this result supports the double innervation theory of the LVP, which posits that both the pharyngeal plexus and the facial nerve innervate it. Identifying and preserving the LPN during palatoplasty might improve postoperative speech results. (*Plast Reconstr Surg Glob Open* 2016;4:e1044; doi: 10.1097/GOX.0000000000001044; Published online 29 September 2016.)

The levator veli palatini (LVP) muscle is responsible for the elevation of the soft palate and is critically involved in speech and deglutition. Therefore, repair of the muscle during palatoplasty for cleft palate is essential. However, the innervation of the LVP remains controversial.<sup>1-7</sup> The conventional view is the innervation via the pharyngeal plexus, whereas the conflicting view is the double innervation via the pharyngeal plexus and the facial nerve.

Our previous study<sup>1</sup> using nondestructive three-dimensional (3D) imaging and serial histological sections of embryos and early fetuses suggests that the motor nerve components from the facial nerve enter the lesser palatine nerve (LPN), which most researchers believe to be a purely sensory nerve. The results support the double innervation theory.<sup>1-3</sup>

Some patients with cleft palate exhibit velopharyngeal dysfunction during speech after palatoplasty although they acquire a good velopharyngeal function during deglutition. No previous reports have focused on the cause of such dysfunction. It is hypothesized that double innervation of the LVP might cause differing degrees of function between speech and deglutition. During deglutition,

the pharyngeal plexus is involved in the function, but during speech, the facial nerve is also partially involved.

The studies reporting double innervation of the LVP muscle are all animal studies or cadaveric studies.<sup>1-3</sup> In this study, the authors directly monitored the electromyogram of the LVP on stimulating the LPN during palatoplasty to clarify whether the LPN innervates the LVP.

## PATIENTS AND METHODS

### Patients

Three patients undergoing palatoplasty via the push-back method were targeted for the study (Table 1). All the patients were male and had unilateral cleft lip, alveolus, and palate. They were 10–12 months of age at the surgical operation. They had no other complication.

### Materials and Methods

First, the LPN was exposed during the operation. Because the lesser palatine foramen is often on the rear plane of the palatal bone (Fig. 1), we were in danger of cutting the LPN. Using a surgical loupe, we carefully separated the palatal muscles attaching abnormally to the rear plane of the palatal bone. This is a common technique in the push-back operation. Using an NIM-Neuro 3.0 system (Medtronic Japan Co., Ltd., Tokyo, Japan) for nerve stimulation, we stimulated the LPN and recorded the electromyogram of the LVP (Fig. 2). Because the stimulating and monitoring points were very close, to avoid a false-positive result, we monitored the electromyogram at an additional point as a control, located almost the same distance as the monitoring point from the stimulating point. The study was approved

From the \*Department of Plastic and Reconstructive Surgery and †Congenital Anomaly Research Center, Kyoto University Graduate School of Medicine, Kyoto, Japan.

Received for publication July 6, 2016; accepted August 3, 2016.

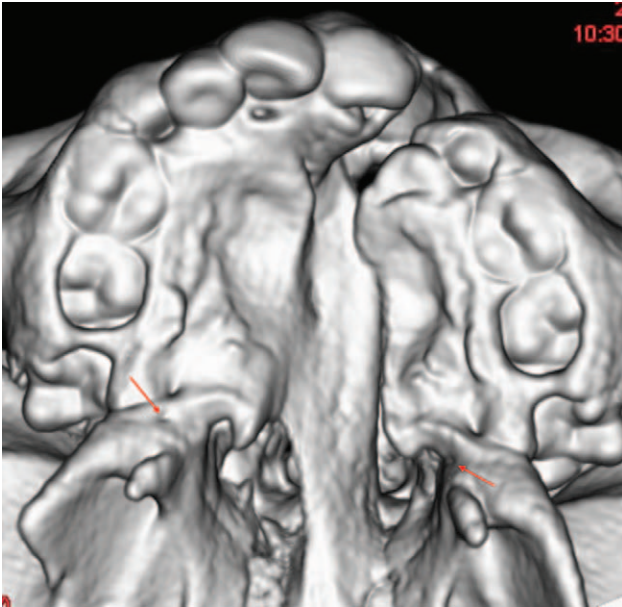
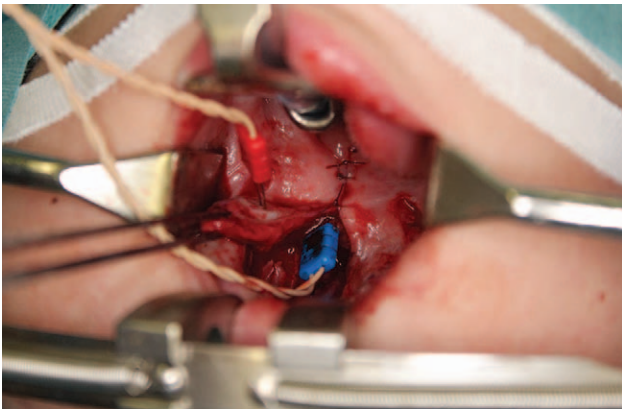
Copyright © 2016 The Authors. Published by Wolters Kluwer Health, Inc. on behalf of The American Society of Plastic Surgeons. All rights reserved. This is an open-access article distributed under the terms of the Creative Commons Attribution-Non Commercial-No Derivatives License 4.0 (CCBY-NC-ND), where it is permissible to download and share the work provided it is properly cited. The work cannot be changed in any way or used commercially.

DOI: 10.1097/GOX.0000000000001044

**Disclosure:** The authors have no financial interest to declare in relation to the content of this article. The Article Processing Charge was paid for by the authors.

**Table 1. Characteristics of the 3 Cases**

|   | Cleft Type                                      | Age at Operation (mo) | Nerve Stimulation          | Gender |
|---|---|-----------------------|----------------------------|--------|
| 1 | Left cleft incomplete lip, alveolus, and palate | 12                    | Left lesser palatine nerve | Male   |
| 2 | Right cleft complete lip, alveolus, and palate  | 11                    | Left lesser palatine nerve | Male   |
| 3 | Right cleft complete lip, alveolus, and palate  | 10                    | Left lesser palatine nerve | Male   |

**Fig. 1.** A 12-mo-old patient's 3D computed tomographic scan of the palatal bone. The arrows indicate the lesser palatine foramen.**Fig. 2.** Monitoring at 2 points. The blue electrode is in the palatal muscles, including the levator veli palatini muscle and the uvular muscle. The red electrode is in the palatal mucosa.

by the Ethics Committee at the Kyoto University Graduate School and Faculty of Medicine, Kyoto, Japan (C1906).

## RESULTS

Although the soft palate did not move after stimulating the LPN, the electromyogram of the palatal muscles showed a myogenic potential in all three cases (Fig. 3). This finding supported the hypothesis that the LPN includes a motor nerve and innervates the LVP.

## DISCUSSION

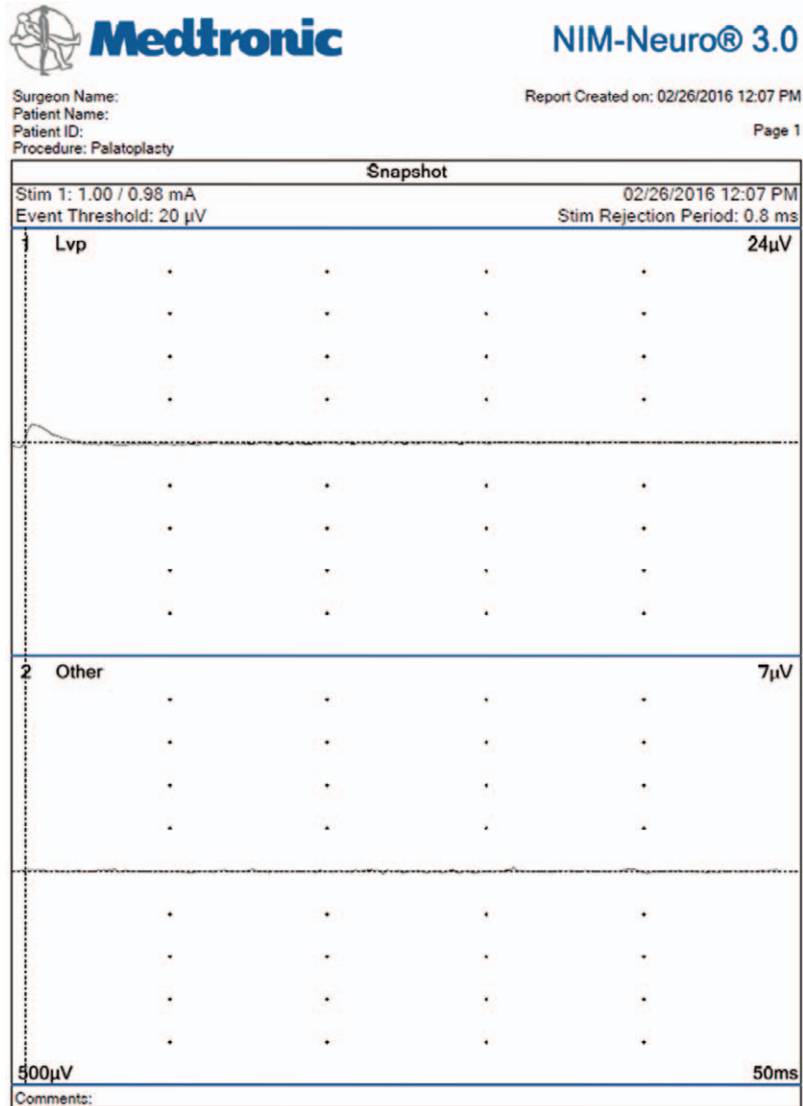
The LPN is known to be a branch of the trigeminal nerve, innervating the sensation of the soft palate. The LPN innervates the soft palatal glands by an autonomic nerve through the pathway from the facial nerve—or the intermediate nerve—via the greater petrosal nerve and the pterygopalatine ganglion.<sup>8</sup> However, the existence of a motor nerve in the LPN has not been proven in humans, although Boorman<sup>9</sup> observed uvular twitching on stimulating the LPN in a human subject. The result of this study confirmed the presence of a motor nerve in the LPN and that the nerve innervates the LVP.

The LPN connects to the facial nerve through the previously described pathway, and the facial nerve innervates the muscles relating the movement of the mouth. A previous report<sup>10</sup> found that the greater petrosal nerve branched from the geniculate ganglion of the facial nerve and innervated the LVP, although those findings were from an animal study. Some studies<sup>1,3</sup> using human embryos and fetuses have suggested that the LPN or the facial nerve innervates the LVP. The double innervation of the LVP has been described in some of the papers mentioned above, but the concept has not been widely accepted because these were animal or cadaver studies.

Clinically, some patients with facial palsy have soft palate palsy on the same side, and some patients with first and second branchial syndrome also have soft palate palsy.<sup>11,12</sup> Because soft palate palsy is almost the same as LVP palsy, these facts support the existence of double innervation.

However, most reports denying that the facial nerve innervates the muscle are also animal studies using horseradish peroxidase labeling of the neural circuit.<sup>13,14</sup> Therefore, the evidence level is low for both viewpoints. Shimokawa et al<sup>15</sup> stated that the participation of the LPN in the LVP innervation is too low when compared to the pharyngeal plexus for the HRP to be taken to the nucleus of the facial nerve. We believe that the low participation of the facial nerve in the innervation of LVP may be due to the fact that animals do not speak, unlike humans.

The significance of the LPN innervating the LVP is yet to be clarified. Given that the proportion of participation of the LPN in innervation of LVP is low, the soft palate did not move in this study. Boorman's<sup>9</sup> finding that LPN blocking for noncleft patients does not lead to the velopharyngeal insufficiency might also be attributed to the low participation of the LPN. However, despite the purportedly low participation of the LPN in innervating the LVP, the present result confirms that a motor nerve is present in the LPN. If we carefully separate the palatal muscles attaching abnormally to the rear plane end of the palatal bone to identify the LPN and preserve it, the rate of postoperative occurrence of velopharyngeal dysfunction during speech



**Fig. 3.** Report of the nerve stimulation by NIM. Stimulation of 0.98 mA showed an electromyogram of 24  $\mu$ V in the LVP. The point at the palatal mucosa showed an electromyogram of 7  $\mu$ V, which was less than the threshold (20  $\mu$ V). Stimulation at 1.48 mA showed an electromyogram of 41  $\mu$ V in the LVP, although the other point was unchanged.

might be reduced. To clarify the true significance of preservation of the LPN, we are continuing careful surgical methods with preservation of the LPN and following up the patients to examine the long-term outcomes of speech.

**Hideaki Kishimoto, MD**  
 54 Shogoin Kawabatacho  
 Sakyou-Ku, Kyoto, 606-8507  
 Japan  
 E-mail: gushi@kuhp.kyoto-u.ac.jp

#### REFERENCES

1. Kishimoto H, Yamada S, Suzuki S, et al. Three-dimensional observation of palatal muscles in human embryo and fetus: development of levator veli palatini muscle and clinical importance of the lesser palatine nerve. *Dev Dyn.* 2016;245:123–131.
2. Nishio J, Matsuya T, Ibuki K, et al. Roles of the facial, glossopharyngeal and vagus nerves in velopharyngeal movement. *Cleft Palate J.* 1976;13:201–214.
3. Iwase M, Kitamura H. Palatal muscles in human fetuses. *Kaibogaku Zasshi.* 1985;60:711–727.
4. Futamura R. Uber die Entwicklung der Facialismuskulatur des Menschen. *Anatomische Hefte.* 1906;30:433–516.
5. Gasser RF. The development of the facial nerve in man. *Ann Otol Rhinol Laryngol.* 1967;76:37–56.
6. Broomhead IW. The nerve supply of the muscles of the soft palate. *Br J Plast Surg.* 1951;4:1–15.
7. Domenech-Ratto G. Development and peripheral innervation of the palatal muscles. *Acta Anat.* 1977;97:4–14.
8. Walker HK. Clinical methods: the history, physical, and laboratory examinations. In: Walker HK, Hall WD, Jurst JW, eds. *Cranial Nerve VII: The Facial Nerve and Taste.* 3rd ed. Boston: Butterworths; 1990: Chapter 62.

9. Boorman JG. Musculus uvulae and levator palati: their anatomical and functional relationship in velopharyngeal closure. *Br J Plast Surg.* 1985;38:333–338.
10. Ibuki K, Matsuya T, Nishio J, et al. The course of facial nerve innervation for the levator veli palatini muscle. *Cleft Palate J.* 1978;15:209–214.
11. Toyoda K. Sixteen cases of soft palate paralysis. *Practica Oto-Rhino-Laryngologica* 1986;79:421–426.
12. Dellon AL. The levator veli palatini muscle arises from the second branchial arch: a hypothesis. *Ann Plast Surg.* 1989;23:317–319.
13. van Loveren H. Localization of motoneurons innervating the levator veli palatini muscle in the cat. *Brain Res Bull.* 1983;11:303–307.
14. Keller JT, Saunders MC, van Loveren H, et al. Neuroanatomical considerations of palatal muscles: tensor and levator veli palatini. *Cleft Palate J.* 1984;21:70–75.
15. Shimokawa T, Yi S, Tanaka S. Nerve supply to the soft palate muscles with special reference to the distribution of the lesser palatine nerve. *Cleft Palate Craniofac J.* 2005;42:495–500.