

Two novel mutations in *RNU4ATAC* in two siblings with an atypical mild phenotype of microcephalic osteodysplastic primordial dwarfism type 1

Anne B. Krøigård^a, Andrew P. Jackson^c, Louise S. Bicknell^e, Emma Baple^d, Klaus Brusgaard^a, Lars K. Hansen^b and Lilian B. Ousager^a

Clinical Dysmorphology 2016, 25:68–72

^aDepartment of Clinical Genetics, ^bH.C. Andersen Children's Hospital, Odense University Hospital, Odense, Denmark, ^cMRC Human Genetics Unit, Institute of Genetics and Molecular Medicine, University of Edinburgh, Edinburgh, ^dUniversity of Southampton, Southampton, UK and ^eDepartment of Pathology, Dunedin School of Medicine, University of Otago, Dunedin, New Zealand

Correspondence to Anne B. Krøigård, MD, PhD, Department of Clinical Genetics, Odense University Hospital, Sdr. Boulevard 29, DK-5000 Odense C, Denmark
Tel: +45 654 119 73; fax: +45 654 148 75; e-mail: anne.kroegaard@rsyd.dk

Received 2 October 2015 Accepted 17 November 2015

List of key features

- Dwarfism
- Foetal growth retardation
- Microcephaly
- Mutation
- Nucleotides
- Osteochondrodysplasias
- RNA, small nuclear
- Spliceosomes
- Syndrome
- Microcephalic osteodysplastic primordial dwarfism, type 1

Introduction

Taybi–Linder syndrome or microcephalic osteodysplastic primordial dwarfism type 1 (MOPD1) (MIM # 210710) is a rare autosomal recessive developmental disorder, originally described in 1967 (Taybi and Linder, 1967). The patients present with severe intrauterine and postnatal growth retardation, microcephaly, facial dysmorphism, sparse thin hair and dry skin (Meinecke and Passarge, 1991). Radiological findings include dysplasia of the skeleton with cleft vertebral arches, horizontal acetabula and short and bowed long bones (Sigaudy *et al.*, 1998). Neurological findings typically include profound developmental delay, blindness, hearing deficits, central nervous system malformations, early-onset epilepsy and neuroendocrine dysfunction (Pierce and Morse, 2012).

MOPD1 has been shown to result from biallelic mutations in the *RNU4ATAC* gene encoding the small nuclear RNA (snRNA) U4atac, which is a component of the minor spliceosome. Although accounting for splicing of only about 800 introns, the minor spliceosome is involved in the correct splicing of many essential gene products.

Thus, minor intron splicing has a critical role in human development (He *et al.*, 2011).

At present, only around 40 patients with MOPD1 and 10 different *RNU4ATAC* mutations have been reported according to the Human Gene Mutation Database. The condition is usually severe, and the patients do not generally live beyond the age of 3 years (Meinecke and Passarge, 1991). A few cases with a slightly milder phenotype have been reported (Abdel-Salam *et al.*, 2012; Nagy *et al.*, 2012), but no patients have yet been reported to survive into adulthood.

We report on two adult siblings with MOPD1 presenting with an atypical mild phenotypic appearance compared with the previously reported cases.

Clinical reports

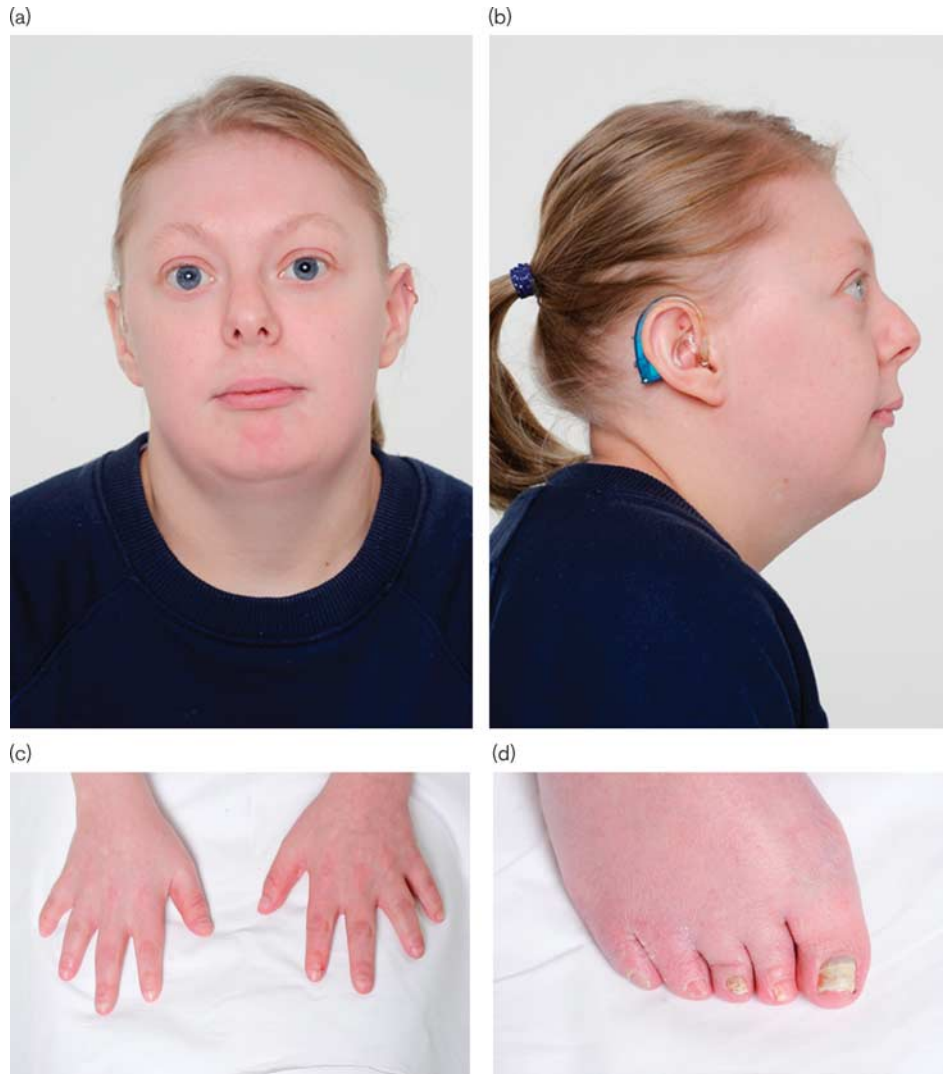The two siblings are the second and third children of healthy nonconsanguineous white parents and have an unremarkable family history. They both presented with prenatal and postnatal growth retardation, microcephaly, developmental delay, cataract, hearing loss and dysmorphic features. Before the establishment of the diagnosis, the cases were reported as unsolved cases (Hansen *et al.*, 2009).

Case 1

A girl, now age 24 years, was born at 38 weeks of gestational age with a birth weight of 1950 g (−3 SD), a length of 43 cm (−4 SD) and a head circumference of 29 cm (−5 SD). She had neonatal hypoglycaemia, which resolved after treatment. In childhood, her skin was affected by severe atopic dermatitis and she had allergies towards egg, milk, nuts and grass. She had several pulmonary infections in early childhood and asthma until 10 years of age. The dysmorphic features included receding forehead, large prominent eyes, arched eyebrows, hypoplasia of the ala nasi, micrognathia, thin hair, small low-set ears and short neck (Fig. 1a and b). Dental examination revealed malocclusion, crowded teeth and

This is an open-access article distributed under the terms of the Creative Commons Attribution-Non Commercial-No Derivatives License 4.0 (CCBY-NC-ND), where it is permissible to download and share the work provided it is properly cited. The work cannot be changed in any way or used commercially.

Fig. 1



Case 1, age 24 years. (a, b) Dysmorphic features included receding forehead, prominent eyes, arched eyebrows, hypoplasia of the ala nasi, micrognathia, thin hair, small low-set ears and short neck. (c, d) Tapering fingers. Fingers and toes were broad and short, the skin was dry and nails were dystrophic.

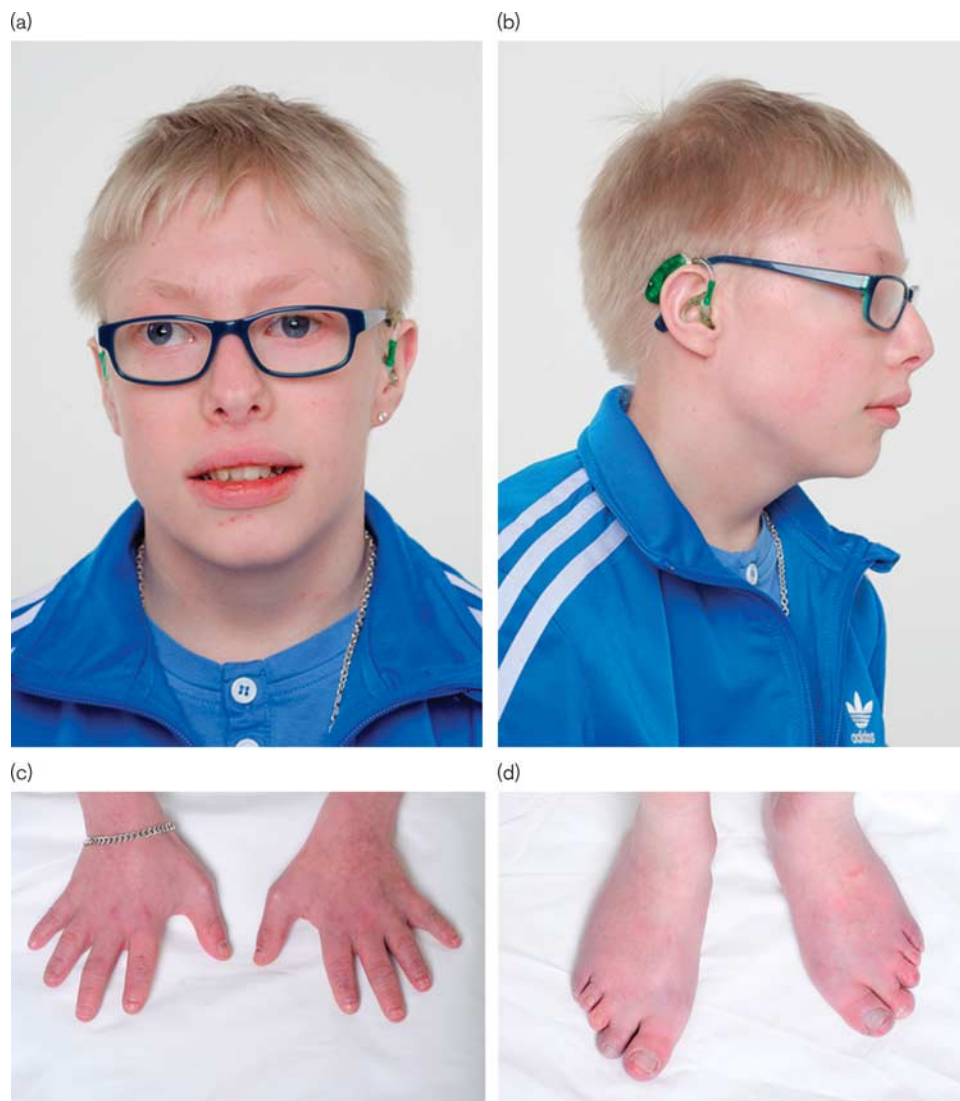microdontia with enamel abnormalities. She had tapering fingers and her fingers and toes were broad and short, the skin was dry and the nails were dystrophic (Fig. 1c and d). Radiographs of the long bones, at the age of 1 and 8 years, displayed generalized shortening with metaphyseal broadening and delayed bone age. Ophthalmological examination revealed bilateral cataracts, which were operated at the age of 5 years, and tapeto-retinal degeneration. She had menarche at 16 years of age and had normal periods. From the age of 14 years, she had progressive sensorineural hearing loss of 60 dB, partially corrected by hearing aids. At the age of 23 years, she developed severe pneumonia complicated by haemolytic uraemic syndrome and required respiratory support and dialysis for 1 week. Cranial MRI at the age of 24 years

demonstrated microcephaly, partial agenesis of corpus callosum and general atrophy. She did not develop epilepsy. At the most recent evaluation, at the age of 24 years, she was severely growth retarded with a height of 142 cm (-5 SD), weight of 35 kg (-6 SD) and a head circumference of 45 cm (-10 SD). Intellectual disability was evident with an IQ of 56, but she was able to live in her own apartment with some support. She had reading skills comparable with a 9-year-old and very limited mathematics skills. She had a slight kyphosis, but no specific orthopaedic problems and was able to walk 5 km.

Case 2

A boy, now aged 17 years, presented like his sister with severe prenatal growth retardation and was delivered at

Fig. 2




Case 2, age 17 years. (a, b) Dysmorphic features included receding forehead, bulbous nose, hypoplasia of the ala nasi, full lips, small ears and mild micrognathia. (c, d) Tapering fingers, which were broad and short. The feet were flat with dry skin and short toes with syndactyly of second and third toes.

32 weeks of gestation by Caesarean section with a birth weight of 1079 g (-4 SD) and length of 38 cm (-4 SD). He had atopic dermatitis and allergies in childhood. He was operated on for cryptorchidism. He developed bilateral cataract and received artificial lenses at the age of 4 years, and ophthalmological examination has also revealed tapetoretinal degeneration. He had asthma until 10 years of age. From the age of 10 years, he developed progressive sensorineural hearing loss relieved by hearing aids. The dysmorphic features included receding forehead, bulbous nose, hypoplasia of the ala nasi, full lips, small ears and mild micrognathia (Fig. 2a and b). Dental examination revealed malocclusion and small, crowded

teeth with enamel abnormalities. He had tapering fingers, which were broad and short. He had flat feet, syndactyly of second and third toes and dry skin (Fig. 2c and d). Skeletal radiological examination at the age of 12 years (Fig. 3a and b) showed shortening of the long bones, metaphyseal broadening, but otherwise relatively normal configuration. He reached puberty at the age of 15 years. He did not develop epilepsy. At the most recent evaluation, at the age of 17 years, he was severely growth retarded with a height of 139 cm (-7 SD), weight of 30 kg (-6.5 SD) and a head circumference of 46.9 cm (-8 SD). He lived in his parents' home, attended special school and had reading capability corresponding to

Fig. 3



Radiographs of (a) humerus and (b) femur of case 2 at the age of 12 years showing shortening of the long bones, metaphyseal broadening, but otherwise relatively normal configuration.

8 years of age, and no mathematics skills. He had good motor skills, could ride a bicycle, walk 5–10 km and run 3 km without breaks.

Mutation analysis

The study was approved by the Scottish Multicentre Research Ethics Committee (04:MRE00/19). Genomic DNA samples from the patients, parents and unaffected sister were analysed at the Institute of Genetics and Molecular Medicine, University of Edinburgh, UK. The *RNU4ATAC* gene was screened by bidirectional Sanger sequencing, and analyses were performed using Mutation Surveyor (Softgenetics Inc., Pennsylvania, USA). The findings were validated by bidirectional Sanger sequencing at the Department of Clinical Genetics, Odense University Hospital, using SeqMan Pro v.12.0, DNA Star (Wisconsin, USA).

The affected siblings were compound heterozygous for a n.40C>T nucleotide substitution and an 85-base tandem duplication (bp 16–100) in *RNU4ATAC*, which results in an insertion of an 85-base-pair-long sequence in position n.101.

The parents were both heterozygous for each one of these mutations, and the oldest sister, who was unaffected, was heterozygous for the n.40C>T mutation.

Neither of these mutations have been previously reported in the literature in relation to MOPD1. The n.40C>T was reported in a single individual from south Asia in the Exome Aggregation Consortium corresponding to a population frequency of 0.0093%. No homozygotes for the mutation have been detected.

Figure 4 displays the normal configuration of the U4atac snRNA and localization of the two mutations. The n.40C>T mutation is predicted to disrupt the essential 5' stem loop, as the n.40C is one of four bases stabilizing this loop and notably it pairs with n.46 G, a base previously reported to be mutated in MOPD1 (Kilic *et al.*,

2015). The other mutation, the 85-base-pair insertion in position n.101, is also predicted to have a major impact on conformation and to destroy the 3' stem loop, and it is therefore also predicted to have a major functional impact on the snRNA [in-silico predictions made by Protein Data Bank 3SIU (New Jersey, USA) and PhyMol v.1.7 (Schrödinger, New York, USA) software].

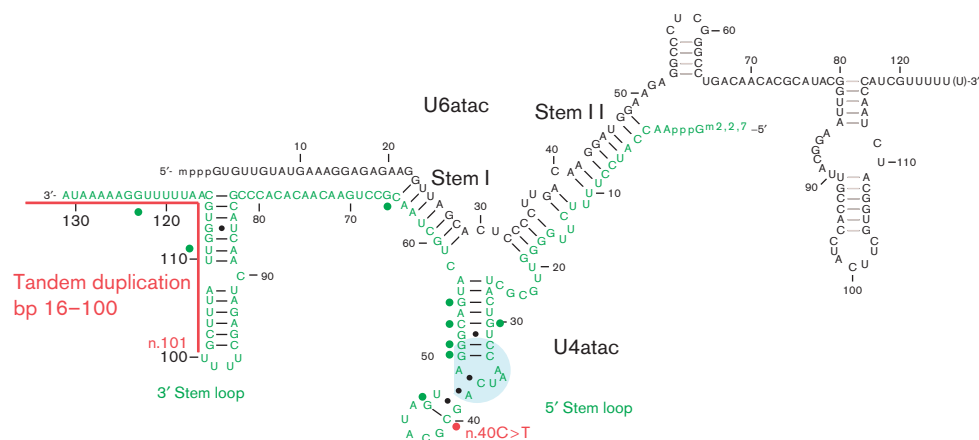
Discussion

MOPD1 is generally described as a fatal condition within the first months or years of life. However, reports of less severely affected individuals are emerging (Abdel-Salam *et al.*, 2012; Nagy *et al.*, 2012).

Most of the previously reported cases were homozygous for the n.51 G>A mutation, a founder mutation in the Amish population, representing the most frequent genotype of MOPD1 patients and one associated with a shorter life span compared with other cases (Nagy *et al.*, 2012). A patient described with a milder phenotype is compound heterozygous for n.66C>G and n.124 G>A mutations (Abdel-Salam *et al.*, 2012). Thus, the fact that our cases present with a mild phenotype may be because of the compound heterozygous state or that one of the mutations lies outside the essential 5' stem loop.

Seven of the previously reported mutations in patients with MOPD1 including n.30 G>A, n.46 G>A, n.50 G>A, n.50 G>C, n.51 G>A, n.53C>G and n. 55 G>A mutations are located within the 5' stem loop of the U4atac snRNA, a motif interacting with spliceosomal proteins. This secondary structure of the snRNA is highly conserved across species, suggesting that the site is of critical importance for minor U12 spliceosomal function (Edery *et al.*, 2011). The 3' stem loop is also believed to have an essential role, and complete deletion of the 3' stem loop is reported to abolish the in-vivo splicing function of the minor spliceosome (Shukla *et al.*, 2002).

Fig. 4



Schematic of the normal structure of the U4atac snRNA in complex with the other essential component of the minor spliceosome, U6atac. The reported cases are compound heterozygous for two mutations in *RNU4ATAC* encoding U4atac (marked in red). The n.40C > T is predicted to destroy the essential 5' stem loop as the n.40C is one of four bases stabilizing this essential loop. The n.101 tandem duplication (bp 16–100) is predicted by in-silico prediction tools to induce a major conformational change and to destroy the 3' stem loop. The positions of previously reported mutations in patients with MOPD1 (marked by green dots) are also primarily situated in either the 5' stem loop or the 3' stem loop.

The two mutations reported by us are both predicted by in-silico prediction tools to severely affect the secondary structure of the snRNA.

Our presented cases display some classical features of MOPD1, including prenatal and postnatal growth retardation, microcephaly, developmental delay, cataract, hearing loss and dysmorphic features, but unlike previously reported cases have survived into adult life.

Although no clear genotype–phenotype correlation exists on the limited number of milder cases reported previously and in our study, our findings at least indicate that the compound heterozygous genotype n.40C > T/n.101 tandem duplication (bp 16–100) in *RNU4ATAC* results in a mild phenotypic appearance of MOPD1 compatible with survival into adulthood. The presented cases further expand the mutational and phenotypic spectrum of the MOPD1 syndrome.

Acknowledgements

The authors thank the family for participating in the study.

Conflicts of interest

There are no conflicts of interest.

References

- Abdel-Salam GMH, Abdel-Hamid MS, Issa M, Magdy A, El-Kotoury A, Amr K (2012). Expanding the phenotypic and mutational spectrum in microcephalic osteodysplastic primordial dwarfism type I. *Am J Med Genet A* **158A**:1455–1461.
- Ederly P, Marcaillou C, Sahbatou M, Labalme A, Chastang J, Touraine R, et al. (2011). Association of TALS developmental disorder with defect in minor splicing component U4atac snRNA. *Science* **332**:240–243.
- Hansen LK, Bygum A, Ousager LB (2009). Two siblings with microcephaly, growth retardation, cataract, hearing loss, and unusual appearance. *Clin Dysmorphol* **18**:181–183.
- He H, Liyanarachchi S, Akagi K, Nagy R, Li J, Dietrich RC, et al. (2011). Mutations in U4atac snRNA, a component of the minor spliceosome, in the developmental disorder MOPD I. *Science* **332**:238–240.
- Kilic E, Yigit G, Utine GE, Wollnik B, Mihci E, Nur BG, Boduroglu K (2015). A novel mutation in *RNU4ATAC* in a patient with microcephalic osteodysplastic primordial dwarfism type I. *Am J Med Genet A* **167A**:919–921.
- Meinecke P, Passarge E (1991). Microcephalic osteodysplastic primordial dwarfism type I/III in sibs. *J Med Genet* **28**:795–800.
- Nagy R, Wang H, Albrecht B, Wieczorek D, Gillesen-Kaesbach G, Haan E, et al. (2012). Microcephalic osteodysplastic primordial dwarfism type I with biallelic mutations in the *RNU4ATAC* gene. *Clin Genet* **82**:140–146.
- Pierce MJ, Morse RP (2012). The neurologic findings in Taybi–Linder syndrome (MOPD I/III): case report and review of the literature. *Am J Med Genet A* **158A**:606–610.
- Shukla G, Cole AJ, Dietrich RC, Padgett RA (2002). Domains of human U4atac snRNA required for U12-dependent splicing in vivo. *Nucleic Acids Res* **30**:4650–4657.
- Sigaudy S, Toutain A, Moncla A, Fredouille C, Bourlière B, Ayme S, Philip N (1998). Microcephalic osteodysplastic primordial dwarfism Taybi–Linder type: report of four cases and review of the literature. *Am J Med Genet* **80**:16–24.
- Taybi H, Linder D (1967). *Radiology* **89**:275–281.