

## Paraneoplastic Encephalitis Associated with Thymoma: A Case Report

Jee Won Suh, M.D., Seok Jin Haam, M.D., Suk Won Song, M.D., Yu Rim Shin, M.D.,  
Hyo Chae Paik, M.D., Doo Yun Lee, M.D.

A 42-year-old woman with short-term memory loss visited Gangnam Severance Hospital, and her chest X-ray and computed tomography revealed a right anterior mediastinal mass. On hospital day two, she suddenly presented personality changes and a drowsy mental status, so she required ventilator care in the intensive care unit. She underwent thymectomy, and was pathologically diagnosed with thymoma, type B1. Her mental status eventually recovered by postoperative day 90. Paraneoplastic encephalopathy associated with thymoma is very rare, and symptoms can be improved by thymectomy. We report a case of paraneoplastic encephalopathy associated with a thymoma.

Key words: 1. Paraneoplastic syndromes  
2. Thymoma  
3. Thymectomy

### CASE REPORT

A 42-year-old woman presented with a history of 15 days of short-term memory loss. She complained of generalized weakness and voice changes over the previous 3 months. On physical examination, she had mild bilateral ptosis. Chest X-ray revealed a right hilar mass and chest computed tomography showed a 5 cm anterior mediastinal mass consistent with a thymoma (Fig. 1).

On hospital day 2, she suddenly exhibited personality changes and severe agitation, which evolved into a drowsy mental status. Arterial blood gas analysis demonstrated hypoxemia (PaO<sub>2</sub>, 68.4 mmHg), hypercapnea (58.3 mmHg), and respiratory acidosis (pH, 7.187), prompting orotracheal intubation and ventilator care. Brain magnetic resonance imag-

ing (MRI) showed multifocal high intensity signals in the cerebral cortex including the limbic area on T2 flare images (Fig. 2A). Diffuse delta background activity and moderate diffuse cerebral dysfunction were observed on electroencephalography (EEG). In serologic tests, serum acetylcholine receptor (AChR) antibody titer (11.189 nmol/L) was elevated, but antineuronal nuclear antibody (Hu/Ri) and Purkinje cell antibody (Yo) were negative. Considering these findings, we thought that she had myasthenia gravis and paraneoplastic encephalitis associated with a thymoma.

Thymectomy was recommended, but due to the patient's drowsy mental status, it was difficult to obtain consent for the surgery from her guardians. Ultimately, on hospital day 8, she underwent a thymectomy, the pathology of which revealed a thymoma, type B1. The thymoma had invaded the

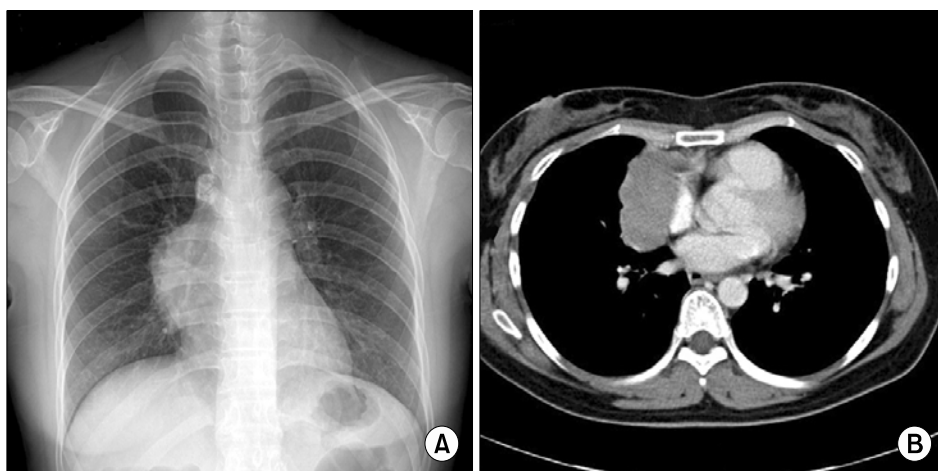
Department of Thoracic and Cardiovascular Surgery, Gangnam Severance Hospital, Yonsei University College of Medicine

Received: October 12, 2012, Revised: December 12, 2012, Accepted: December 18, 2012

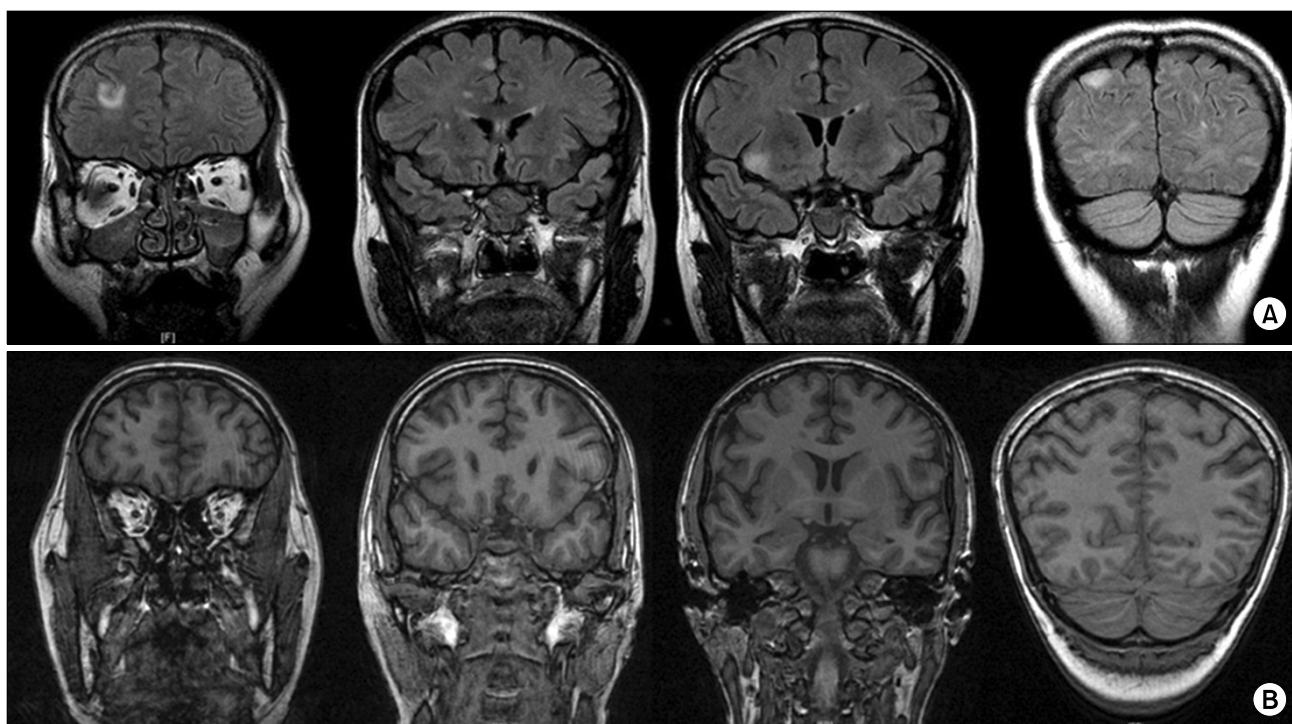
Corresponding author: Seok Jin Haam, Department of Thoracic and Cardiovascular Surgery, Gangnam Severance Hospital, Yonsei University College of Medicine, 211 Eonju-ro, Gangnam-gu, Seoul 135-720, Korea  
(Tel) 82-2-2019-3380 (Fax) 82-2-3461-8282 (E-mail) hamsj@yuhs.ac

© The Korean Society for Thoracic and Cardiovascular Surgery. 2013. All right reserved.

© This is an open access article distributed under the terms of the Creative Commons Attribution Non-Commercial License (<http://creativecommons.org/licenses/by-nc/3.0>) which permits unrestricted non-commercial use, distribution, and reproduction in any medium, provided the original work is properly cited.



**Fig. 1.** (A) Preoperative chest X-ray revealed a mediastinal mass in the right hilum. (B) Preoperative chest computed tomography showed a 5 cm anterior mediastinal mass considered to be a thymoma.



**Fig. 2.** (A) Preoperative brain magnetic resonance imaging (MRI) showing multifocal high intensity signals in the cerebrum on T2 flare images. (B) Follow-up brain MRI, on postoperative day 96, showed that the lesions had disappeared.

pericardium and pericardial fat tissues with metastasis to the right diaphragm. Despite the thymectomy, the patient's mental status and odd behavior still did not improve. On postoperative day 10, follow-up brain MRI was performed, but the previous high intensity lesion still remained. Thereafter, her mental status and abnormal behavior gradually improved. On postoperative day 90, her cognitive status had nearly fully

recovered and brain MRI on postoperative day 96 showed that the previous lesions had disappeared (Fig. 2B). On postoperative day 106, the patient was discharged without complications. Because the thymoma pathologically invaded adjacent tissues, we recommended additional radiotherapy. However, she refused further treatment. At 2 years after thymectomy, she has had no specific symptoms, but the AchR

antibody titer is still high (13.483 nmol/L). She takes only 180 mg per day of pyridostigmine from our outpatient clinic.

## DISCUSSION

Paraneoplastic neurologic syndromes (PNS) are very rare diseases that are mainly associated with small cell lung cancer, testicular cancer, bladder cancer, and breast cancer [1]. PNS is caused by damage to the nervous system due to immune-mediated mechanisms; the primary tumor is typically not found in the nervous system. To meet the criteria for PNS, direct tumor invasion to the nervous system, metastasis, and infection must be excluded [2].

Thymoma is the most common type of tumor in the anterior mediastinum. Its association with myasthenia gravis is well established, but the associations with other types of PNS are unknown. Only about thirty cases of PNS associated with thymoma invading the limbic area and 5 cases of extralimbic encephalopathy have been reported [3]. What is unusual in our case is that both the limbic and extralimbic areas were involved. The main symptoms, such as short term memory and personality changes, were thought to be associated with invasion into the limbic area.

Symptoms of paraneoplastic encephalitis are not specific, but short-term memory loss, personality changes, agitation, and seizure may occur [4]. Diagnosis is difficult to confirm, but high intensity lesions are found in T2 flare images on brain MRI. EEG is generally abnormal, and slow-wave abnormalities with epileptiform activity are found [5]. Brain biopsy can confirm the pathological diagnosis, but is not always necessary [3].

Its pathogenesis remains uncertain, but it is thought that paraneoplastic encephalopathy is caused by immune responses to neuronal antigens of tumor cross-reacting with protein expressed in the nervous system [6]. However, not all patients with paraneoplastic encephalopathy have antineuronal antibodies. In our case, only serum AchR antibody was high while the other antibodies were negative.

The optimal treatment consists of identifying the thymoma as soon as possible and removing it surgically [7]. Additionally, intravenous immunoglobulin, plasmapheresis, or immunosuppression can be used against antineuronal

antibodies.

The progression of disease varies so widely that in one report, symptoms were completely resolved within 1 week of surgery [3], but in another report, symptoms continuously remained despite complete resection of the thymoma [2]. Due to the rarity of the disease, its pathogenesis and prognosis are not well known.

In our case, paraneoplastic encephalitis was associated with a thymoma and manifested as neurologic symptoms corresponding to the limbic system on brain MRI. Neurologic symptoms improved 3 months after resection of the thymoma.

In conclusion, when patients have neurologic symptoms related to the limbic area, it is necessary to examine the thymus to rule out potential thymoma. In addition, thymectomy should be aggressively considered for relief of symptoms associated with paraneoplastic encephalopathy with thymoma.

## CONFLICT OF INTEREST

No potential conflict of interest relevant to this article was reported.

## REFERENCES

1. Gultekin SH, Rosenfeld MR, Voltz R, Eichen J, Posner JB, Dalmau J. *Paraneoplastic limbic encephalitis: neurological symptoms, immunological findings and tumour association in 50 patients*. Brain 2000;123:1481-94.
2. Chaudhry MS, Waters M, Gilligan D. *Paraneoplastic limbic encephalitis attributable to thymoma*. J Thorac Oncol 2007;2: 879-80.
3. Rizzardi G, Campione A, Scanagatta P, Terzi A. *Paraneoplastic extra limbic encephalitis associated with thymoma*. Interact Cardiovasc Thorac Surg 2009;9:755-6.
4. Pearce JM. *Paraneoplastic limbic encephalitis*. Eur Neurol 2005;53:106-8.
5. Lawn ND, Westmoreland BF, Kiely MJ, Lennon VA, Vernino S. *Clinical, magnetic resonance imaging, and electroencephalographic findings in paraneoplastic limbic encephalitis*. Mayo Clin Proc 2003;78:1363-8.
6. Darnell RB. *Onconeural antigens and the paraneoplastic neurologic disorders: at the intersection of cancer, immunity, and the brain*. Proc Natl Acad Sci U S A 1996;93:4529-36.
7. D'Avino C, Lucchi M, Ceravolo R, et al. *Limbic encephalitis associated with thymic cancer: a case report*. J Neurol 2001;248:1000-2.