

Synchronous Bilateral Adrenalectomy for Adrenocorticotrophic-Dependent Cushing's Syndrome

Dev Malley, MS IV, Ronald Boris, MD, Sanjeev Kaul, MD, MCh (Uro), Daniel Eun, MD, Fred Muhletaler, MD, Craig Rogers, MD, Vinod Narra, MD, Mani Menon, MD

ABSTRACT

Select patients with ACTH-dependent Cushing's syndrome, such as patients with persistent Cushing's disease after failed hypophysectomy or patients with ectopic ACTH production, may require bilateral adrenalectomy. Laparoscopic bilateral adrenalectomy has been described, offering definitive treatment with reduced morbidity compared with open techniques. We report on the performance of synchronous bilateral adrenalectomy treated using the da Vinci robot (Intuitive Surgical, Sunnyvale, CA). To our knowledge, the usage of this minimally invasive approach for this operation has yet to be reported in literature. The details of the case and a brief review of the literature are described herein.

Key Words: Robotics, Adrenalectomy, da Vinci, Cushing syndrome.

INTRODUCTION

Cushing's syndrome is a disorder caused by excess cortisol and can result in clinical manifestations including obesity, hypertension, diminished glucose intolerance, sexual and menstrual dysfunction, hirsutism, acne, striae, emotional lability, and osteoporosis.¹ Most cases (80%) of endogenous Cushing's syndrome are caused by a pituitary adenoma (ie, Cushing's disease), 10% by ectopic production of ACTH, 5% by adrenal adenoma, and 5% by carcinoma.² In the United States, the annual incidence of endogenous Cushing's syndrome has been estimated at 13 cases per one million individuals.

Select patients with ACTH-dependent Cushing's syndrome, such as patients with persistent Cushing's disease after failed hypophysectomy or patients with ectopic ACTH production, may ultimately require bilateral adrenalectomy. Other rare indications for bilateral adrenalectomy include adrenocortical hyperplasia, bilateral adrenocortical adenomas, congenital adrenal hyperplasia, and bilateral pheochromocytomas in patients with multiple endocrine neoplasia type 2 or von Hippel-Lindau syndrome. Although laparoscopic surgery is the standard of care for most adrenal tumors, concurrent bilateral laparoscopic adrenalectomy is less established. To date, only 6 published series with more than 15 patients exist. We report on the first synchronous bilateral adrenalectomy utilizing a robotic approach and provide a brief review of the literature regarding the role of minimally invasive surgery for this procedure.

CASE REPORT

A 45-year-old Caucasian female with hypercortisolism underwent transsphenoidal hypophysectomy for a 4-mm by 5-mm pituitary lesion diagnosed on RI. Postoperatively, she had persistently elevated ACTH and cortisol levels. Computed tomographic (CT) scan revealed bilateral adrenal hyperplasia without evidence of an ectopic ACTH-producing tumor (**Figure 1**). A diagnosis of nonremitting ACTH-dependent hypercortisolism was made. Treatment options were considered including completion hypophysectomy, medical management, and bilateral adrenalectomy with steroid replacement. The patient elected to

Vattikuti Urology Institute, Henry Ford Health System, Detroit, Michigan, USA (all authors).

Address reprint requests to: Sanjeev Kaul, MD, MCh, 2799 West Grand Blvd, K-9, Detroit, MI 48202, USA. E-mail: skaul1@hfhs.org

© 2008 by JSL, *Journal of the Society of Laparoendoscopic Surgeons*. Published by the Society of Laparoendoscopic Surgeons, Inc.

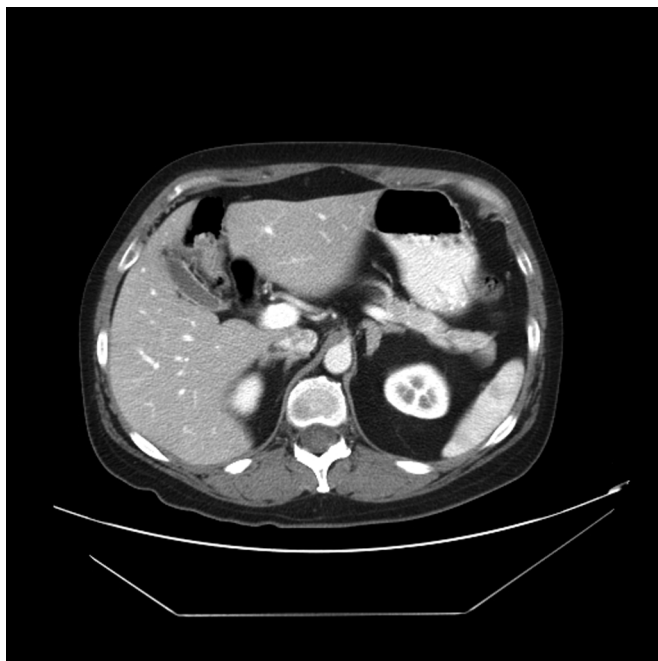

Figure 1. Computed tomographic scan of abdomen with contrast revealing bilateral adrenal hyperplasia. No masses or nodules seen.

undergo concurrent robotic-assisted bilateral adrenalectomy.

METHODS

The patient was placed in a left lateral decubitus position. Veress needle pneumoperitoneum was established. Three triangulated robotic ports were placed directed towards the right adrenal gland: a 12-mm camera port and two 8-mm robotic ports as seen in **Figure 2**. A 12-mm periumbilical port and a 5-mm subxiphoid port were placed and used for retraction, suction, and specimen retrieval by the assistant. The robot was docked, and the right adrenal gland was removed in 77 minutes following the standard laparoscopic technique. It was placed in a 10-mm ENDOCATCH bag (US Surgical Corporation, Pembroke, Bermuda), and the string was externalized through the umbilical port.

The robot was docked, and the patient was rotated into a right lateral decubitus position. A 12-mm port was reinserted through the umbilical incision, and the abdomen was insufflated to 20 mm Hg. In a similar fashion, a 12-mm port and two 8-mm robotic ports were placed in an isosceles triangle directed towards the left adrenal gland. The subxiphoid 5-mm port was replaced orthotopically. The robot was redocked. The left adrenal gland was removed

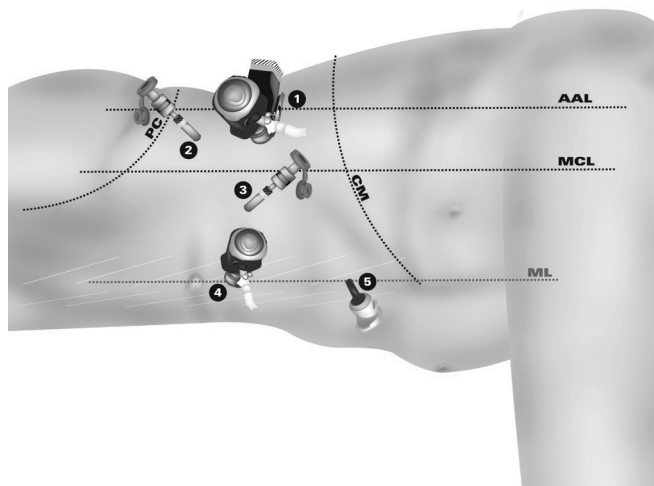


Figure 2. Diagram of port placement for right sided robotic adrenalectomy. Patient in left lateral decubitus position. Robot docked over ipsilateral shoulder. Ports 1–3 triangulated toward adrenal bed. For left side, patient rotated and ports 1–3 replaced in similar fashion towards left adrenal gland. Assistant ports 4 and 5 used for right and left adrenalectomy. AAL=anterior axillary line; MCL=midclavicular line; ML=midline.

in 55 minutes. The specimen was placed in a second 10-mm ENDOCATCH bag, and both specimens were removed through a 4-cm extended umbilical incision. The overall operative time was 235 minutes.

The patient's postoperative course was uncomplicated, and she was discharged home on postoperative day 3 on steroid replacement. Histopathologic analysis confirmed mild adrenal hyperplasia. At one-month follow-up, the patient was doing well, and prior stigmata of hypercortisolism have resolved.

DISCUSSION

Transsphenoidal surgery for resection of an ACTH-secreting pituitary tumor is the standard therapy for Cushing's disease, but it is associated with a 20% to 40% failure rate.³ Completion hypophysectomy presents an increased risk of panhypopituitarism and may be poorly tolerated. Sellar radiation therapy is not an ideal therapy for Cushing's disease because of its delayed onset of action and high remission rates.^{4,5} Long-term pharmacotherapy can carry significant side effects.⁶ Therefore, bilateral adrenalectomy may be an alternative therapy in select patients with Cushing's disease who fail initial pituitary surgery. Laparoscopic bilateral adrenalectomy has been described and can offer definitive treatment with low morbidity com-

Table 1.

Synchronous Laparoscopic Bilateral Adrenalectomy: Review of Published Reports With 15 or More Cases Compared With Our Synchronous Robotic Bilateral Adrenalectomy

Author	Diagnosis * (n)	Op Time (min)	Open Conversion	Blood Loss (mL)	Hosp Stay (d)	Postoperative Morbidity and Mortality*
Acosta et al ¹⁰	CS (17)	360	1	N/A	6	Hypoglycemia (1) Back pain (1) Death from GI bleed (1)
Bonjer et al ¹¹	CS (13) Pheo (3)	214	1	121	5	Hematoma (1) UTI (1) Death from sepsis (1)
Vella et al ¹²	CS (19)	252	3	N/A	2.7	DVT (1)
Hawn et al ¹³	CS (18)	296	None	218	3	Hemorrhage (1) Pancreatitis (1)
Jager et al ¹⁴	CS (16) Pheo (2)	289	None	125	7	Death from PE (1)
Takata et al ¹⁵	CS (25) Pheo (5)	290	None	81	3.5	UTI (2) Pneumonia (1) Addisonian crisis (1) Wd infection (1) DI (1)
Summary	CS (108) Pheo (10)	284	4.2%	136	4.5	14% morbidity 2.5% mortality
Present Case	Persistent Hypercortisolism	132 (console)	None	50	3	None

*CS = Cushing's syndrome, Pheo = pheochromocytoma, UTI = urinary tract infection, DVT = deep venous thrombosis, DI = diabetes insipidus.

pared with open techniques.^{7,8} While robotic adrenalectomy has been shown to be a safe and effective alternative to laparoscopic adrenalectomy,⁹ no published reports have been published on synchronous robotic bilateral adrenalectomy.

A review of 118 laparoscopic bilateral adrenalectomies from 6 published series is presented in **Table 1**.^{9–15} Our robotic bilateral adrenalectomy was performed in 235 minutes with 132 minutes of operative console time and a 50 mL estimated blood loss. The procedure was performed without complication or associated patient morbidity.

Our first experience with bilateral robotic adrenalectomy was performed with less blood loss, shorter hospital stay, shorter operative time, and no complications, compared with the data from published laparoscopic series (**Table 1**). These early data are encouraging, and we will continue to refine our technique and we hope improve operative and perioperative parameters.

CONCLUSION

Robotic-assisted synchronous bilateral adrenalectomy is a feasible and safe procedure. Preoperative and periopera-

tive parameters appear equivalent and potentially superior to parameters in larger published laparoscopic series. A larger experience with longer follow-up will be necessary to further assess this novel approach.

References:

1. Nieman L, Cutler GB Jr. Cushing's syndrome. In: Degroot LJ, Besser M, Burger HG et al, eds. *Endocrinology*. 3rd ed. Philadelphia, PA: WB Saunders; 1995;1741–1769.
2. Tanagho, EA, McAninch JW. *Smith's General Urology*. 16th ed. New York: Lange; 2004;492–493.
3. Tahir AH, Sheeler LR. Recurrent Cushing's disease after transsphenoidal surgery. *Arch Intern Med*. 1992;152:977–981.
4. Mahmoud-Ahmed AS, Suh JH. Radiation therapy for Cushing's disease: a review. *Pituitary*. 2002;5:175–180.
5. Vance ML. Pituitary radiotherapy. *Endocrinol Metab Clin North Am*. 2005;34:479–487.
6. Findling JW, Raff H. Clinical Review: Cushing's Syndrome: Important Issues in Diagnosis and Management. *J Clin Endocrinol Metab*. 2006;91:3746–3753.
7. Hellman P, Linder F, Hennings J, et al. Bilateral adrenalect-

tomy for ectopic Cushing's syndrome-discussions on technique and indication. *World J Surg.* 2006;30:909–916.

8. Ferrer FA, MacGillivray DC, Malchoff CD, Albala DM, Shichman SJ. Bilateral laparoscopic adrenalectomy for adrenocorticotropin dependent Cushing's syndrome. *J Urol.* 1997;157:16–18.

9. Winter JM, Talamini MA, Stanfield CL, et al. Thirty robotic adrenalectomies: a single institution's experience. *Surg Endosc.* 2006;20(1):119–124.

10. Acosta E, Pantoja JP, Gamino R, Rull JA, Herrera MF. Laparoscopic versus open adrenalectomy in Cushing's syndrome and disease. *Surgery.* 1999;126:1111–1116.

11. Bonjer HJ, Sorm V, Berends FJ, et al. Endoscopic retroperitoneal adrenalectomy: lessons learned from 111 consecutive cases. *Ann Surg.* 2000;232:796–803.

12. Vella A, Thompson GB, Grant CS, van Heerden JA, Farley DR, Young WF. Laparoscopic adrenalectomy for adrenocorticotropin-dependent Cushing's syndrome. *J Clin Endocrinol Metab.* 2001;86:1596–1599.

13. Hawn MT, Cook D, Deveney C, Sheppard B. Quality of life after laparoscopic bilateral adrenalectomy for Cushing's disease. *Surgery.* 2002;132:1064–1069.

14. Jager E, Heintz A, Junginger T. Synchronous bilateral endoscopic adrenalectomy: experiences after 18 operations. *Surg Endosc.* 2004;18:314–318.

15. Takata MC, Kebebew E, Clark OH, Duh QY. Laparoscopic bilateral adrenalectomy: results of 30 consecutive cases. *Surg Endosc.* 2008;22:202–207.