

Re-Vitrectomy versus Combined Re-Vitrectomy with Scleral Buckling for Pediatric Recurrent Retinal Detachment

Omar Al Abdulsalm¹, Hussain Al Habboubi^{2,3}, Marco Mura², Abdulelah Al-Abdullah^{2,4}

¹Ophthalmology Division, King Abdulaziz Hospital (Ministry of National Guard Health Affairs), King Abdullah International Medical Research Center (KAIMRC), Al Ahsa, Saudi Arabia; ²Vitreoretinal Division, King Khaled Eye Specialist Hospital, Riyadh, Saudi Arabia; ³Ophthalmology Division, Prince Mohammed Bin Abdulaziz Hospital, Medina, Saudi Arabia; ⁴Ophthalmology Department, Johns Hopkins Aramco Healthcare, Dhahran, Saudi Arabia

Correspondence: Omar Al Abdulsalm, Ophthalmology Division, King Abdulaziz Hospital (Ministry of National Guard Health Affairs), King Abdullah International Medical Research Center (KAIMRC), Al Ahsa, Saudi Arabia, Tel +966 504859424, Email alabdulsalamom@ngha.med.sa

Purpose: To compare re-vitrectomy versus combined re-vitrectomy with scleral buckling (SB) for pediatric recurrent rhegmatogenous retinal detachment (RRD) following failed primary pars plana vitrectomy (PPV).

Methods: This was a retrospective, comparative case series of pediatric patients (under 18 years) who underwent secondary RRD procedures after failed primary PPV. Patients were divided into the re-vitrectomy and the combined re-vitrectomy with SB groups. The primary outcome was the anatomical success rate for each procedure. The secondary outcomes were changes in best-corrected visual acuity (BCVA) and postoperative complications.

Results: In the re-vitrectomy group (30 eyes), the final anatomical success rate was 83.3% (25/30) after a mean follow-up of 21.7 + 6.9 months. The final anatomical success rate in the combined re-vitrectomy/SB group (23 eyes) was 73.9% (17/23) after a mean follow-up of 26.5 + 7.7 months. There was no statistically significant difference in the final anatomical success rate ($P = 0.41$) and the mean change in BCVA ($P = 0.37$) between the two groups. Even though not statistically significant, the combined re-vitrectomy/SB group had a lower incidence of postoperative complications ($P = 0.25$).

Conclusion: Re-vitrectomy alone provides similar anatomical and functional outcomes to combined re-vitrectomy/SB for pediatric recurrent RRD after failed primary PPV.

Keywords: pars plana vitrectomy, pediatric rhegmatogenous retinal detachment, recurrent retinal detachment, re-vitrectomy, scleral buckle

Introduction

In the pediatric population, rhegmatogenous retinal detachment (RRD) is an uncommon ocular condition, accounting for 3–12% of all retinal detachments.^{1,2} Unlike adults, children with RRD often represent a challenge to the operating surgeon for several reasons. They usually present late with macula-off RRD, proliferative vitreoretinopathy (PVR), and a longstanding retinal detachment resulting from late diagnosis. Furthermore, they often have underlying predisposing factors such as trauma, congenital or structural abnormalities, myopia, and previous ophthalmic surgery that can affect visual prognosis.¹

Several retrospective studies have evaluated the primary surgical procedures for pediatric RRD.^{2–20} To the best of our knowledge, this is the first study to date to compare the surgical options for pediatric recurrent RRD.

Patients and Methods

This study was a retrospective, institutional, interventional, comparative case series of pediatric patients (under 18 years) who underwent secondary RRD procedures performed at King Khaled Eye Specialist Hospital, Riyadh, Saudi Arabia, between June 2014 to August 2016. Patients were included in the study if they had recurrent detachment after failed primary pars plana vitrectomy (PPV) irrespective of lens status, location and number of retinal breaks, macular

involvement, and preoperative PVR. Patients were excluded if they presented with tractional retinal detachment before the primary procedure or had less than 12 months of follow-up. The study protocol adhered to the tenets of the Declaration of Helsinki and was approved by the affiliated hospital's institutional review board. The decision of surgical repair method by re-vitreotomy or combined re-vitreotomy with scleral buckling (SB) was made at the surgeon's discretion. All procedures were performed by experienced vitreoretinal surgery consultants or fellows under complete supervision. Written consent was obtained from all patients before surgery.

Preoperative data included the patient's demographic information, details of the primary RRD surgery, best-corrected visual acuity (BCVA), intraocular pressure (IOP), lens status (pseudophakic, phakic, or aphakic), etiology of RRD, location, and the number of retinal breaks, preoperative PVR grade C or higher, whether the detachment is total or subtotal, and if the macula is attached or detached before recurrent RRD repair. Visual acuity was measured using the Snellen or Sheridan Gardiner chart, as appropriate. Intraoperative data included the method of surgical repair, type of intraocular tamponade agent used, and if retinectomy was performed during the procedure. Postoperative data included retina status (attached or detached), reoperations number, follow-up duration, the last documented BCVA and IOP, and postoperative complications.

Surgical Technique

All the surgeries were performed under general anesthesia. Patients undergoing re-vitreotomy received a standard 3-port 23-gauge PPV using a noncontact wide-angle viewing system (Binocular Indirect Ophthalmomicroscope; Oculus, Wetzlar, Germany). In silicon oil-filled eyes, the silicon oil was evacuated first, then triamcinolone acetamide-assisted removal of residual posterior cortical vitreous was performed. For cases with PVR, membranes were peeled with the assistance of staining dyes. Relaxing retinectomy was performed at the surgeon's discretion. Fluid-air exchange was completed, and subretinal fluid was drained through existing breaks or retinotomy. Endolaser photocoagulation was applied around the retinal breaks or/and 360° up to the Ora Serrata. Patients received either non-expansile perfluoropropane (C3F8) in air (14–16%), sulfur hexafluoride (SF6) in air (20%), conventional silicone oil (1300 or 5000-centistokes), or heavy silicone oil (HSO) for tamponade. The sclerotomies were sutured in all cases. The SB was placed before starting vitrectomy for patients who underwent combined re-vitreotomy with SB. These patients received a 360° encircling band (2.5–4.0 mm in width) sutured to the sclera using 5-0 nylon suture and secured with a Watzke sleeve. In phakic eyes with significant cataracts, simultaneous lens aspiration and intraocular lens (IOL) implantation or pars plana lensectomy was performed at the surgeon's discretion.

Data Analysis

The study's primary outcome was the anatomical success rate for each recurrent RRD procedure (re-vitreotomy alone versus combined re-vitreotomy/SB) following failed primary PPV. Anatomical success was defined as total retinal reattachment up to the last follow-up. If silicone oil was used, success was considered if the retina was flat after silicone oil removal or if the retina remained attached with silicone oil in situ for ocular survival. The secondary outcomes were changes in BCVA and postoperative complications. The Snellen visual acuity was converted to the logMAR values developed by Ferris et al²¹ for statistical analysis. The logMAR values of hand movements visual acuity were assigned +3.0 logMAR, and counting fingers visual acuity was assigned +2.0 logMAR according to methods published by Holladay.²² SPSS statistics software version 16.0 (SPSS, Chicago, IL) was utilized for outcomes assessment. Fisher exact test was used for categorical data, and the Mann–Whitney *U*-test was used for continuous data to compare demographic and clinical data between the two treatment groups. Odds ratios (ORs) and 95% confidence intervals (CIs) were used to compare anatomical success rates. A paired *t*-test was used to evaluate BCVA changes within the groups. Statistical significance was defined as $P \leq 0.05$.

Results

Baseline Characteristics

This study included 53 eyes of 51 pediatric patients who underwent recurrent RRD repair after failed primary PPV. Patients were divided into two groups based on the method of surgical repair (re-vitrectomy group and combined re-vitrectomy/SB group). The re-vitrectomy group included 30 eyes of 29 patients (21 male and eight female), and the combined re-vitrectomy/SB group included 23 eyes of 22 patients (15 male and seven female). The mean age of patients in the re-vitrectomy group was 10.9 ± 3.7 years and 10.3 ± 4.3 years in the combined

Table 1 Baseline Characteristics of the Patients in the Re-Vitrectomy and Re-Vitrectomy/SB Groups

	R-Vitrectomy (n = 30)	R-Vitrectomy/SB (n = 23)	P (Method)
Age (years, mean \pm SD)	10.9 \pm 3.7	10.3 \pm 4.3	0.63 (MW)
Sex (male/female)	21/8	15/7	0.77 (F)
Follow-up (months, mean \pm SD)	21.7 \pm 6.9	26.5 \pm 7.7	0.03 (MW)
Laterality (right/left, n)	17/13	8/15	0.17 (F)
Onset of primary RRD, n (%)			0.57 (F)
• Acute	19 (63.3%)	12 (52.2%)	
• Chronic	11 (36.7%)	11 (47.8%)	
Etiology, n (%)			
• Trauma	15 (50%)	7 (30.4%)	0.17 (F)
• Congenital/developmental	8 (26.7%)	6 (26.1%)	1.00 (F)
• High myopia	6 (20%)	7 (30.4%)	0.52 (F)
• Previous ocular surgery	1 (3.3%)	3 (13%)	0.31 (F)
Tamponade in primary RRD surgery, n (%)			1.00 (F)
• Conventional SO	23 (76.7%)	18 (78.3%)	
• Heavy SO	5 (16.7%)	4 (17.4%)	
• C3F8	2 (6.7%)	1 (4.3%)	
Lens (before recurrent RRD surgery), n (%)			
• Phakic	18 (60%)	14 (60.9%)	1.00 (F)
• Pseudophakic	4 (13.3%)	2 (8.7%)	0.69 (F)
• Aphakic	8 (26.7%)	7 (30.4%)	0.77 (F)
Extent of detached retina, n (%)			1.00 (F)
• Total	8 (26.7%)	6 (26.1%)	
• Subtotal	22 (73.3%)	17 (73.9%)	
Macula detached, n (%)	29 (96.7%)	23 (100%)	1.00 (F)
Number of breaks, n (%)			
• Single	7 (23.3%)	9 (39.1%)	0.24 (F)
• Multiple	12 (40%)	10 (43.5%)	0.36 (F)
• No break identified	11 (36.7%)	4 (17.4%)	0.14 (F)
Location of breaks, n (%)			0.22 (F)
• Inferior	7 (36.8%)	11 (57.9%)	
• Non-inferior	12 (63.2%)	8 (42.1%)	
Presence of PVR, n (%)	21 (70%)	15 (65.2%)	0.77 (F)
Intentional retinotomy, n (%)	5 (16.7%)	2 (8.7%)	0.69 (F)
Retinectomy, n (%)	9 (30%)	3 (13%)	0.19 (F)
Tamponade in recurrent RRD surgery, n (%)			
• Conventional SO	18 (60%)	11 (47.8%)	0.42 (F)
• Heavy SO	7 (23.3%)	10 (43.5%)	0.15 (F)
• C3F8	4 (13.3%)	1 (4.3%)	0.37 (F)
• SF6	1 (3.3%)	1 (4.3%)	1.00 (F)
SO was removed in, n (%)	13 (43.3%)	9 (39.1%)	0.79 (F)

Note: Bold text indicates statistical significance ($P \leq 0.05$).

Abbreviations: SB, scleral buckle; SD, standard deviation; MW, Mann-Whitney U-test; F, Fisher exact test; RRD, rhegmatogenous retinal detachment; PVR, proliferative vitreoretinopathy; SO, silicone oil.

re-vitrectomy/SB group ($P = 0.63$). The mean follow-up duration was 21.7 ± 6.9 months and 26.5 ± 7.7 months in the re-vitrectomy and combined re-vitrectomy/SB groups, respectively ($P = 0.03$).

A detailed comparison of baseline characteristics and interventions between the two groups is summarized in (Table 1). As shown, the two groups were well balanced respective to age, sex, lens status, macular detachment, the extent of a detached retina, tear number and location, presence of PVR, retinectomy, and the type of intraocular tamponade used in secondary RRD procedures (Table 1).

Anatomical Results

The re-attachment rate with one secondary RRD surgery was 60% (18/30 eyes) in the re-vitrectomy group, and 65.2% (15/23 eyes) in the combined re-vitrectomy/SB group (OR, 0.80; 95% CI, 0.26–2.47; $P = 0.69$). The final anatomical success rate for eyes treated with re-vitrectomy alone was 83.3% (25/30 eyes) compared with 73.9% (17/23 eyes) for eyes treated with combined re-vitrectomy/SB. No statistically significant difference in the final anatomical success was found between the two methods of secondary RRD repair with an OR: 1.76 (95% CI, 0.46–6.72; $P = 0.41$) (Table 2).

The final anatomical success rate of patients with PVR in the re-vitrectomy group was 76.2% (16/21 eyes), while in the combined re-vitrectomy/SB group was 66.7% (10/15 eyes), (OR, 1.60; 95% CI, 0.37–6.96; $P = 0.53$).

The mean number of re-attachment operations was 1.4 ± 0.7 in the re-vitrectomy group and 1.3 ± 0.6 in the combined re-vitrectomy/SB group. This difference was not statistically significant ($P = 0.79$) (Table 3). The flowchart of the study subjects is displayed in (Figure 1).

Visual Results

The mean preoperative BCVA of patients in the re-vitrectomy group was 2.48 ± 0.79 logMAR, and 2.57 ± 0.76 logMAR in the combined re-vitrectomy/SB group ($P = 0.75$). The mean postoperative BCVA at final follow-up was 1.86 ± 1.01 logMAR, and 1.77 ± 0.99 logMAR in the re-vitrectomy group and the combined re-vitrectomy/SB group, respectively

Table 2 Anatomical and Visual Results of the Patients in the Re-Vitrectomy and Re-Vitrectomy/SB Groups

	Re-Vitrectomy (n = 30)	Re-Vitrectomy/SB (n = 23)	P (Method)
Re-attachment rate with one secondary RRD surgery, n (%)	18 (60%)	15 (65.2%)	0.69 (OR, 0.80; 95% CI, 0.26–2.47)
Final anatomical success, n (%)	25 (83.3%)	17 (73.9%)	0.41 (OR, 1.76; 95% CI, 0.46–6.72)
Preoperative BCVA in logMAR (Mean \pm SD)	2.48 \pm 0.79	2.57 \pm 0.76	0.75 (MW)
Postoperative BCVA at final follow-up in logMAR (Mean \pm SD)	1.86 \pm 1.01	1.77 \pm 0.99	0.81 (MW)
Change in BCVA in logMAR (mean \pm SD)	0.62 \pm 0.78	0.80 \pm 0.97	0.37 (MW)
P value of change in BCVA (paired t-test)	0.0001	0.0006	

Note: Bold text indicates statistical significance ($P \leq 0.05$).

Abbreviations: SB, scleral buckle; RRD, rhegmatogenous retinal detachment; OR, odds ratio; CI, confidence interval; BCVA, best corrected visual acuity; logMAR, logarithm of the minimum angle of resolution; SD, standard deviation; MW, Mann–Whitney U-test.

Table 3 Number of Re-Attachment Operations of the Patients in the Re-Vitrectomy and Re-Vitrectomy/SB Groups

	Re-Vitrectomy (n = 30)	Re-Vitrectomy/SB (n = 23)	P (Method)
Mean number of reoperations \pm SD	1.4 \pm 0.7	1.3 \pm 0.6	0.79 (MW)
Number of re-attachment operations			
• One, n (%)	21 (70%)	17 (73.9%)	
• Two, n (%)	7 (23.3%)	5 (21.7%)	
• Three, n (%)	1 (3.3%)	1 (4.3%)	
• Four, n (%)	1 (3.3%)	0 (0%)	

Abbreviations: SB, scleral buckle; SD, standard deviation; MW, Mann–Whitney U-test.

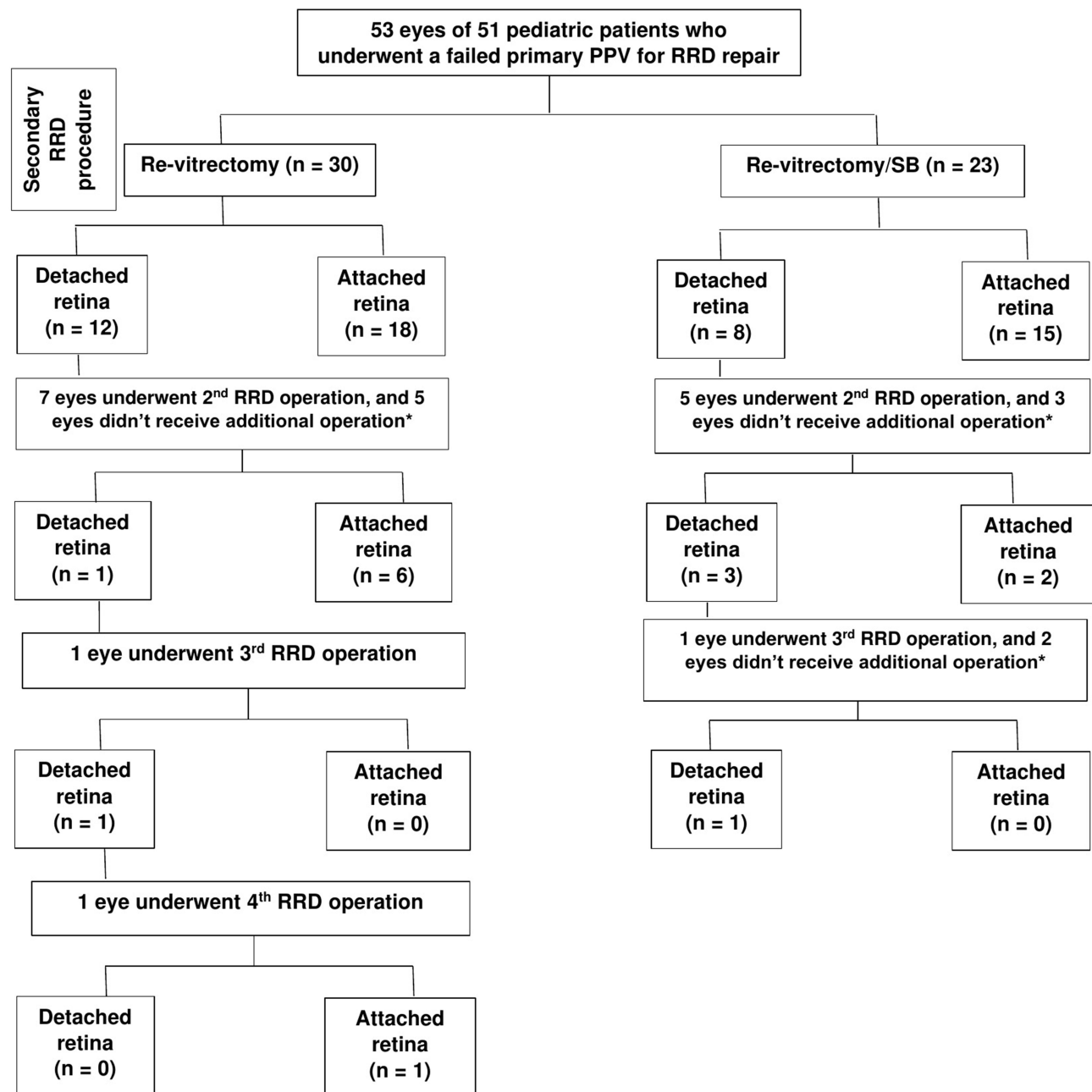


Figure 1 Flowchart of study subjects. *These eyes did not receive additional operation because they were either deemed inoperable, lost to follow-up, or due to patients' parental refusal.

Abbreviations: PPV, pars plana vitrectomy; SB, scleral buckle; RRD, rhegmatogenous retinal detachment.

($P = 0.81$). There was no significant difference in the mean change in BCVA between patients in both groups (0.62 ± 0.78 logMAR in the re-vitrectomy group vs 0.80 ± 0.97 logMAR in the combined re-vitrectomy/SB group, $P = 0.37$). However, in both groups, the mean BCVA improved significantly after surgery ($P < 0.001$) (Table 2).

Complications

The postoperative complication rate was 70% (21/30 eyes) in the re-vitrectomy group compared with 52.2% (12/23 eyes) in the re-vitrectomy/SB group ($P = 0.25$). Cataract was the most commonly observed complication in both groups (88.9% of phakic eyes in the re-vitrectomy group and 57.1% of those in the combined re-vitrectomy/SB group, $P = 0.096$). In the re-vitrectomy group, four eyes had an IOP rise; two eyes were treated Medically, and two eyes subsequently underwent

Table 4 Postoperative Complications of the Patients in the Re-Vitrectomy and Re-Vitrectomy/SB Groups

	Re-Vitrectomy (n = 30)	Re-Vitrectomy/SB (n = 23)	P (Method)
Epiretinal membrane	3 (10%)	0 (0%)	0.25 (F)
Macular hole	1 (3.3%)	0 (0%)	1.00 (F)
Cataract requiring surgery	16/18 (88.9%)*	8/14 (57.1%)*	0.096 (F)
High IOP required surgery or treatment for ≥ 3 months	4 (13.3%)	4 (17.4%)	0.72 (F)
Pupillary membrane	5 (16.7%)	0 (0%)	0.06 (F)
Phthisis bulbi	1 (3.3%)	0 (0%)	1.00 (F)
Number of eyes developed complications	21 (70%)	12 (52.2%)	0.25 (F)

Note: *Number of eyes developed cataract postoperatively out of the number of phakic eyes included in the group.

Abbreviations: SB, scleral buckle; IOP, intraocular pressure; F, Fisher exact test.

filtration surgery. In the combined re-vitrectomy/SB group, four eyes had an IOP rise and were treated medically. Other complications observed in both groups are summarized in (Table 4).

Discussion

Pediatric RRDs differ from adult detachments in the anatomy, characteristics, ocular and systemic comorbidities, and prognosis. Understanding these differences guides the vitreoretinal surgeon's approach to achieve anatomical success.²³ SB is generally preferred as the first-line procedure for pediatric RRD because it offers several advantages: significantly less vitreous manipulation and cataracts formation and no need for reintervention in case of silicone oil employment during vitrectomy. PPV for pediatric RRD is more challenging due to the strong vitreoretinal adhesions and few areas with posterior vitreous detachment. Therefore, it is usually reserved for cases not amenable to conventional surgery, such as RRD with severe PVR (grade C or worse), media haze, giant and posterior retinal tears, epiretinal membranes, and colobomas. Besides its primary indications for complex cases, PPV is also performed as a second-line procedure in cases of recurrent RRD.²⁴ In selected cases, some authors performed PPV combined with SB as an initial approach when PPV was needed to reduce peripheral tractions due to PVR.^{5,14}

In cases with recurrent RRD, surgical intervention is crucial to maintain anatomical integrity and gain functional success, especially in children's future motor and intellectual development.¹ In the current study, we compare the anatomical and visual outcomes of re-vitrectomy alone versus combined re-vitrectomy with SB for recurrent RRD following failed primary PPV in pediatric patients.

Compared to adult RRD, the success rates of pediatric RRD repair has a relatively lower final anatomical success rate of 62–88% with different surgical approaches. However, the re-attachment rate with one surgery is considerably lower at 52–78%.^{2,5–16} In our study, although not reaching statistical significance, the re-attachment rate with one secondary RRD surgery was higher in the combined re-vitrectomy/SB group than the re-vitrectomy group (60% vs 65.2%, $P = 0.69$). However, the final anatomical success rate in the re-vitrectomy group was higher than the combined re-vitrectomy/SB group (83.3% vs 73.9%, $P = 0.41$). This slight difference in the final anatomical success rate was not statistically significant between the two groups. It could be related to the longer duration of follow-up and the more complicated cases in the combined re-vitrectomy/SB group. Similarly, there was no difference between the mean number of operations needed to re-attach the retina in the two groups (1.4 ± 0.7 in the re-vitrectomy group vs 1.3 ± 0.6 in the combined re-vitrectomy/SB group) ($P = 0.79$). Apart from the follow-up duration, other baseline characteristics of the patients in the two surgical groups did not differ.

Given the complexity of the RRD, all the patients in our study required PPV as the initial surgical procedure, with silicone oil tamponade in 50 out of 53 eyes (94.3%). Furthermore, all the patients had a predisposing factor to detachment.

PVR was the leading cause of recurrent detachment in our cohort of patients. The reported incidence of PVR in pediatric cases is more than in adults (29.8–37.5% vs 5–10%),⁵ possibly because of chronicity of the detachment with a higher level of inflammation and cellular proliferation.^{3,10} In our study, the overall rate of PVR \geq Grade C before the secondary RRD repair was 67.9% (36/53 eyes), which is considered higher than the previously reported rates, as we exclusively included

cases with recurrent detachment. For patients presenting with PVR in our study, combined re-vitreotomy/SB did not demonstrate superiority over re-vitreotomy alone in achieving final anatomical success.

Despite anatomical success in a large proportion of patients in our study, visual recovery was limited with a mean change in BCVA of 0.62 ± 0.78 logMAR in the re-vitreotomy group and 0.80 ± 0.97 logMAR in the combined re-vitreotomy/SB group. These changes were similar in the two groups with no statistically significant difference ($P = 0.37$). The literature has well-described factors attributing the poor visual outcome after pediatric RRD repair. They include the tendency for delayed diagnosis with a high rate of macular involvement, amblyopia at presentation, concomitant ocular abnormalities (especially patients with congenital and developmental disorders), and postoperative complications such as cataract formation, glaucoma, corneal opacity, and optic nerve head damage.⁸ Notwithstanding, the significant improvement in BCVA postoperatively within the two groups supports the notion that multiple surgical attempts to recover any amount of vision are a worthwhile endeavor and quite reasonable to attempt.

Even though not statistically significant, the combined re-vitreotomy/SB group had a lower incidence of postoperative complications (52.2%) compared to the re-vitreotomy group (70%) ($P = 0.25$). This slightly lower rate of complications observed in the combined re-vitreotomy/SB group could be related to the smaller number of patients included. The most common complication, as expected, was cataract formation in both groups. The rate of cataracts was higher in the re-vitreotomy group (88.9% of phakic eyes) compared to the combined re-vitreotomy/SB group (57.1% of phakic eyes) ($P = 0.096$). The rate of elevated IOP was similar in the two groups. Furthermore, other complications, including epiretinal membrane, macular hole, pupillary membrane, and phthisis bulbi, were observed only in the re-vitreotomy group.

There are certain inherent limitations to this study. First, it was a retrospective study that included a small number of patients due to the low incidence of pediatric RRD. Second, it was conducted in a tertiary center, and referral biases could not be excluded. Third, there was a lack of long follow-up duration to evaluate the long-term outcomes of the two surgical approaches. Finally, many of the patients described still had silicone oil in their eyes at the last follow-up visit.

According to our results, re-vitreotomy alone provides similar anatomical and functional outcomes compared to combined re-vitreotomy/SB for pediatric recurrent RRD after failed primary PPV. Further randomized prospective studies in more patients are needed to compare these two procedures for pediatric recurrent RRD.

Brief Summary Statement

This is the first study to compare re-vitreotomy versus combined re-vitreotomy with scleral buckling (SB) for pediatric recurrent rhegmatogenous retinal detachment (RRD) following failed primary pars plana vitrectomy. Our results suggest that re-vitreotomy alone provides similar anatomical and functional success rates than combined re-vitreotomy/SB for pediatric recurrent RRD.

Acknowledgment

The study's abstract was presented as a Scientific Poster at the 18th European Vitreoretinal Society Meeting, Prague, Czech Republic (August 30 – September 02, 2018).

Disclosure

The authors declared that there is no conflict of interest.

References

1. Soliman MM, Macky TA. Pediatric rhegmatogenous retinal detachment. *Int Ophthalmol Clin*. 2011;51(1):147–171. doi:10.1097/IIO.0b013e31820099c5
2. Fong AH, Yip PP, Kwok TY, et al. A 12-year review on the aetiology and surgical outcomes of paediatric rhegmatogenous retinal detachments in Hong Kong. *Eye (Lond)*. 2016;30(3):355–361. doi:10.1038/eye.2015.212
3. Rejda R, Nowakowska D, Wrona K, et al. Outcomes of vitrectomy in pediatric retinal detachment with proliferative vitreoretinopathy. *J Ophthalmol*. 2017;2017:8109390. doi:10.1155/2017/8109390

4. Errera MH, Liyanage SE, Moya R, et al. Primary scleral buckling for pediatric rhegmatogenous retinal detachment. *Retina*. 2015;35(7):1441–1449. doi:10.1097/IAE.0000000000000480
5. Al-Zaaidi S, Al-Rashaed S, Al-Harathi E, et al. Rhegmatogenous retinal detachment in children 16 years of age or younger. *Clin Ophthalmol*. 2013;7:1001–1014. doi:10.2147/OPTH.S40056
6. Fivgas GD, Capone A Jr. Pediatric rhegmatogenous retinal detachment. *Retina*. 2001;21(2):101–106. doi:10.1097/00006982-200104000-00001
7. Butler TKH, Kiel AW. Anatomical and visual outcomes of retinal detachment surgery in children. *Br J Ophthalmol*. 2001;85:1437–1439. doi:10.1136/bjo.85.12.1437
8. Weinberg DV, Lyon AT, Greenwald MJ, et al. Rhegmatogenous retinal detachments in children: risk factors and surgical outcomes. *Ophthalmology*. 2003;110(9):1708–1713. doi:10.1016/S0161-6420(03)00569-4
9. Yokoyama T, Kato T, Minamoto A, et al. Characteristics and surgical outcomes of paediatric retinal detachment. *Eye*. 2004;18(9):889–892. doi:10.1038/sj.eye.6701341
10. Wang N-K, Tsai C-H, Chen Y-P, et al. Pediatric rhegmatogenous retinal detachment in East Asians. *Ophthalmology*. 2005;112(11):1890–1895. doi:10.1016/j.ophtha.2005.06.019
11. Chang PY, Yang CM, Yang CH, et al. Clinical characteristics and surgical outcomes of pediatric rhegmatogenous retinal detachment in Taiwan. *Am J Ophthalmol*. 2005;139:1067–1072. doi:10.1016/j.ajo.2005.01.027
12. Chen SN, Jiunn-Feng H, Te-Cheng Y. Pediatric rhegmatogenous retinal detachment in Taiwan. *Retina*. 2006;26(4):410–414. doi:10.1097/01.iae.0000238546.51756.cd
13. Gonzales CR, Singh S, Yu F, et al. Pediatric rhegmatogenous retinal detachment: clinical features and surgical outcomes. *Retina*. 2008;28(6):847–852. doi:10.1097/IAE.0b013e3181679f79
14. Wadhwa N, Venkatesh P, Sampangi R, et al. Rhegmatogenous retinal detachments in children in India: clinical characteristics, risk factors, and surgical outcomes. *J AAPOS*. 2008;12(6):551–554. doi:10.1016/j.jaapos.2008.05.002
15. Soheilian M, Ramezani A, Malihi M, et al. Clinical features and surgical outcomes of pediatric rhegmatogenous retinal detachment. *Retina*. 2009;29(4):545–551. doi:10.1097/IAE.0b013e318194fd1a
16. Rahimi M, Bagheri M, Nowroozzadeh MH. Characteristics and outcomes of pediatric retinal detachment surgery at a tertiary referral center. *J Ophthalmic Vis Res*. 2014;9(2):210–214.
17. Oono Y, Uehara K, Haruta M, Yamakawa R. Characteristics and surgical outcomes of pediatric rhegmatogenous retinal detachment. *Clin Ophthalmol*. 2012;6:939–943. doi:10.2147/OPTH.S31765
18. Yokoyama T, Kanbayashi K, Yamaguchi T. Scleral buckling procedure with chandelier illumination for pediatric rhegmatogenous retinal detachment. *Clin Ophthalmol*. 2015;9:169–173. doi:10.2147/OPTH.S75648
19. Read SP, Aziz HA, Kuriyan A, et al. Retinal detachment surgery in a pediatric population: visual and anatomic outcomes. *Retina*. 2018;38(7):1393–1402. doi:10.1097/IAE.0000000000001725
20. Smith JM, Ward LT, Townsend JH, et al. Rhegmatogenous retinal detachment in children: clinical factors predictive of successful surgical repair. *Ophthalmology*. 2018;S0161-6420(18):30087.
21. Ferris FL 3rd, Kassoff A, Bresnick GH, Bailey I. New visual acuity charts for clinical Research. *Am J Ophthalmol*. 1982;94:91–96. doi:10.1016/0002-9394(82)90197-0
22. Holladay JT. Proper method for calculating average visual acuity. *J Refract Surg*. 1997;13:388–391. doi:10.3928/1081-597X-19970701-16
23. McElnea E, Stephenson K, Gilmore S, et al. Pediatric retinal detachment: aetiology, characteristics, and outcomes. *Int J Ophthalmol*. 2018;11(2):262–266. doi:10.18240/ijo.2018.02.14
24. Nuzzi R, Lavia C, Spinetta R. Paediatric retinal detachment: a review. *Int J Ophthalmol*. 2017;10(10):1592–1603. doi:10.18240/ijo.2017.10.18

Clinical Ophthalmology

Dovepress

Publish your work in this journal

Clinical Ophthalmology is an international, peer-reviewed journal covering all subspecialties within ophthalmology. Key topics include: Optometry; Visual science; Pharmacology and drug therapy in eye diseases; Basic Sciences; Primary and Secondary eye care; Patient Safety and Quality of Care Improvements. This journal is indexed on PubMed Central and CAS, and is the official journal of The Society of Clinical Ophthalmology (SCO). The manuscript management system is completely online and includes a very quick and fair peer-review system, which is all easy to use. Visit <http://www.dovepress.com/testimonials.php> to read real quotes from published authors.

Submit your manuscript here: <https://www.dovepress.com/clinical-ophthalmology-journal>