

Received: 2019.02.08  
Accepted: 2019.03.03  
Published: 2019.03.27

## Choledochoduodenal Fistula Secondary to Peptic Ulcer Disease: A Case Report

Authors' Contribution:  
Study Design A  
Data Collection B  
Statistical Analysis C  
Data Interpretation D  
Manuscript Preparation E  
Literature Search F  
Funds Collection G

DG 1,2 **Antoine Kachi**  
ABCDEF 1 **Mouhammad Kanj**  
ABCE 1 **Charif Khaled**  
A 1 **Chady Nassar**  
A 1 **Charbel Bou Rached**  
ABCDEF 1 **Alaa Kansoun**

1 Department of General Surgery, Faculty of Medical Sciences, Lebanese University, Beirut, Lebanon  
2 Department of General Surgery, Geitaoui University Hospital, Beirut, Lebanon





**Corresponding Author:** Alaa Kansoun, e-mail: [a.kanso@hotmail.com](mailto:a.kanso@hotmail.com)  
**Conflict of interest:** None declared

**Patient:** Female, 29  
**Final Diagnosis:** Choledocho-duodenal fistula  
**Symptoms:** Abdominal pain • nausea • vomiting  
**Medication:** —  
**Clinical Procedure:** Gastro-jejunostomy • hepatico-jejunostomy  
**Specialty:** Surgery

**Objective:** Rare co-existence of disease or pathology  
**Background:** Choledochoduodenal fistula is an uncommon complication secondary to peptic ulcer disease. Determining this diagnosis is challenging especially when confronted with unspecific physical and radiological findings.  
**Case Report:** Here we report a case of a 29-year-old Ethiopian female who presented to Geitaoui University Hospital in Beirut, Lebanon with epigastric pain and was diagnosed to have of choledochoduodenal fistula.  
**Conclusions:** Choledochoduodenal fistula is a rare complication of duodenal ulcer and this case report may help clinicians to identify suspected cases of this entity with similar presentations.

**MeSH Keywords:** Biliary Fistula • Intestinal Fistula • Peptic Ulcer

**Full-text PDF:** <https://www.amjcaserep.com/abstract/index/idArt/915600>

 919  1  3  28



## Background

Internal biliary fistulas represent only 2% of all biliary diseases [1]. The most commonly reported types of fistula in order of frequency are: cholecystoduodenal, choledochoduodenal, cholecystocolonic, and cholecystogastric [1,2]. These abnormal communications are usually related to biliary lithiasis [3]. Choledochoduodenal fistula accounts for 5–25% of all internal biliary fistulas [4]. Mostly duodeno-biliary fistula is caused by gall stones and subsequent inflammation of the bile duct; however, other causes, including duodenal ulcer, are possible [5]. Rarely, an entero-biliary fistula can be attributed to a benign ulcer [6], while giant peptic ulcers may perforate into the common bile duct [7]. Notably, duodenal ulcer *per se* can cause fistula to other organs such as duodeno-pleural [8], duodeno-portal [9], or duodeno-ureteric fistula [10]. Being a rare complication of peptic ulcer disease [11], its diagnosis and management remains challenging. However, with the recent advances in hepato-biliary imaging techniques, suspecting this entity has become more plausible [12], and thanks to these available endoscopic approaches, confirming the presence of choledochoduodenal fistula has become attainable in most cases [12]. Here we report a case of choledochoduodenal fistula, which was ulcerogenic in origin and had a challenging diagnosis.

## Case Report

We present a case of a 29-year-old Ethiopian female, who had recurrent episodes of abdominal pain, and who presented to the Emergency Department complaining of severe epigastric pain. Her pain had been increasing in intensity for the past couple of days, and was associated with nausea and vomiting. Upon presentation, the patient was febrile and icteric. Abdominal examination revealed localized epigastric tenderness. Initial blood workup revealed leukocytosis, elevated C-reactive protein (CRP) and disturbed liver function tests as shown in Table 1.

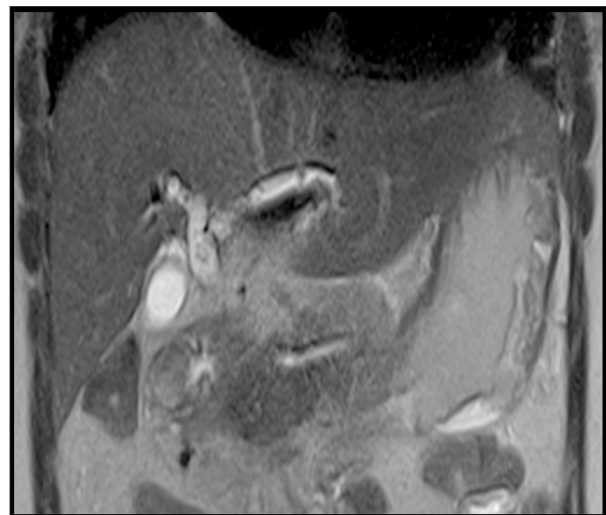
Abdominal ultrasound showed a distended gallbladder containing micro-lithiasis with dilatation of the intra and extra-hepatic bile ducts. Moreover, magnetic resonance cholangiopancreatography showed diffuse dilatation of intra and extra-hepatic bile ducts in the absence of stones or obstacles along with multiple hypointense images at the level of the intra-hepatic bile ducts, consistent with aerobilia as shown in Figure 1.

An attempt to do endoscopic retrograde cholangiopancreatography failed because the duodenum could not be bypassed due to the inflammatory process in the pyloric region as shown in Figure 2.

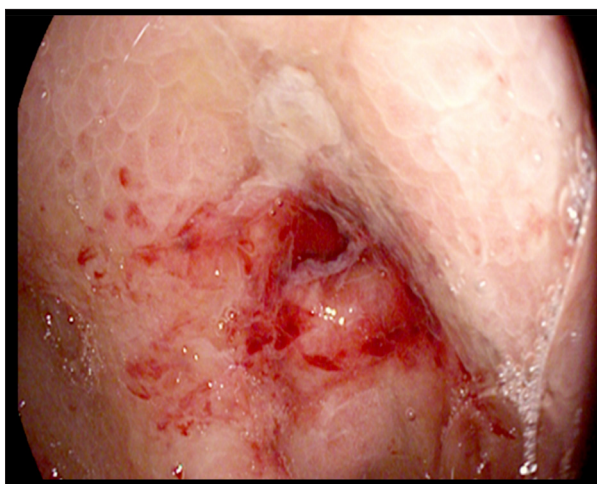
**Table 1.** An overview of the patient's initial laboratory workup.

Results	Normal range
Hematocrit: 38	36–48%
Hemoglobin: 12.9	12–16 g%
Red blood cells: 4.58	4–6 million/mm <sup>3</sup>
White blood cells: 1 1500*	4000–10 000/mm <sup>3</sup>
Neutrophils: 90*	40–80%
Lymphocytes: 8*	20–40%
Platelets: 250000	150 000–300 000/mm <sup>3</sup>
C-reactive protein: 52*	0–5 mg/L
Albumin: 2.5*	3.4–5 g%
Bilirubin	
Direct: 2.8*	0–0.2 mg%
Total: 4.9*	0–1 mg%
Alkaline phosphatase: 123*	37–98 U/L
ALT: 436*	<65 U/L
AST: 335*	<37 U/L
GGT: 346*	5–55 U/L
Amylase: 162*	25–115 U/L
Lipase: 106	73–393 U/L
INR: 1.68*	1
PTT: 40*	30

GGT – gamma-glutamyltransferase; ALT – alanine transaminase; AST – aspartate transaminase; INR – international normalized ratio; PTT – partial thromboplastin time.



**Figure 1.** Magnetic resonance cholangiopancreatography showing diffuse dilatation of intra and extra-hepatic bile ducts in the presence of aerobilia.



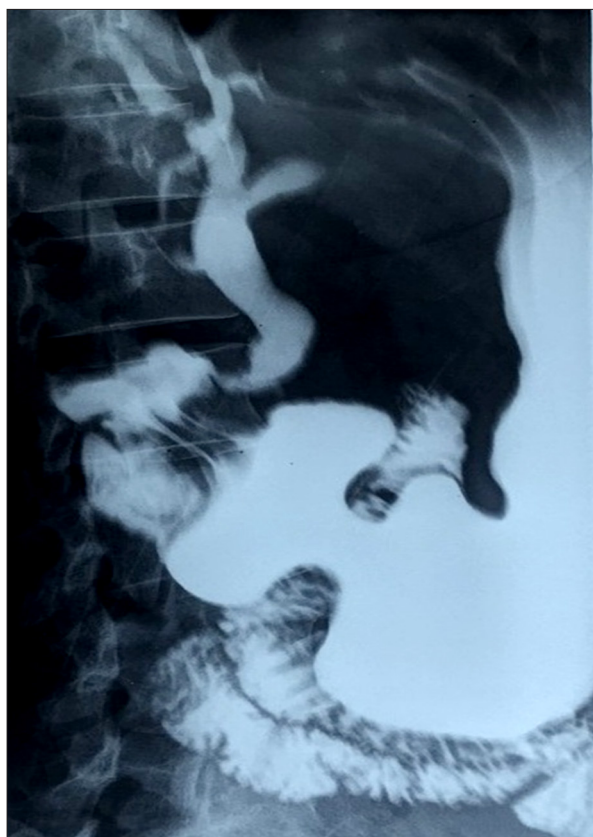**Figure 2.** Endoscopic retrograde cholangiopancreatography showing pyloric region being inflamed and ulcerated.

The examination was completed by an upper gastro-intestinal series with gastrografin swallow for better assessment of the pyloric stenosis. The examination revealed an extravasation of the contrast from the base of the duodenum at around 7 mm ulcer to the hepato-biliary tree along with a completely deformed duodenal bulb as shown in Figure 3.

The patient was diagnosed as having cholangitis secondary to a choledochoduodenal fistula. Broad spectrum antibiotic therapy was started. The patient underwent a laparotomy and a choledochoduodenal fistula was confirmed. We decided to do a cholecystectomy, a gastro-jejunostomy, and a hepatico-jejunostomy. She recovered well, and was discharged home with an uneventful post-operative period.

## Discussion

Concerning diagnostic workup, bilio-enteric fistula is usually silent and found incidentally on gastrointestinal imaging [13]. However, if present, the most common symptoms are those of cholangitis, including right upper quadrant pain, fever, and jaundice [14]; which was similar to symptoms found in our patient. It could also be associated with gastrointestinal bleeding as a complication of peptic ulcer disease [15]. Although pneumobilia can be helpful in diagnosis, it is not specific and found in only 14% to 22% of cases [16]. The presence of contrast material in the biliary tree after a barium-swallow-study, in a patient suspected to have peptic ulcer disease, is highly suggestive of entero-biliary fistula [17]. Notably, these 2 latter radiographic features may be present after endoscopic papillectomy or after surgical biliary-enteric anastomosis. However, in the absence of such events, these findings are diagnostic of entero-biliary fistula [18].



**Figure 3.** Gastrografin swallow showing fistula between the duodenum and the biliary tree.

Concerning management and despite the increased rate of choledochoduodenal fistula diagnosis, there is still no consensus regarding the treatment and management strategies. Some studies dictate that the mere presence of fistula is not an absolute indication for surgery [19] and management depends on the type and cause of fistula [20]. However, percutaneous or endoscopic interventions may be a treatment option [21–25]. However, when symptoms are poorly controlled as in a biliary obstruction or hemorrhage, surgical options prevail [21,25]. In our patient case, our patient was treated medically for cholangitis, but she did not improve, thus she underwent a double derivation and had an uneventful postoperative course. However, some reports endorse surgical management, avoiding the risk of cholangiocarcinoma [26,27]. Moreover, a high index of suspicion is required to prevent long term complications such as acute cholangitis or small bowel obstruction [28], conditions in which mortality is high and surgical management is inevitable.

## Study limitations

This study aimed to pinpoint a rare complication of a relatively common disease, however, it provides little evidence concerning the treatment plan. It is a case report that needs to

be endorsed by other studies higher in quality to allow us to know more about managing this condition.

## Conclusions

Choledochoduodenal fistula is a rare complication of duodenal ulcer. Patients may present with non-specific clinical symptoms, which makes the diagnosis difficult. Pneumobilia and the presence of contrast in the biliary tree should always alert the clinician to the possibility of choledochoduodenal fistula. Surgery should be considered for refractory cases. This case report is a reminder of a rare complication for a relatively common disease: peptic ulcer disease.

## References:

1. Reed C GF, Grafe W: Biliary enteric fistula. *Surg Gynecol Obstet*, 1981; 153: 527–31
2. Zwemer F, Coffin-Kwart VE, Conway M: Biliary enteric fistulas: Management of 47 cases in Native Americans. *Am J Surg*, 1979; 138: 301–4
3. H'ng MWC, Yim HB: Spontaneous choledochoduodenal fistula secondary to long standing ulcer disease. *Singapore Med J*, 2003; 44: 205–7
4. Wu MB, Zhang WF, Zhang YL et al: Choledochoduodenal fistula in Mainland China: A review of epidemiology, etiology, diagnosis and management. *Ann Surg Treat Res*, 2015; 89: 240–46
5. Sharma K, Kibria R, Ali S, Rao P: Primary aortoenteric fistula caused by an infected abdominal aortic aneurysm with *Mycobacterium avium* complex in an HIV patient. *Acta Gastroenterol Belg*, 2010; 73(2): 280–82
6. Shah P, Ramakantan R: Choledochoduodenal fistula complicating duodenal ulcer disease (A report of 3 cases). *J Postgrad Med*, 1990; 36: 167–68
7. Shelat V, Diddapur R: Gastrobiliary fistula from a giant gastric ulcer. *Digestive Endoscopy*, 2008; 20(4): 207–9
8. Nwose PE, Nwofor AM, Ogbuokiri UC: Duodeno-pleural fistula: A rare complication of peptic ulcer perforation. *Niger J Clin Prac*, 2006; 9(1): 84–86
9. Kinoshita H, Takifuji K, Nakatahi Y et al: Duodenoportal fistula caused by peptic ulcer after extended right hepatectomy for hilar cholangiocarcinoma. *World J Surg Oncol*, 2006; 4: 84
10. Tan SM, The CH, Tan PK: Duodeno-ureteric fistula secondary to chronic duodenal ulceration. *Ann Acad Med Singapore*, 1997; 26(6): 850–51
11. Tobolini M: Spontaneous pneumobilia revealing choledocho-duodenal fistula: A rare complication of peptic ulcer disease. *J Emerg Trauma Shock*, 2013; 6(2): 146–47
12. Zong KC, You HB, Gong JP, Tu B: Diagnosis and management of choledochoduodenal fistula. *Am Surg*, 2011; 77(3): 348–50
13. Michowitz M, Farago C, Lazarovici I, Solowiejczyk M: Choledochoduodenal fistula: A rare complication of duodenal ulcer *Am J Gastroenterol*, 1984; 79: 416–20
14. Akaydin M, Demiray O, Ferlenguez E et al: Importance of spontaneous choledochoduodenal fistulas detected during ERCP procedure. *Indian J Surg*, 2016; 2016: 216–20
15. Xi B, Jia JJ, Lin BY et al: Peptic ulcers accompanied with gastrointestinal bleeding, pylorus obstruction and cholangitis secondary to choledochoduodenal fistula: A case report. *Oncol Lett*, 2016; 11(1): 481–83
16. Fowler CL, Sternquist JC: Choledochoduodenal fistula: A rare complication of peptic ulcer disease. *Am J Gastroenterol*, 1987; 82: 269–71
17. Mallikarjunappa B, Ashish SR: Choledochoduodenal fistula: A rare case report with review of literature. *JIMSA*, 2013; 26(4): 226
18. Pagej E, Dow J: Ulcerogenic choledochoduodenal fistula. *Clin Radiol*, 1989; (40): 58
19. H'ng MWC, Yim HB: Spontaneous choledochoduodenal fistula secondary to long standing ulcer disease. *Singapore Med J*, 2003; 44: 205–7
20. Yamashita H, Chijiwa K, Ogawa Y et al: The internal biliary fistula – reappraisal of incidence, type, diagnosis and management of 33 consecutive cases. *HPB Surg*, 1997; 10(3): 143–47
21. Jaballah S, Sabri Y, Karim S: Choledochoduodenal fistula due to duodenal peptic ulcer. *Dig Dis Sci*, 2001; 46: 2475–79
22. Miyamoto S, Furuse J, Maru Y et al: Duodenal tuberculosis with a choledocho-duodenal fistula. *J Gastroenterol Hepatol*, 2001; 16: 235–38
23. Mueller XM, Tevaeairai HT, Stumpe F et al: Gastrointestinal disease following heart transplantation. *World J Surg*, 1999; 23: 650–55
24. Pivoski S, Shamma'a J: Fistula involving portal vein and duodenum at the site of a duodenal ulcer in a patient after previous extrahepatic bile duct resection and brachytherapy. *Dig Surg*, 2003; 20: 53–55
25. Topal U, Savci G, Sadikoglu MY, Tuel E: Choledochoduodenal fistula secondary to duodenal peptic ulcer: A case report. *Acta Radiol*, 1997; 38: 1007–9
26. Ohtsuka T, Tanaka M, Inoue K et al: Is peripapillary choledochoduodenal fistula an indication for endoscopic sphincterotomy? *Gastrointest Endosc*, 2001; 53: 313–17
27. Dwivedi AN, Kumar S, Rana S, Maurya B: Transmural invasion of hepatic flexure of colon causing cholecystocolic fistula by aggressive gallbladder carcinoma. *World J Surg Oncol*, 2013; 11: 86
28. Aguilar-Espinosa F, Maza-Sánchez R, Vargas-Solis F et al: Fistula colecistoduodenal, complicación infrecuente de litiasis vesicular: Nuestra experiencia en su manejo quirúrgico. *Revista de Gastroenterología de México*, 2017; 82: 287–95 [in Spanish]

## Acknowledgement

We would like to thank the Geitaoui University Hospital medical team who were helpful in providing data for this report. Also, many thanks go to our patient who allowed us to write about her case.

## Conflicts of interest

None.