

## Paroxysmal nocturnal hemoglobinuria: When delay in diagnosis and long therapy occurs

Salvatrice Mancuso,<sup>1</sup> Giuseppe Sucato,<sup>1</sup> Melania Carlisi,<sup>2</sup> Marco Santoro,<sup>2</sup> Giuseppe Tarantino,<sup>1</sup> Emilio Iannitto,<sup>1</sup> Mariasanta Napolitano,<sup>1</sup> Sergio Siragusa<sup>1</sup>

<sup>1</sup>Department of Oncology, Haematology Unit, and <sup>2</sup>Department of Surgical, Oncological and Stomatological Disciplines, University of Palermo, Italy

### Abstract

Paroxysmal nocturnal hemoglobinuria (PNH) is a rare clonal disorder characterized by hemolytic anemia, bone marrow failure and thrombosis, caused by a somatic mutation in PIG-A gene that results in the absence of CD55 and CD59, two important complement regulatory proteins. In this paper, a case of PNH is retrospectively examined looking for clinical and laboratory features, and the entire course of the disease from the onset of the symptoms is described, together with an adequate follow-up over a 7-years treatment period. In this case, the not specificity and the limited clinical relevance of the symptoms led to a delay in diagnosis. After thrombosis, Eculizumab therapy has been shown to be effective, and during seven years of follow-up no events have occurred that put the patient's life at risk. A multidisciplinary approach is crucial in cases like this, in order to allow early diagnosis and minimize the risks for the patients.

### Introduction

Paroxysmal nocturnal hemoglobinuria (PNH) is a rare clonal disease which can produce hemolysis, venous (and rarely arterial) thrombosis, and bone marrow failure.<sup>1,2</sup> A somatic mutation in a gene called PIG-A occurs in a hematopoietic stem cell that leads to deficient synthesis of GPI. Absence of one of the GPI-linked proteins on the surface of the erythrocytes is the cause of their susceptibility to complement and to intravascular hemolysis. Most of the signs and symptoms, as well as of laboratory abnormalities of PNH, may be triggered by plasma-free hemoglobin.<sup>3</sup> Although the etiology and pathophysiology of PNH are

well known and therapy is available to block intravascular hemolysis and to reduce the risk of thromboses, we need to focus on some issues that still need to be discussed. Clinical features are heterogeneous and affect several organs with progressive worsening, but in some cases non-specific symptoms appear.<sup>4</sup> These characteristics, along with the rarity of the disease, make it difficult to assess the presence of PNH and to provide the diagnosis. Furthermore, it is necessary to identify the *burden* and the activity of the disease in order to initiating therapy before major events occur.<sup>5</sup> The most common complications, such as thrombosis or kidney damage, are often particularly serious and it is helpful to share information and experience for an appropriate clinical management. We describe the case of a PNH patient with a long history of disease that may help recognizing different aspects and implications for clinical practice.

### Case Report

The patient, 49 years old, male, came under our observation in September 2009 following a hospitalization at the Division of Gastroenterology for acute abdominal pain episode accompanied by intense fatigue. He had a family history of coronary disease; he was a former smoker and moderate consumer of alcohol and coffee; he habitually did sport activities (cycling, running). The only comorbidity reported was Gilbert's syndrome. The patient had been previously hospitalized, in March 2006, for right inguinal hernioplasty. A week after surgery, abdominal pain accompanied by loss of appetite, fever and dark urine, appeared. In the following years there were about 3-4 episodes per year of abdominal pain with the same features. It is noteworthy that the pain was attenuated by non-steroidal anti-inflammatory drugs (NSAIDs). Because of these episodes, several laboratory tests were carried out that showed consistently high levels of LDH and indirect bilirubin, which is why Gilbert's syndrome was diagnosed, despite this syndrome does not cause LDH elevation. In April 2009, an abdominal computed tomography (CT) scan did not reveal any abnormal findings. In September 2011 a new episode of acute abdominal pain occurred due to which he was hospitalized at the Division of Gastroenterology. During hospitalization abdominal nuclear magnetic resonance (NMR) was performed that only demonstrated a distended gallbladder with signs of intraluminal alterations related to

Correspondence: Salvatrice Mancuso, Department of Oncology, Haematology Unit, University of Palermo School of Medicine, Via del Vespro 129, 90127, Palermo, Italy. Tel.: +39.091.6554570 - Fax: +39.091.6554402. E-mail: salvatrice.mancuso@unipa.it

Key words: paroxysmal nocturnal hemoglobinuria, thrombotic events, renal failure, Eculizumab.

Acknowledgments: the authors received no specific funding support for this work. Francesco Moscato, University of Glasgow, revised English language. Melania Carlisi, PhDst is supported, for this research, by the University of Palermo (IT), Doctoral Course of Experimental Oncology and Surgery, Cycle XXXII. Marco Santoro, PhDst is supported, for this research, by the University of Palermo (IT), Doctoral Course of Experimental Oncology and Surgery, Cycle XXXIII.

Contributions: the authors contributed equally.

Conflict of interest: the authors declare no potential conflict of interest.

Received for publication: 5 December 2017.

Revision received: 3 March 2018.

Accepted for publication: 5 March 2018.

This work is licensed under a Creative Commons Attribution-NonCommercial 4.0 International License (CC BY-NC 4.0).

©Copyright S. Mancuso et al., 2018  
Licensee PAGEPress, Italy  
*Hematology Reports* 2018; 10:7523  
doi:10.4081/hr.2018.7523

biliary sludge. At the blood tests, microcytic anemia (hemoglobin 8 g/dL, erythrocyte MCV 79.1 fL), high count of reticulocytes (3.2%,  $111.3 \times 10^3/\mu\text{L}$ ) with an increase of the indices of hemolysis (unconjugated bilirubin 1.53 mg/dL, serum lactate dehydrogenase 1924 U/L, haptoglobin <0.2 g/L), negative direct antiglobulin test (DAT) and associated iron deficiency (serum iron 27  $\mu\text{g/dL}$ , serum ferritin 9  $\mu\text{g/L}$ ) were detected. Because of anemia, hematology consultation was required, after which it was recommended to search for the PNH clone in view of the clinical history. Flow cytometric analysis with CD59 and CD55 on red blood cells, granulocytes and monocytes identified three subtypes of cells: Type I, Type II and Type III (Figure 1). The total clone size on granulocytes was 98% with CD59 and 72% with CD55. Studies of bone marrow were also carried out using bone marrow biopsy and bone marrow aspiration for cytogenetic and morphologic analysis that excluded associated blood

dyscrasias. After the diagnosis, supportive care has been practiced with only two red cell concentrates, short steroid therapy and iron supplements. After about three weeks the patient was again hospitalized for painful crises with intense dark urine, vomiting, and seriously compromised general conditions. He was found to have severe renal impairment with creatinine levels of 5.5 mg/dL. A gradual improvement of the clinical picture and renal function was obtained with conservative medical therapy by optimizing hemodynamic and fluid status, until the complete resolution of all symptoms and normalization of laboratory values. Later, during hospitalization, a new episode of severe acute abdomen pain with peritoneal signs occurred and an abdominal CT scan showed superior mesenteric vein thrombosis. The patient underwent urgent surgery during which multiple areas of ischemic necrosis involving the small bowel were observed and a bowel resection of three clearly necrotic areas was performed. After that, he started an oral anticoagulant therapy for thrombosis and Eculizumab as a specific treatment for PNH. Currently, after six years of treatment with Eculizumab and anticoagulant therapy with vitamin K-antagonist (Warfarin) the patient maintains good health conditions. The initial symptomatology, characterized by marked asthenia and recurrent acute abdominal pain crises, disappeared. Furthermore, no hemolytic crises have emerged while hemoglobin levels have been stable at around 12-13 g/dL. A known feature of Eculizumab treatment, namely signs of extra vascular hemolysis, still persist with negative direct antiglobulin test, which however do not affect the patient's quality of life.

## Discussion

To our knowledge, this is the first case report with an exhaustive description of all three phases of long clinical history: before and after diagnosis, and after institution of therapy. In this patient, some elements have delayed the diagnosis. Particularly, relevant signs of hemolysis, such as the chronic low grade unconjugated hyperbilirubinemia, were attributed to the concomitant Gilbert's syndrome; then, the anemia was associated with iron deficiency and the abdominal pain appeared related to the hernioplasty and was seen as an unspecific symptom. Furthermore, several episodes of what could be hemoglobinuria were missed, likely regarded as urinary tract infections. When the patient came to our expert opin-

ion, other symptoms such as severe anemia associated with hyperbilirubinemia and increasing lactate dehydrogenase (LDH) led us to look for the PNH clone. Therefore, diagnosing PNH still represents a challenge and creates unique issues for early detection. Little knowledge about this rare disease and the lack of distinctive clinical features are the cause for diagnostic delay. This may emphasize the need for high clinical suspicion of PNH to avoid disease complications. As thrombosis is the leading cause of mortality, it is important to recognize the risk of thrombotic events in PNH patients regardless of their hemolytic status to assure closer monitoring. A multidisciplinary approach is crucial to acknowledge the disease, anticipate the diagnosis and avoid the development of complications linked to the natural history of the disease. Evidence of the implications of lifelong therapy with Eculizumab emphasizes the need for open study groups that provide education for different medical specialties to increase the rate of early diagnosis.

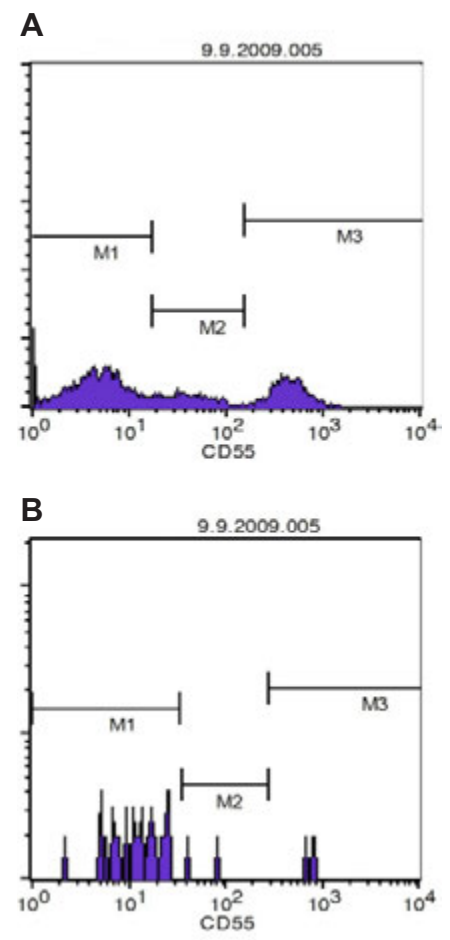
The appearance of acute renal failure is an interesting aspect of this clinical case. Whereas it is well known that chronic kidney disease is a common and progressive clinical complication and a major cause of mortality in PNH, acute dysfunction occurs less frequently and its description is available in case reports.<sup>6</sup> Severe hemolytic episodes with massive hemoglobinuria can lead to acute renal failure that generally is one of the first possible clinical manifestations of PNH that allows subsequent disease diagnosis. In our case, the disease was already known at this point and renal impairment was managed conservatively. As reported, early diagnosis and treatment of acute renal failure are crucial to prevent further damage and restore normal function. In similar cases, when performed, renal biopsy and NMR showed signs of acute tubular necrosis and renal hemosiderosis.

PNH is a prothrombotic state leading to thrombosis at unusual sites.<sup>7</sup> Acute mesenteric venous thrombosis (MVT) is a rare, but life-threatening medical emergency.<sup>8</sup>

Involvement of superior mesenteric vein and of mesenteric venous arches may lead to intestinal ischemia, bowel infarction and ileus in one third of the patients, with a mortality rate of 20%. However, the natural history of acute MVT is still uncertain and modified by medical intervention.<sup>9</sup> In our case, prior PNH diagnosis, increased clinical awareness, improved diagnostic techniques and early recognition facilitated the management of the occlusive event with a favorable outcome. The emergency surgery and subsequent anticoagulation were necessary to optimize the patient's chances of

survival.

Eculizumab is the only drug approved for the treatment of PNH and has become the current standard for therapy.<sup>10,11</sup> Eculizumab has changed the natural history of the disease by increasing the overall survival and reducing thrombotic events.<sup>12,13</sup> Data on clinical benefits of Eculizumab in patients with no transfusion history in the International Paroxysmal Nocturnal Haemoglobinuria Registry demonstrated the significance of disease burden and disease activity.<sup>14,15</sup> High Disease Activity (HAD), was defined by hemolysis (LDH  $\geq 1.5 \times$  upper limit of normal) and the presence of one or more of the following signs or symptoms: fatigue, hemoglobinuria, abdominal pain, dyspnea, anemia, major adverse vascular event, dysphagia or erectile dysfunction. PNH patients without transfusion history, but with only minor



**Figure 1.** Flow cytometry CD55-based assay for PNH granulocytes (A) and monocytes (B). The flow cytometric analysis reveals the presence of an intermediate peak, which testifies to the existence of a second clone (M2).

hemolysis-related clinical manifestations, are at risk of early mortality and can now be treated with Eculizumab according to the update of the European approval.<sup>16</sup> Indeed, abdominal pain, the predominant symptom in our patient during the first years of clinical course, is associated with a 3.6-fold greater risk of thrombosis and mortality.<sup>17</sup> Therefore, a new chapter of PNH's history is opening, on the basis of the new therapeutic indications.

Our case, where therapy was started according to the previous indications after major adverse events, confirms the need for an early treatment.<sup>18</sup> With the onset of specific therapy with Eculizumab our patient did not require any transfusion maintaining hemoglobin levels around 12 g / dl, did not suffer from other thrombotic events, and had normal kidney function without chronic renal damage. The only sign of disease remains a persistent indirect hyperbilirubinaemia and mildly elevated LDH levels, probably due to phenomena of extravascular hemolysis related to the opsonization of PNH erythrocytes by uncontrolled complement component C3 activation. Residual extravascular hemolysis is a known possible mechanism that may explain the persisting hyperbilirubinemia and anemia in PNH patients treated with Eculizumab.<sup>19</sup>

*Breakthrough* intravascular hemolysis was excluded and the effect of this occurrence is not clinically meaningful. In our patient, direct antiglobulin test, performed before and during Eculizumab therapy, resulted negative. Hill et al. demonstrated that the direct antiglobulin test was positive in 68% of the treated patients and the limited sensitivity of the test can explain a proportion of negative results.<sup>19</sup>

This clinical case also raises another problem: the need to continue lifelong anticoagulation as secondary profilaxis in PNH patients who are well controlled on Eculizumab therapy. Anticoagulation is the mainstay of treatment for acute thrombotic events, but it appears not to contribute to reduce significantly the thrombotic risk in both Eculizumab-treated and not patients. By contrast, Eculizumab decreases markedly the risk regardless of the anticoagulation. At the present state, in three PNH patients with previous thrombotic events, successful discontinuation of anticoagulation after Eculizumab therapy was reported.<sup>20</sup> However, in the absence of randomized clinical trial, only the experience and longer follow-up can support more precise indications.

## Conclusions

In conclusion, this case report captures different aspects of the complexity of the disease. The patient was followed for a long period and his history may be particularly representative of the spectrum of issues associated with the management of PNH. One of the main points is that, at the beginning, the clinical picture is likely to be encountered in everyday practice and then, over time, the disease burden worsens.

Despite the success of Eculizumab therapy in improving health status and life expectancy, major challenges remain. The rarity of the disease does not allow to organize clinical trials that can meet outstanding problems, so a descriptive approach using registry data or case reports plays a fundamental role to further improve the research agenda.

## References

1. Brodsky RA. Narrative review: paroxysmal nocturnal hemoglobinuria: the physiology of complement-related hemolytic anemia. *Ann Intern Med* 2008;148:587-95.
2. Parker CJ. Historical aspects of paroxysmal nocturnal haemoglobinuria: defining the disease. *Br J Haematol* 2002;117:3-22.
3. Hillmen P, Hows JM, Luzzatto L. Two distinct patterns of glycosylphosphatidylinositol (GPI) linked protein deficiency in the red cells of patients with paroxysmal nocturnal haemoglobinuria. *Br J Haematol* 1992;80:399-405.
4. Brodsky RA. Paroxysmal nocturnal hemoglobinuria. *Blood* 2014;124:2804-11.
5. Loschi M, Porcher R, Barraco F, et al. Impact of eculizumab treatment on paroxysmal nocturnal hemoglobinuria: A treatment versus no-treatment study. *Am J Hematol* 2016;91:366-70.
6. Chow KM, Lai FM, Wang AY, et al. Reversible renal failure in paroxysmal nocturnal hemoglobinuria. *Am J Kidney Dis* 2001;37:E17.
7. Hillmen P, Muus P, Dührsen U, et al. Effect of the complement inhibitor eculizumab on thromboembolism in patients with paroxysmal nocturnal hemoglobinuria. *Blood* 2007;110:4123-8.
8. Choudhary AM, Grayer D, Nelson A, Roberts I. Mesenteric venous thrombo-

sis: a diagnosis not to be missed! *J Clin Gastroenterol* 2000;31:179-82.

9. Hotoleanu C, Andercou O, Andercou A. Mesenteric venous thrombosis: clinical and therapeutic approach. *Int Angiol* 2008;27:462-5.
10. Hill A, Hillmen P, Richards SJ, et al. Sustained response and long-term safety of eculizumab in paroxysmal nocturnal hemoglobinuria. *Blood* 2005;106:2559-65.
11. Hillmen P, Young NS, Schubert J, et al. The complement inhibitor eculizumab in paroxysmal nocturnal hemoglobinuria. *N Engl J Med* 2006;355:1233-43.
12. Hillmen P, Muus P, Röth A, et al. Long-term safety and efficacy of sustained eculizumab treatment in patients with paroxysmal nocturnal haemoglobinuria. *Br J Haematol* 2013;162:62-73.
13. Malato A, Saccullo G, Lo Coco L, et al. Thrombotic complications in paroxysmal nocturnal haemoglobinuria: a literature review. *Blood Transfus* 2012;10:428-35.
14. Schrezenmeier H, Muus P, Socié G, et al. Baseline characteristics and disease burden in patients in the International Paroxysmal Nocturnal Hemoglobinuria Registry. *Haematologica* 2014;99:922-9.
15. Yenerel MN, Muus P, Wilson A, Szer J. Clinical course and disease burden in patients with paroxysmal nocturnal hemoglobinuria by hemolytic status. *Blood Cells Mol Dis* 2017;65:29-34.
16. Almeida AM, Bedrosian C, Cole A, et al. Clinical benefit of eculizumab in patients with no transfusion history in the International Paroxysmal Nocturnal Hemoglobinuria Registry. *Intern Med J* 2017;47:1026-34.
17. Lee JW, Jang JH, Kim JS, et al. Clinical signs and symptoms associated with increased risk for thrombosis in patients with paroxysmal nocturnal hemoglobinuria from a Korean Registry. *Int J Hematol* 2013;97:749-57.
18. Brodsky RA. How I treat paroxysmal nocturnal hemoglobinuria. *Blood* 2009;113:6522-7.
19. Hill A, Rother RP, Arnold L, et al. Eculizumab prevents intravascular hemolysis in patients with paroxysmal nocturnal hemoglobinuria and unmasks low-level extravascular hemolysis occurring through C3 opsonization. *Haematologica* 2010;95:567-73.
20. Emadi A, Brodsky RA. Successful discontinuation of anticoagulation following eculizumab administration in paroxysmal nocturnal hemoglobinuria. *Am J Hematol* 2009;84:699-701.