

Two Patterns of the “Crossed Swords Sign” for the Accurate Diagnosis of Diverse Mitral Valve Regurgitations

Abstract

The “crossed swords sign,” demonstrating the divergent jet, is visualized on 2-dimensional color Doppler imaging and indicates complicated mitral regurgitation (MR). We describe the cases of two patients with varying patterns of the crossed swords sign. In the first patient, the crossed swords sign was detected during the holosystolic phase. In the second patient, the direction of the MR jet changed according to the phase of systole: The crossed swords sign was formed by two regurgitation jets during different phases of systole. The crossed swords sign implies two patterns and is useful for the accurate diagnosis of complex MR.

Keywords: Color Doppler imaging, complicated mitral regurgitation, crossed swords sign

Introduction

Recently, the indications for surgery for complicated MR have expanded, and mitral valve (MV) repair has become the first line of treatment for complicated MV lesions such as bileaflet prolapse. Thus, it is important to accurately diagnose MV lesions with intraoperative transesophageal echocardiography (TEE) and assess the severity of MR. Various protocols have been advocated for the diagnosis of MV lesions using 2-dimensional (2D) imaging.^[1] However, 2D imaging is better suited for the diagnosis of single, less complex lesions compared to 3-dimensional (3D) imaging.^[2] Two-dimensional color Doppler imaging usually demonstrates eccentric regurgitant jets in single leaflet MV lesions and a central regurgitant jet in bileaflet lesions, if there is an equal degree of prolapse in both mitral leaflets. The crossed swords sign is noted when divergent jets are present in complicated MV lesions.^[3-5]

We describe two patients with complicated MV lesions, presenting with the crossed swords sign. In the first patient, the crossed swords sign was detected during holosystole. The MV lesions were due to flail posterior leaflet (P2) and billowing of the anterior leaflet (A3) and posterior leaflet (P3), which could be visualized on 3D imaging. In the second patient, the direction of the

regurgitant jet changed according to the systolic phase; these regurgitation jets, with divergent directions, formed the crossed swords sign. The lesions observed included P2 prolapse and A2 billowing. The A2 lesion could not be demonstrated on the 3D image. The crossed swords sign is useful for diagnosing complicated MV lesions. When the crossed swords sign is observed, it is important to identify the systolic phase, when the regurgitant jet occurs. We obtained written consent from the patients to publish this case report.

Case Reports

Patient 1

A 38-year-old woman was scheduled to undergo robot-assisted MV repair for severe MR. Preoperative transthoracic echocardiography (TTE) revealed a P2 prolapse and an ejection fraction (EF) of 60%. There were no other abnormal findings on preoperative evaluation.

After uneventful induction of general anesthesia, a comprehensive TEE was performed using the CX-50 TEE machine (Philips Medical Systems Andover, MA). Myxomatous changes were noted on 2D imaging in both leaflets, with posterior P2 prolapse and torn chordae. Two-dimensional color Doppler on the midesophageal long-axis (ME-LAX) view showed diverse regurgitant jets, i.e., “the crossed swords sign” during holosystole [Figure 1]. On

**Kazuto Miyata,
Sayaka Shigematsu**

*Department of Anesthesia,
NewHeart Watanabe Institute,
Hamadayama 3-19-11,
Suginami-Ku, Tokyo, Japan*

Submitted: 05-Nov-2019

Accepted: 09-Mar-2020

Published: 19-Oct-2020

Address for correspondence:

*Dr. Kazuto Miyata,
Department of Anesthesia,
NewHeart Watanabe Institute,
Hamadayama 3-19-11,
Suginami-Ku, Tokyo, Japan.
E-mail: kmiyata0410@gmail.
com*

Videos Available on:
www.annals.in

Access this article online

Website: www.annals.in

DOI: 10.4103/aca.ACA_167_19

Quick Response Code:



How to cite this article: Miyata K, Shigematsu S. Two patterns of the “crossed swords sign” for the accurate diagnosis of diverse mitral valve regurgitations. *Ann Card Anaesth* 2020;23:499-501.

This is an open access journal, and articles are distributed under the terms of the Creative Commons Attribution-NonCommercial-ShareAlike 4.0 License, which allows others to remix, tweak, and build upon the work non-commercially, as long as appropriate credit is given and the new creations are licensed under the identical terms.

For reprints contact: reprints@medknow.com

turning the probe clockwise from the ME-LAX view, A3 and P3 billowing with central regurgitant jets were observed. The crossed swords sign was shown to be formed by the eccentric jet due to P2 prolapse and central jet due to A3-P3 billowing. The 3D en-face image showed P2 prolapse with torn chordae and A3-P3 billowing.

We informed the surgical team regarding the complex etiology of the MV lesion. The surgical team, after discussion, decided not to resect the leaflets because of the wide P2 and P3 lesion and the profound indentation between P1-P2 and P2-P3. Hence, NeoChord reconstruction and annuloplasty were planned. NeoChord reconstruction was performed for P2 and P3, and annuloplasty was performed using a 35-mm Tailor Flexible Band (St. Jude Medical Inc., St. Paul, MN, USA). The patient was weaned from cardiopulmonary bypass (CPB) without difficulty. TEE revealed no residual MR jet and there was no systolic anterior motion of anterior mitral leaflet. The remainder of the hospital stay was uneventful.

Patient 2

A 71-year-old man was scheduled for robot-assisted MV repair for the treatment of severe MR. Preoperative TTE revealed P2 prolapse and mild aortic regurgitation with an EF of 63%. No other abnormal findings were observed on preoperative evaluation.

After uneventful induction of general anesthesia, a comprehensive TEE examination was performed using the CX-50 machine (Philips Medical Systems Andover, MA). The 2D image revealed a P2 prolapse. No other MV lesions were noted.

Two-dimensional color Doppler imaging on the ME-LAX view revealed a central jet during early systole and an eccentric jet due to P2 prolapse during mid to late systole. These regurgitant jets formed the crossed swords sign,

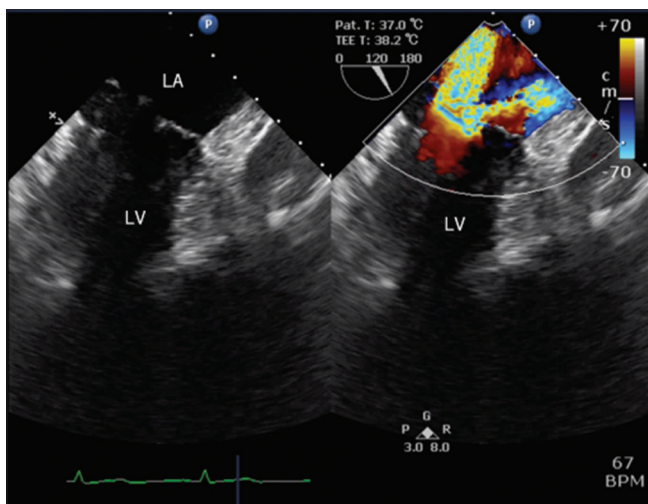


Figure 1: Mid-esophageal long-axis view: Divergent mitral valve regurgitation with the “crossed swords sign.” LV: Left ventricular; LA: Left atrium

suggestive of a bileaflet MV lesion [Figure 2]. The 3D en-face image showed P2 prolapse. No other lesions were visible. The surgical team was informed of the complex anatomical nature of the lesions. Although the A2 lesion was not evident on 2D and 3D imaging, we presumed that it was complicated by A2 lesions, due to the crossed swords sign. The cardiac surgeon decided to perform NeoChord reconstruction with annuloplasty. After P2 NeoChord reconstruction, a water test was performed. The billowing of the A2 segment of the anterior leaflet was apparent [Figure 3]. Thus, NeoChord reconstruction was performed for the A2 segment. Annuloplasty was performed using a 31-mm Tailor Flexible Band (St. Jude Medical Inc., St. Paul, MN, USA). The patient was weaned off CPB without difficulty. A trivial residual MR was observed after weaning from CPB. The remainder of the hospital stay was uneventful.[Video 1 and 2]

Discussion

We describe two patients who presented with the crossed swords sign on 2D color Doppler imaging, which indicates a complicated MV lesion. In the first patient, we observed the crossed swords sign during holosystole. In the second patient, the crossed swords sign was characterized by a change in

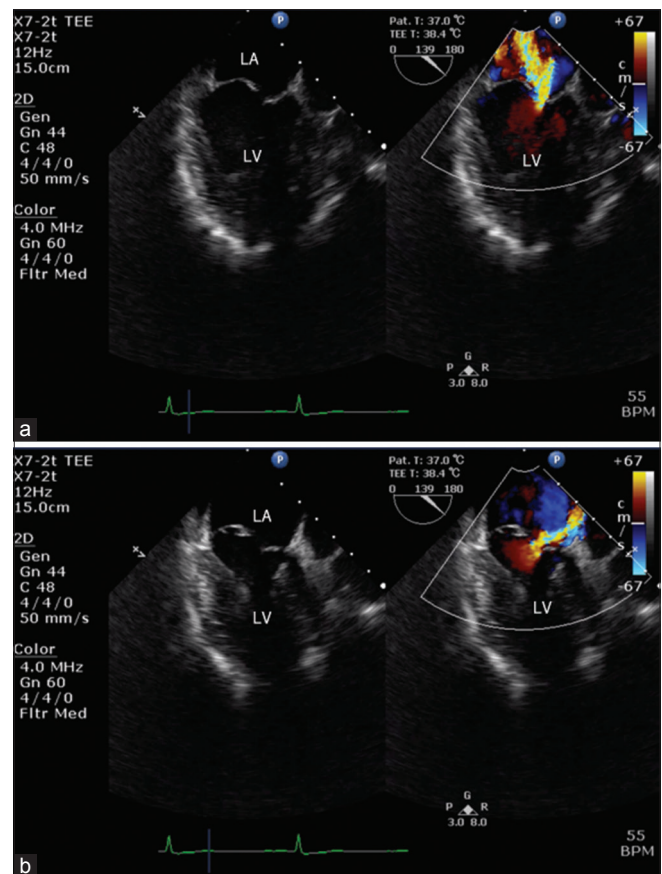


Figure 2: (a) Mid-esophageal long-axis view: A central jet is observed during early systole without any apparent etiology. LV: Left ventricular LA: Left atrium. (b) Mid-esophageal long-axis view: An eccentric jet is observed during mid to late systole due to posterior leaflet (P2) prolapse. LV: Left ventricular LA: Left atrium

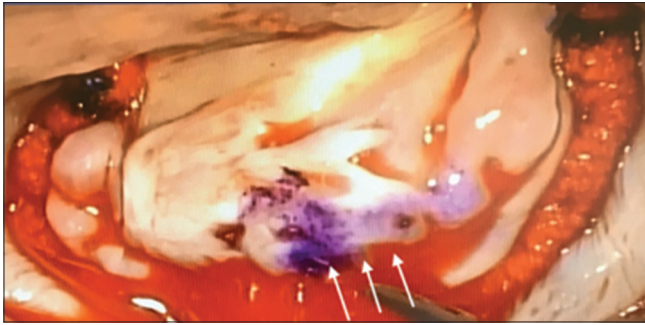


Figure 3: After ring annuloplasty and NeoChord reconstruction of the posterior leaflet (P2), the billowing of the anterior leaflet (A2) is observed on performing the water test (White arrow)

the direction of the regurgitant jet, according to the phase of systole. The A2 lesion could not be diagnosed on 2D and 3D en-face imaging in this patient and the crossed sword sign was the only manifestation that suggested an anterior leaflet lesion.

Divergent regurgitant jets on 2D color Doppler imaging manifest as the crossed swords sign. The presence of two orifices results in a higher volume of regurgitation and increases the severity of MR. Hence, if the crossed swords sign is observed, two regurgitation orifices should be considered. In the first patient, there were two regurgitation orifices due to P2 prolapse and billowing of the A3 and P3 segments. The presence of two holosystolic regurgitation jets resulted in the formation of a crossed swords sign. In the second patient, the direction of 2D color Doppler flow changed depending on the systolic phase, resulting in the formation of the crossed swords sign. There was only one instantaneous regurgitation jet, suggesting the presence of a single regurgitation orifice. Therefore, the lesion was considered to involve the posterior leaflets and opposite anterior leaflets (P2-A2).

The direction of the 2D color Doppler flow is a holosystolic eccentric jet from the site of the lesion to the opposite side, for a single leaflet MV lesion. A central jet is seen during the holosystolic phase, when there is an equal degree of prolapse in both mitral leaflets, in a bileaflet MV lesion.

In the second patient, an opposite MV lesion (A2-P2) was present, and the degree of the prolapse of P2 was greater than the degree of the billowing of A2. Therefore, the 2D color Doppler central jet due to billowing of A2 was observed in the early systolic phase. The eccentric 2D color Doppler jet was directed toward the atrial septum, opposite to the posterior leaflet (P2), when P2 prolapse was most pronounced during mid to late systole.

The incidence of severe MR due to anterior or bileaflet lesions is less than 30%.^[6] However, the incidence of recurrent MR after MV repair is higher for anterior and bileaflet lesions.^[7] Moreover, a history of previous surgery decreases the durability of MV repair.^[7] Accurate diagnosis of the MV lesion with recent advances in diagnostic methods and equipment by TEE and the development of simple and highly reproducible procedures such as

NeoChord reconstruction may contribute to improved durability of MV repair.

We performed robot-assisted MV repair using a complete endoscopic approach, performed through four ports.^[8] All members of the cardiac team can monitor the surgical procedure. Based on TEE findings and water test results, we could discuss and plan additional procedures with the cardiac surgeons. Such interactions may influence the prognosis of repair of complex MV lesions.

In summary, complex MV lesions may present with the crossed swords sign on 2D color Doppler imaging by TEE. The crossed swords sign may be of two types. Two regurgitation orifices are observed when the regurgitation jets are observed during holosystole, and a single regurgitation orifice is observed when the regurgitation jet varies, depending on the phase of systole. In the latter case, the crossed swords sign may be the sole indicator of a MV lesion.

Declaration of patient consent

The authors certify that they have obtained all appropriate patient consent forms. In the form the patient(s) has/have given his/her/their consent for his/her/their images and other clinical information to be reported in the journal. The patients understand that their names and initials will not be published and due efforts will be made to conceal their identity, but anonymity cannot be guaranteed.

Financial support and sponsorship

Nil.

Conflicts of interest

There are no conflicts of interest.

References

1. Sidebotham DA, Allen SJ, Gerber IL, Fayers T. Intraoperative transesophageal echocardiography for surgical repair of mitral regurgitation. *J Am Soc Echocardiogr* 2014;27:345-66.
2. Ben Zekry S, Nagueh SF, Little SH, Quinones MA, McCulloch ML, Karanbir S, *et al.* Comparative accuracy of two- and three-dimensional transthoracic and transesophageal echocardiography in identifying mitral valve pathology in patients undergoing mitral valve repair: Initial observations. *J Am Soc Echocardiogr* 2011;24:1079-85.
3. Beerli R, Streckenbach SC, Isselbacher EM, Akins CW, Vlahakes GJ, Adams MS, *et al.* The crossed swords sign: Insights into the dilemma of repair in bileaflet mitral valve prolapse. *J Am Soc Echocardiogr* 2007;20:698-702.
4. Amador Y, Baribeau Y, Khamooshian A, Hai T, Mahmood F. A case of divergent mitral regurgitation jets. *J Cardiothorac Vasc Anesth* 2017;31:1142-4.
5. Gao Z, Bortman JM, Mahmood F, Matyal R, Khabbaz KR. Crossed swords sign: A 3-dimensional echocardiographic appearance. *A Pract* 2019;12:416-9.
6. Freed LA, Levy D, Levine RA, Matyal R, Khabbaz KR. Prevalence and clinical outcome of mitral-valve prolapse. *N Engl J Med.* 1999;341:1-7.
7. Suri RM, Clavel MA, Schaff HV, Michelena HI, Huebner M, Nishimura RA, *et al.* Effect of recurrent mitral regurgitation following degenerative mitral valve repair: Long-term analysis of competing outcomes. *J Am Coll Cardiol* 2016;67:488-98.
8. Ishikawa N, Watanabe G. Robot-assisted cardiac surgery. *Ann Thorac Cardiovasc Surg* 2015;21:322-8.