

Case Report

## An unusual case of hypothenar hammer syndrome in the non-dominant hand

Natasha J.G. Bauer\* and Simon C. Hardy

Department of Vascular Surgery, Royal Blackburn Hospital, East Lancashire NHS Trust, Blackburn, UK

\*Correspondence address. Department of Vascular Surgery, Royal Blackburn Hospital, East Lancashire NHS Trust, Blackburn BB2 3HH, UK. Tel: +44-7703-804650; E-mail: natasha.bauer@elht.nhs.uk

Received 25 May 2014; accepted 9 June 2014

A 60-year-old male patient was referred to the vascular clinic with a 2-week history of a 1.5 cm pulsatile tender swelling in the left hypothenar eminence. He worked as a gas fitter and sustained this swelling following an injury at work. Interestingly, unlike many cases reported, his left, non-dominant hand was only used passively while his dominant right hand was using the hammer. Duplex ultrasonography confirmed the presence of a true aneurysm of the left ulnar artery, measuring 11 mm in diameter, as it approached the palmar arch. The ulnar nerve was revealed to be ectatic and tortuous and was found to cork-screw in the palm. The aneurysm was removed surgically and histological specimens revealed an intraluminal organizing thrombus. The literature reveals that, in a true aneurysm, it is rare to present with symptoms of this syndrome in the non-dominant, passive hand.

### INTRODUCTION

'Hypothenar Hammer Syndrome' (HHS), a term coined in 1970 [1], was first described by Von Rosen in 1934 [2]. The syndrome is characterized by repeated trauma to the ulnar artery, resulting in intimal damage leading to thrombosis and sometimes, the formation of an aneurysm. Traditionally, HHS is diagnosed in the dominant hand of middle-aged men involved in skilled trades through regular use of tools such as hammers, screwdrivers and electrical drills or habitual use the heel of their dominant hand as a hammer. Three distinct occupational groups have been linked to this syndrome including manual labourers, sportsmen and operators of vibrating tools. Typical symptoms experienced by patients with HHS include digital pain (96%), cold sensitivity (79%), cyanosis (70%), numbness (54%) and paraesthesia (51%) [3]. In this case report, we present a rare case of HHS where the patient presents with symptoms in the non-dominant hand which was used passively when the injury occurred.

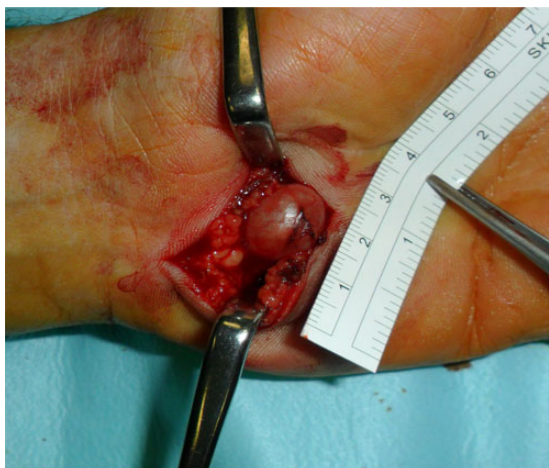### CASE REPORT

A 60-year-old male patient was referred to the vascular clinic with a 2-week history of a pulsatile tender swelling in the left

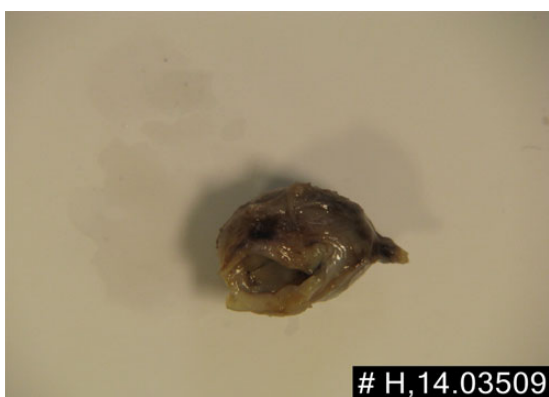
hypothenar eminence following an injury to his left hand. He worked as a gas fitter and was right hand dominant. He was a type 2 diabetic with hypertension and a family history of stroke with no family history of coagulopathies or Raynaud's disease. His regular medication was metformin, insulin and aspirin. This injury was sustained just before Christmas while using his right hand to hammer a pipe according to a specification. His left hand was passively involved in ensuring the pipe was held steady. He regularly used his left hand passively while doing his job. He experienced acute severe pain throughout the hypothenar region and noticed cyanosis of his fourth and fifth digits. Immediately following this, he noticed a sizeable swelling in his right hypothenar eminence.

Examination revealed good radial and ulnar pulses. The left hypothenar eminence was tender and a small expansile mass measuring ~1.5 cm in diameter was palpable. Allen's test was normal in the right hand but on the left, there was no refill of the palmar vasculature on release of the ulnar artery. There were some calluses noted but no digital ulcers or signs of digital ischaemia. Tactile sensation was slightly diminished in the ring and little finger. A cardiovascular examination was unremarkable with a normal blood pressure recorded.

Routine biochemistry was unremarkable. Duplex ultrasonography of the left hand confirmed the presence of a true



**Figure 1:** A curvilinear incision revealed an ulnar aneurysm 1.5 cm in length.



**Figure 2:** Microscopy revealed an organizing thrombus. The intima was focally hyalinised and the media focally thinned, containing scattered neutrophils.

aneurysm of the left ulnar artery, measuring 11 mm in diameter, as it approached the palmar arch. Interestingly, this also revealed an ectatic and tortuous ulnar artery, which corkscrewed in the palm. The radial artery was found to have good volume flow. Computed tomography angiography was not deemed to be necessary.

Intraoperatively, a curvilinear incision was made directly over the swelling, revealing an aneurysm measuring 1.5 cm in length (Fig. 1). The neck of the aneurysm was ligated causing loss of aneurysmal pulsation. The aneurysmal tissue was sent to histology to be further analysed.

Histologic evaluation confirmed an ulnar artery aneurysm measuring 1.3 cm in diameter by 1.5 cm in length. Sections of the aneurysm were examined using microscopy, unveiling an organizing thrombus. The intima was focally hyalinised and the media focally thinned, containing scattered neutrophils (Fig. 2).

This was a day case surgical procedure; the patient was discharged 3 h post-operatively. The stitches were removed 14 days later and he was found to be asymptomatic without any complications.

## DISCUSSION

The pathogenesis of this syndrome relates closely to its anatomy. Guyon's canal is triangular in shape, usually measures 4 cm in length and is located at the base of the ulnar side of the palm [4]. The ulnar nerve and artery pass through Guyon's canal before entering the hand. It is bordered laterally by the hook of the hamate and the transverse carpal ligament. Repetitive blunt trauma sustained to the ulnar aspect of the palm through frequent use of tools or habitual use of the heel of the hand as a hammer causes intimal damage of the ulnar artery within Guyon's canal, resulting in thrombosis of the ulnar artery, leading to aneurysm formation. In this case, our patient was diagnosed with occupational HHS due to frequent use of tools through his job as a gas fitter.

Analysis of the literature reveals that ulnar artery thrombosis in the non-dominant hand is in fact a rarity. Multiple studies have looked at HHS affecting the dominant hand [5–7]. In a study conducted by Ferris *et al.* [8], a high proportion of subjects who reported unilateral symptoms were found to have multiple digital artery occlusions bilaterally, concluding that HHS developed as a result of pre-existing palmar ulnar artery fibrodysplasia. This was refuted by Larsen *et al.* [3] who, after a review of 67 cases, concluded that FMD does not contribute to HHS in most patients. In our opinion, HHS is a complex syndrome that arises due to a combination of genetic and environmental factors.

In our patient, pathognomonic features of HHS were found on duplex ultrasonography such as a 'corkscrew' appearance of the ulnar artery indicating a tortuous course and evidence of an aneurysm.

HHS can be treated conservatively, medically and surgically, depending on the severity, onset and duration of symptoms. Conservative management involves lifestyle changes similar to that of sufferers of Raynaud's disease. Medical interventions include calcium-channel blockers, antiplatelets or anticoagulation. Surgical options include ligation of the ulnar artery, resection of the aneurysm with end-to-end anastomosis or resection and vascular reconstruction using a graft [9]. In our case, we decided to ligate and not anastomose the artery due to the nature of the patients' job and the fact that he had good radial artery flow. On follow-up, the patient is doing well, reporting no recurrence of symptoms in his non-dominant hand.

## REFERENCES

1. Conn J, Bergan JJ, Bell JL. Hypothenar hammer syndrome: post traumatic digital ischaemia. *Surgery* 1970; **68**: 1122–8.
2. Von Rosen S. Ein fall von thrombose in der arteria ulnarix nach einwirkung von stumpfer gewalt. *Acta Chir Scand* 1934; **73**: 500–6.
3. Larsen BT, Edwards WD, Jensen MH, Johnson CH, McBane RD, Harmsen WS, *et al.* Surgical pathology of hypothenar hammer syndrome with new pathogenetic insights: a 25-year institutional experience with clinical and pathologic review of 67 cases. *Am J Surg Pathol* 2013; **37**: 1700–8.

4. Wiesel SW. *Operative Techniques in Orthopaedic Surgery*, vol. III. Washington: Lippincott Williams & Wilkins, 2010,2671–6.
5. Vayssairat M, Debure C, Cormier JM, Bruneval P, Laurian C, Juillet Y. Hypothenar hammer syndrome: seventeen cases with long-term follow-up. *J Vasc Surg* 1987;**5**:838–43.
6. Cooke RA. Hypothenar hammer syndrome: a discrete syndrome to be distinguished from hand-arm vibration syndrome. *Occup Med* 2003;**53**:320–4.
7. Drape JL, Feydy A, Guerini H, Desmarais E, Godefroy D, Le Viet D, *et al.* Vascular lesions of the hand. *Eur J Radiol* 2005;**56**:331–43.
8. Ferris BL, Taylor LM, Oyama K, McLafferty RB, Edwards JM, Moneta GL, *et al.* Hypothenar hammer syndrome: proposed etiology. *J Vasc Surg* 2000;**31**:104–11.
9. Ablett CT, Hackett LA. Hypothenar hammer syndrome: case reports and brief review. *Clin Med Res* 2008;**6**:3–8.