

# Lateral Patellofemoral Ligament Reconstruction With Semitendinosus Allograft in the Setting of Previous Lateral Release



Benjamin Kerzner, B.S., Mario Hevesi, M.D., Ph.D., Luc M. Fortier, B.A.,  
Monique S. Haynes, M.D., M.P.H., Safa Gursoy, M.D., Ph.D., Suhas P. Dasari, M.D.,  
Zeeshan A. Khan, B.A., Adam B. Yanke, M.D., Ph.D., and Jorge Chahla, M.D., Ph.D.

**Abstract:** The lateral patellofemoral ligament acts to resist medial displacement of the patella. When medial subluxation occurs, it usually has an iatrogenic cause such as prior lateral release, an over-tightened medial patellofemoral ligament reconstruction, or detachment of the vastus lateralis from the patella. The justification for lateral retinacular release has historically been to address extensor mechanism issues such as imbalance of the mechanism due to increased retinacular tension. We present a Technical Note on the treatment of chronic medial patellar instability due to a previous lateral retinacular release using a soft-tissue reconstruction approach with a semitendinosus allograft.

Medial instability of the patella is an uncommon occurrence, especially when compared with lateral patellar dislocation.<sup>1</sup> Most medial instability occurs as a result of iatrogenic causes, such as lateral retinacular release or tibial tubercle osteotomy.<sup>2</sup> In 1962, Kaplan<sup>3</sup> first identified the lateral patellofemoral

ligament (LPFL) as the “epicondylopatellar ligament” and described it as residing anatomically in the deep transverse retinaculum.<sup>2</sup> Subsequently, Vieira et al.<sup>4</sup> described the LPFL’s biomechanical role in resisting medial displacement of the patella as it connected the lateral femoral condyle to the lateral aspect of the patella.

The justification for lateral retinacular release has historically been to address extensor mechanism issues such as imbalance of the mechanism due to increased retinacular tension.<sup>5</sup> This imbalance has been reported to lead to anterior knee pain, instability, and patellofemoral arthritis.<sup>5</sup> Although isolated release was historically relatively commonly performed, it has fallen out of favor over the years. A survey of 27 members of the International Patellofemoral Study Group in 2004 conducted by Fithian et al.<sup>6</sup> revealed that there was no consensus about the indication for lateral retinacular release and that it should not be performed in isolation.<sup>5</sup> A study by Panni et al.<sup>7</sup> examining the results of 100 patients treated between 1986 and 1994 showed that patient satisfaction dropped from 72% to 50% among those with patellofemoral instability who underwent lateral retinacular release.<sup>5</sup> They hypothesized that there were other factors contributing to the patients’ instability that were not adequately addressed by isolated lateral release.<sup>5,7</sup> Similarly, Lattermann et al.<sup>8</sup> found a decrease in satisfaction rates among patients who underwent lateral release for patellofemoral instability.<sup>5</sup> They concluded that isolated lateral release has little benefit and should be used only in conjunction

From Midwest Orthopaedics at Rush, Chicago, Illinois, U.S.A. (B.K., M.H., L.M.F., M.S.H., S.G., S.P.D., Z.A.K., A.B.Y., J.C.); and the Department of Orthopaedic Surgery, Rush University Medical Center, Chicago, Illinois, U.S.A. (A.B.Y., J.C.).

The authors report the following potential conflicts of interest or sources of funding: A.B.Y. is a paid consultant for AlloSource, outside the submitted work; is a paid consultant for AlloSource, ConMed Linvatec, JRF Ortho, and Olympus; is an unpaid consultant for Patient IQ, Smith & Nephew, and Sparta Biomedical; receives research support from Arthrex, Organogenesis, and Vericel; and owns stock or stock options in Patient IQ. J.C. is a paid consultant for Arthrex, ConMed Linvatec, Ossur, and Smith & Nephew and is a board member of or has committee appointments with American Orthopaedic Society for Sports Medicine, AANA, and International Society of Arthroscopy, Knee Surgery & Orthopaedic Sports Medicine. Full ICMJE author disclosure forms are available for this article online, as [supplementary material](#).

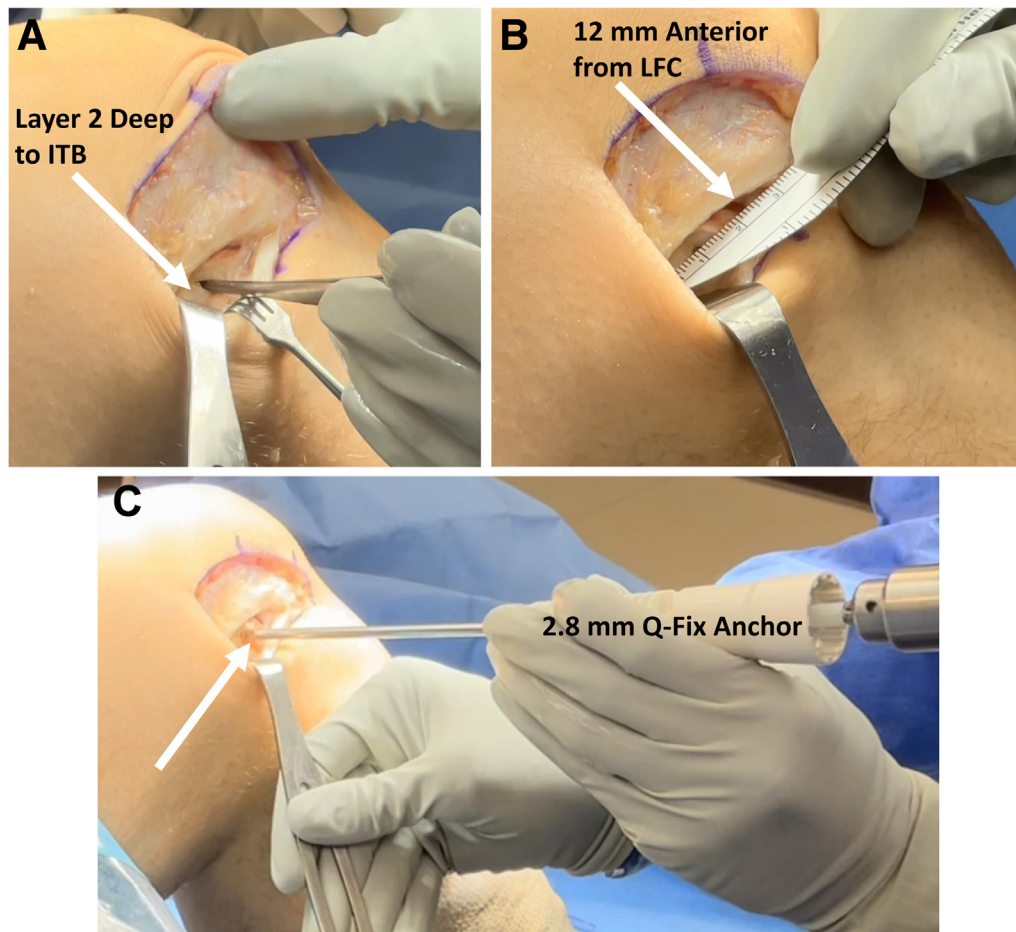
Received December 31, 2021; accepted February 8, 2022.

Address correspondence to Jorge Chahla, M.D., Ph.D., Department of Orthopaedic Surgery, Rush University Medical Center, 1611 W Harrison St, Ste 300, Chicago, IL 60612, U.S.A. E-mail: [Jorge.Chahla@rushortho.com](mailto:Jorge.Chahla@rushortho.com)

© 2022 THE AUTHORS. Published by Elsevier Inc. on behalf of the Arthroscopy Association of North America. This is an open access article under the CC BY-NC-ND license (<http://creativecommons.org/licenses/by-nc-nd/4.0/>).

2212-6287/223

<https://doi.org/10.1016/j.eats.2022.02.016>



**Fig 1.** Intraoperative dissection in lateral right knee. (A) Superficial soft-tissue flaps are created, and sharp dissection is carried down through a laterally based window just anterior to the palpable lateral epicondyle in the right knee. (B) The anatomic attachment of the lateral patellofemoral ligament (LPFL), which averages 12 mm anterior to the lateral epicondyle of the right knee and 14 mm posterior to the anterior cartilage, can be directly visualized in reference to the articular margin and is measured prior to placement of the anchor. (C) The LPFL femoral footprint in the right knee is cleared of soft tissue, and a 2.8-mm all-suture anchor (Q-FIX) is placed at the femoral LPFL attachment. (ITB, iliotibial band; LFC, lateral femoral condyle.).

with other procedures such as extensor mechanism realignment.<sup>5,8</sup> In addition to being used for patellofemoral instability and patellofemoral arthritis, lateral retinacular release is sometimes performed at the time of total knee arthroplasty (TKA).<sup>5</sup> This may be performed to resist lateral translation or subluxation of the patella and is more commonly used in knees with valgus deformity.<sup>5</sup> Although lateral release is sometimes used in the setting of TKA, the biomechanics of the patellofemoral joint in TKA are different from those of the native patellofemoral joint.<sup>9</sup>

When medial patellar instability occurs, it usually has iatrogenic causes such as prior lateral release, an overtightened medial patellofemoral ligament (MPFL) reconstruction, or detachment of the vastus lateralis from the patella.<sup>10</sup> Most techniques to remedy medial subluxation do so by addressing lateral patella stabilizing structures.<sup>10</sup> These techniques include lateral repair and imbrication, which notably require sufficient tissue quantity and quality to create a robust side-to-side advancement and repair.<sup>10,11</sup> Because of concerns that the imbrication may stretch out over time and that repair requires adequate tissue coverage and quality, several repair techniques have been unsuccessful.

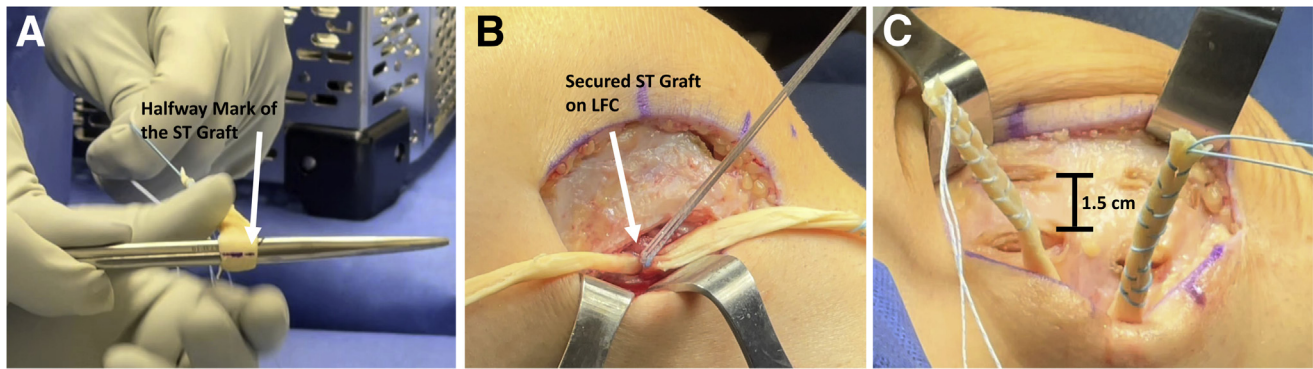
When there is not sufficient-quality tissue, lateral reconstruction may be considered. Several reconstruction techniques with different graft sources have been described, including quadriceps and gracilis grafts.<sup>12-14</sup> Saper and Shneider<sup>13</sup> detailed their reconstruction technique using a quadriceps tendon graft and suggested that an advantage of this approach is a decreased theoretical risk of patellar fracture owing to avoidance of patellar anchors, screws, and bone tunnels. Saper<sup>12</sup> also described LPFL reconstruction using a gracilis allograft with soft tissue–based fixation on the patellar side and reported promising outcomes.

In this article, we present a Technical Note on the treatment of chronic medial patellar instability due to a previous lateral retinacular release using an anatomically based soft-tissue reconstruction approach with commonly available semitendinosus allograft ([Video 1](#)).

## Technique

### Preoperative Planning and Surgical Decision Making

Patients should undergo a comprehensive history and physical examination, with special attention paid to



**Fig 2.** Semitendinosus (ST) allograft preparation and securement for onlay fixation in right knee. (A) ST allograft (AlloSource) measuring 22 cm is prepared using a No. 2 high FiberLoop to whipstitch the last 3 cm of each end; the graft is folded in half and the midpoint marked. (B) The marked midpoint of the graft is sutured to the femoral footprint using the sutures attached to the previously placed 2.8-mm all-suture anchor. (C) Two sets of parallel, longitudinal incisions are made, with the medial set of incisions abutting the lateral patellar margin at the native lateral patellofemoral ligament insertion and the lateral set of incisions located approximately 1.5 cm lateral to each medial incision. (LFC, lateral femoral condyle.).

past knee surgical procedures, as well as patellofemoral tracking. Patients with a history of lateral retinacular release and resultant medial instability in particular may benefit from isolated LPFL reconstruction, whereas patients presenting without past knee trauma or surgery in the setting of chronic medial-based instability should prompt a workup for underlying biomechanical factors such as maltracking, dysplasia, and coronal deformity, which may likely need to be addressed at the time of LPFL reconstruction. Additionally, patients presenting with substantial painful patellar crepitus and radiographic arthritis should prompt a discussion of age-appropriate restoration or joint reconstruction procedures.

Our preferred preoperative imaging includes anteroposterior and flexed posteroanterior (Rosenberg or skier's) views of the knee, a perfect lateral weight-bearing view at 30° of flexion, and a sunrise or Merchant view. Additionally, all patients should undergo magnetic resonance imaging to evaluate for underlying chondral and ligamentous pathology as well as (lateral) retinacular defects. For patients in whom osseous malalignment is suspected, consideration should be given to standing hip-to-ankle radiographs and rotational ("gunsight") computed tomography to determine femoral version and tibial torsion.

### Diagnostic Arthroscopy

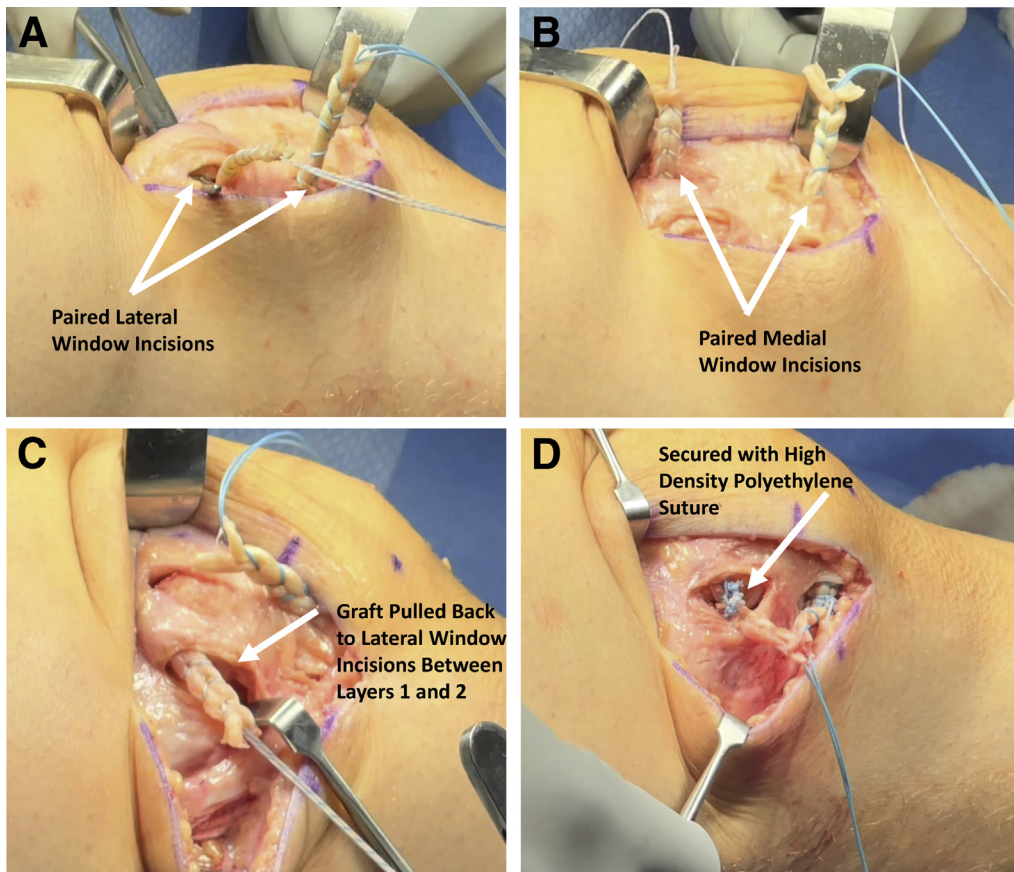
The patient is placed supine on the operating table, and the lower extremity is prepared and draped in the standard fashion. The extremity is exsanguinated, and the tourniquet is inflated to 250 mm Hg. We begin with an arthroscopic examination of the knee including the patellofemoral joint, medial gutter, and lateral gutter, as well as both the medial and lateral joint spaces. Any visible loose bodies are removed. Osteochondral fractures associated with patellar instability may be

identified and treated with debridement or refixation at this juncture. Subsequently, attention is turned to reconstruction of the LPFL.

### Lateral Dissection and Anchor Placement

A 4-cm incision is made just lateral to the lateral-most aspect of the patella, extending longitudinally from just distal to the superior pole of the patella down to the inferior pole of the patella. Superficial soft-tissue flaps are created, and subsequently, sharp dissection is carried down through a laterally based window just anterior to the palpable lateral epicondyle (Fig 1A). Dissection of this laterally based window is carried through the iliotibial band (layer 1), thus arriving at layer 2, which contains the LPFL and the lateral patellar retinaculum. Dissection is continued posteriorly, and the capsule is then identified (layer 3). The anatomic attachment of the LPFL, which averages 12 mm anterior to the lateral epicondyle and 14 mm posterior to the anterior cartilage, can be directly visualized in reference to the articular margin using this approach (Fig 1B).<sup>15</sup> Any remnant tissue from the torn LPFL can be helpful here to further delineate and verify the appropriate anatomic location given inherent patient-to-patient variation in LPFL anatomy. The LPFL femoral footprint is cleared of soft tissue, and a 2.8-mm all-suture anchor (Q-FIX; Smith & Nephew, Watford, England) is placed at the femoral LPFL attachment (Fig 1C).

Subsequently, attention is turned toward the patellar insertion of the LPFL. Two sets of parallel, longitudinal incisions are made in layer 1, with the medial set of incisions abutting the lateral patellar margin at the native LPFL insertion and the lateral set of incisions located approximately 1.5 cm lateral to each medial incision (Fig 2C). Two planes are created deep to layer 1 to allow graft passage around the patellar retinaculum



**Fig 3.** Semitendinosus graft passage for lateral patellofemoral ligament reconstruction in right knee. (A) The graft is passed first into the lateral window of each paired incision. (B) The graft is passed to the medial-window group of incisions after passing through the lateral-window incisions. (C) The graft is looped around the patellar retinaculum by passing it back laterally, through the more superficial of the 2 planes, moving from the medial window to the lateral window. (D) Once the desired tension has been achieved, the semitendinosus allograft is reinforced using the high-density polyethylene sutures in each tail of the graft with the use of a free needle.

located in layer 2, in a manner superficial to the underlying capsule and deep to the iliotibial band.

### Graft Preparation

Our preferred graft is a semitendinosus allograft (AlloSource, Centennial, CO). This is prepared on the back table by a method analogous to MPFL reconstruction. We prepare a 22-cm portion of hamstring allograft, using a No. 2 high FiberLoop (Arthrex, Naples, FL) to whipstitch the last 3 cm of each end of the graft. Subsequently, the graft is folded in half and the midpoint marked (Fig 2A).

### Graft Passage

The marked midpoint of the graft is sutured to the femoral footprint using the sutures attached to the previously placed 2.8-mm all-suture anchor (Fig 2B). Subsequently, each limb of the graft is passed medially along the deeper of the 2 planes created, in an extracapsular fashion. The graft is passed first into the lateral window of each paired incision (Fig 3A) and then to the medial window (Fig 3B). Subsequently, the graft is looped around the patellar retinaculum by passing it back laterally, through the more superficial of the 2 planes, moving from the medial window to the lateral window (Fig 3C). Each limb is tensioned in full

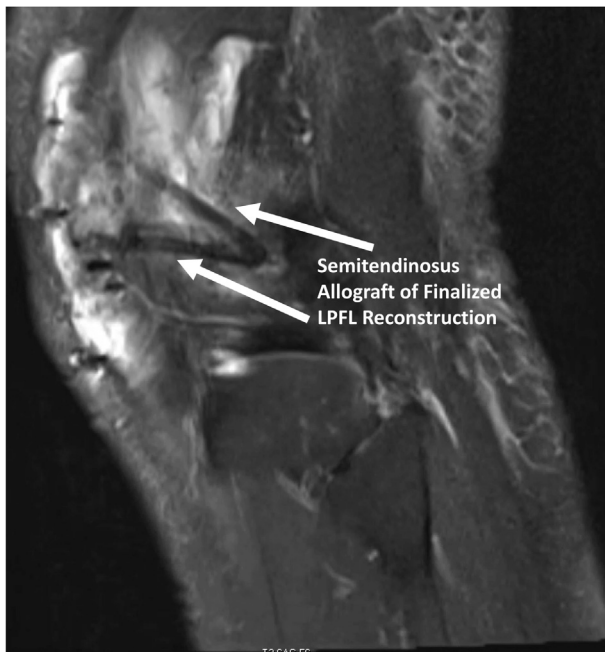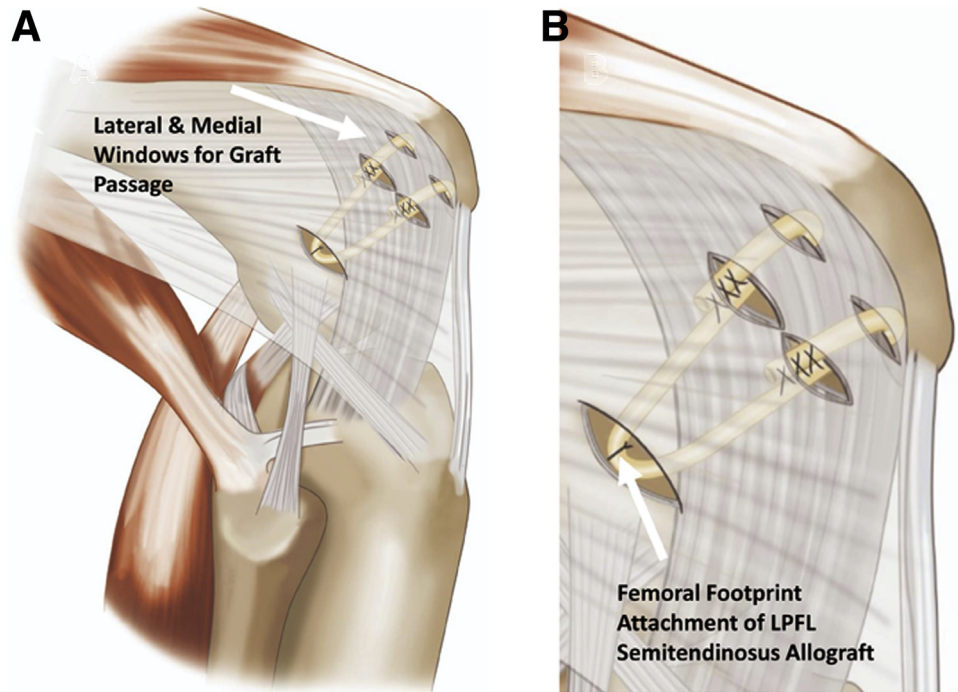
extension, allowing for 1.5 to 2 quadrants of medial patellar excursion, and graft fixation is achieved by suturing the graft tail to the graft itself with a No. 1 Vicryl suture (Ethicon, Somerville, NJ). At this point, proper anisometry is tested and adjustments are made accordingly. Once the desired tension has been achieved, with the patella smoothly transitioning into the trochlear groove at between 0° and 30° of flexion, this is reinforced using the high-density polyethylene sutures in each tail of the graft with the use of a free needle (Fig 3D). The femoral and soft-tissue attachments of the finalized graft in position are illustrated in Figure 4.

Subsequently, the knee is cycled, LPFL reconstruction stability is checked, and layer 1 is closed using No. 1 Vicryl suture. The knee is closed in layers in standard fashion. Postoperative magnetic resonance imaging of the finalized graft trajectory is shown in Figure 5.

### Rehabilitation

In the first 2 weeks postoperatively, patients are allowed weight bearing as tolerated with the brace locked at 0°. Range of motion is limited to 0° to 30° with an emphasis on full extension. From weeks 2 to 4, range of motion is progressed to 0° to 60° with the

**Fig 4.** Finalized lateral patellofemoral ligament (LPFL) graft in place in right knee. (A) Dissection of a laterally based window is carried through the iliotibial band (layer 1) and arrives at layer 2, which contains the LPFL and the lateral patellar retinaculum. Dissection is continued posteriorly, and the capsule is then identified (layer 3). Each limb of the graft is passed medially along the deeper of the 2 planes created, in an extracapsular fashion. The graft is passed first into the lateral window of each paired incision and then to the medial window. The graft is looped around the patellar retinaculum by passing it back laterally, through the more superficial of the 2 planes, moving from the medial window to the lateral window. (B) Once the desired tension has been achieved, the graft is reinforced using the high-density polyethylene sutures in each tail of the graft with the use of a free needle.



**Fig 5.** Postoperative magnetic resonance imaging of finalized lateral patellofemoral ligament (LPFL) graft in right knee. A sagittal T2 magnetic resonance imaging cut of the finalized semitendinosus graft is shown, with 2 strands extending anteromedially from the 2.8-mm all-suture anchor (Q-FIX) origin on the distal femur. The anatomic femoral attachment of the LPFL averages 12 mm anterior to the lateral epicondyle and 14 mm posterior to the anterior cartilage.

addition of quadriceps sets for strengthening, and further range of motion from 0° to 90° is allowed during weeks 4 to 6. During weeks 6 to 14 postoperatively, the use of the brace is discontinued and the patient is weaned from using crutches. A progressive squat program with leg presses, lunges, and agility exercises is slowly introduced in a stepwise fashion. A plyometric program and forward running can be initiated at 14 to 22 weeks postoperatively when an 8-inch step down is satisfactory. At 22 weeks, the patient is coached on an advanced plyometric program with return to sport as directed by the treating surgeon.

## Discussion

The deep lateral retinaculum of the knee joint is composed of 3 distinct structures, namely the iliotibial band, the lateral patellotibial ligament, and the LPFL.<sup>16</sup> Merican et al.<sup>16</sup> dissected 8 cadaveric knees and described the LPFL more specifically as essentially a distinct band of thickening of the joint capsule. Huddleston et al.<sup>15</sup> performed a quantitative cadaveric study evaluating the LPFL attachment sites and found that the center, anterior, and posterior aspects of the LPFL were, on average,  $17.0 \pm 1.4$  mm,  $11.8 \pm 2.0$  mm, and  $8.0 \pm 1.9$  mm, respectively, from the lateral epicondyle. The LPFL plays an important role in patellofemoral joint stability and acts in conjunction with the

**Table 1.** Pearls and Pitfalls

Pearls	
Diagnostic arthroscopy should be performed prior to the rest of the procedure to ensure that no other intra-articular pathology exists, such as cartilage lesions and meniscal tears.	
It is important to use a temporary stitch when assessing tension of the semitendinosus graft because it is easy to re-tension the graft if there is too much medial translation of the patella intraoperatively.	
The graft should be secured between layers 1 and 2 on the lateral side of the knee.	
Pitfalls	
Failure to place lateral distal femur anchor at anatomic origin site for appropriate reconstruction	
Over-tensioning graft and thus impacting patellar tracking in groove and knee flexion	

quadriceps muscle forces, the articular geometry of the patella and femur, the other retinacular structures, and the direction of the patellar tendon to prevent medial subluxation of the patella.<sup>17</sup> A biomechanical study by Merican et al.<sup>16</sup> found that the LPFL is a strong and stiff structure with its fibers oriented to resist patellar medial displacement. Their study showed a significant reduction in patellar medial stability from 0° to 20° of knee flexion after a lateral release. Ostermeier et al.<sup>18</sup> reported that a lateral retinacular release resulted in medial tilt and translation of the patella. As such, iatrogenic medial patellar instability is a well-documented complication associated with release of the lateral retinaculum.<sup>11,19-21</sup>

LPFL reconstruction has been established to be a successful procedure for medial dislocation of the patella after a failed lateral retinacular release.<sup>2,12,13</sup> Conversely, direct repair or imbrication of the lateral retinaculum has been reported to result in recurrence of medial excursion after the first postoperative year.<sup>14</sup> Despite iatrogenic patellar instability being a well-known phenomenon, large prospective studies looking at outcomes after LPFL reconstruction are lacking. Nonetheless, a variety of different surgical techniques to reconstruct the LPFL have been reported in the literature, including the use of autograft and allograft.<sup>12-14,22</sup> Beckert et al.<sup>23</sup> retrospectively reviewed 17 patients (19 knees) who underwent LPFL reconstruction performed by a single surgeon using a semitendinosus allograft secured to the femur with an EndoButton device (Smith & Nephew)—type device and sutured directly to the patella using a FiberWire (Arthrex). At an average follow-up of 2 years, they found no reported cases of residual postoperative symptoms of patellar instability, medial patellar apprehension, or examiner-induced subluxation. All patients showed normal range of motion compared with the contralateral limb. There was also a significant postoperative improvement in the Knee Injury and Osteoarthritis Outcome Score (KOOS), from a mean score of 34.39 preoperatively to 69.54 postoperatively. Our technique provides similar

anatomic reconstruction of the LPFL but avoids the need for direct osseous suturing, thus facilitating workflow as well as potentially decreasing intraoperative or postoperative fracture risk from intraosseous suture passing.

The remainder of studies documenting LPFL reconstruction are largely limited to technique notes and case reports. Saper<sup>12</sup> described a minimally invasive technique using a double-bundle gracilis allograft tendon in a cadaveric knee, involving creation of a femoral tunnel and fixation with an interference screw. Teitge and Torga Spak<sup>14</sup> described an autologous technique involving harvesting of quadriceps tendon autograft with a patellar bone block. The graft is sutured to the patella through a transosseous drill hole and secured to the femoral condyle with a lag screw. Another minimally invasive technique to reconstruct the LPFL was described by Borbas et al.<sup>22</sup> in a patient with symptomatic medial patellar subluxation resulting from a TKA and extended lateral release. They used a double-bundle gracilis tendon autograft looped through the patella and secured to the femur with an interference screw. At 1 year of follow-up, the patient was pain free while the patella was stable and showed correct tracking through range of motion on physical examination.

Our described technique uses a double-bundle semitendinosus allograft for an anatomic soft-tissue reconstruction of the LPFL. We believe this technique offers several important advantages over previously published techniques: By using a suture anchor in the lateral femoral condyle, the graft is secured in its anatomic insertion on the femur to restore native biomechanics. Moreover, by avoiding anchor placement on the patella and securing the graft between 2 separate layers of the lateral retinaculum, the theoretical risk of iatrogenic patellar fracture is reduced. The costs associated with this procedure are also reduced by using only 1 suture anchor. Additionally, this technique is minimally

**Table 2.** Advantages and Limitations

Advantages	
There is a lower risk of fracture because no anchor placement is needed on the lateral side of the patella.	
The surgical method is less expensive owing to the use of fewer materials, given that only 1 anchor in total is required.	
The technique is less invasive to surrounding tissue because the direct patellar attachments are not disrupted.	
Limitations	
The technique requires access and advanced planning for allograft use.	
Not addressing concomitant cartilage issues may result in progressive pain and dysfunction of the knee.	
Intraoperative examination of the patella after LPFL reconstruction may not perfectly replicate patellar tracking in the perioperative period and may result in either a loose or overstrained patellar mechanism.	

LPFL, lateral patellofemoral ligament.

invasive to the surrounding soft-tissue structures because the direct patellar attachments are not disrupted. An important step involves the use of a temporary stitch when evaluating tension of the graft throughout range of motion, which allows the tension to be adjusted if needed. This eliminates the risk of over-tensioning the graft, which can lead to patellar maltracking within the groove during knee flexion (Tables 1 and 2). Moreover, the use of semitendinosus allograft in our practice has had the added benefit of being familiar to sports surgeons and their surgical teams in the patellofemoral setting in particular, given the common use of this graft for MPFL reconstruction.

We recognize that the described technique is not without limitations. Surgeons must have access to allografts in their surgical setting, and advanced planning is required to use allograft tissue. Furthermore, not addressing concomitant cartilage deformities due to chronic medial patellar instability may result in early and progressive osteoarthritis of the knee joint. Finally, intraoperative examination of the patella after LPFL reconstruction may not perfectly replicate patellar tracking in the perioperative period and may result in either a loose or overstrained patellar mechanism.

## References

- Chahla J, Kunze KN, Fulkerson JP, Yanke A. Lateral patellofemoral ligament reconstruction: Anatomy, biomechanics, indications and surgical techniques. *Oper Tech Sports Med* 2019;27: 150689.
- Shah KN, DeFroda SF, Ware JK, Koruprolu SC, Owens BD. Lateral patellofemoral ligament: An anatomic study. *Orthop J Sports Med* 2017;5: 2325967117741439.
- Kaplan EB. Some aspects of functional anatomy of the human knee joint. *Clin Orthop* 1962;23:18-29.
- Vieira EL, Vieira EA, da Silva RT, Berlfein PA, Abdalla RJ, Cohen M. An anatomic study of the iliotibial tract. *Arthroscopy* 2007;23:269-274.
- Fonseca L, Kawatake EH, Pochini AC. Lateral patellar retinacular release: Changes over the last ten years. *Rev Bras Ortop* 2017;52:442-449.
- Fithian DC, Paxton EW, Post WR, Panni AS; International Patellofemoral Study Group. Lateral retinacular release: A survey of the International Patellofemoral Study Group. *Arthroscopy* 2004;20:463-468.
- Panni AS, Tartarone M, Patricola A, Paxton EW, Fithian DC. Long-term results of lateral retinacular release. *Arthroscopy* 2005;21:526-531.
- Lattermann C, Toth J, Bach BR Jr. The role of lateral retinacular release in the treatment of patellar instability. *Sports Med Arthrosc Rev* 2007;15:57-60.
- Tanikawa H, Tada M, Harato K, Okuma K, Nagura T. Influence of total knee arthroplasty on patellar kinematics and patellofemoral pressure. *J Arthroplasty* 2017;32: 280-285.
- McCarthy MA, Bollier MJ. Medial patella subluxation: Diagnosis and treatment. *Iowa Orthop J* 2015;35:26-33.
- Hughston JC, Flandry F, Brinker MR, Terry GC, Mills JC III. Surgical correction of medial subluxation of the patella. *Am J Sports Med* 1996;24:486-491.
- Saper M. Lateral patellofemoral ligament reconstruction with a gracilis allograft. *Arthrosc Tech* 2018;7:e405-e410.
- Saper MG, Shneider DA. Lateral patellofemoral ligament reconstruction using a quadriceps tendon graft. *Arthrosc Tech* 2014;3:e445-e448.
- Teitge RA, Torga Spak R. Lateral patellofemoral ligament reconstruction. *Arthroscopy* 2004;20:998-1002.
- Huddleston H, Haunschild E, Naveen N, et al. The anatomy and length changes of the lateral patellofemoral ligament and lateral patellotibial ligament. *Orthop J Sports Med* 2020;8:2325967120S00452 (suppl 6).
- Merican AM, Sanghavi S, Iranpour F, Amis AA. The structural properties of the lateral retinaculum and capsular complex of the knee. *J Biomech* 2009;42: 2323-2329.
- Christoforakis J, Bull AM, Strachan RK, Shymkiw R, Senavongse W, Amis AA. Effects of lateral retinacular release on the lateral stability of the patella. *Knee Surg Sports Traumatol Arthrosc* 2006;14:273-277.
- Ostermeier S, Holst M, Hurschler C, Windhagen H, Stukenborg-Colsman C. Dynamic measurement of patellofemoral kinematics and contact pressure after lateral retinacular release: An in vitro study. *Knee Surg Sports Traumatol Arthrosc* 2007;15:547-554.
- Hughston JC, Deese M. Medial subluxation of the patella as a complication of lateral retinacular release. *Am J Sports Med* 1988;16:383-388.
- Miller PR, Klein RM, Teitge RA. Medial dislocation of the patella. *Skeletal Radiol* 1991;20:429-431.
- Nonweiler DE, DeLee JC. The diagnosis and treatment of medial subluxation of the patella after lateral retinacular release. *Am J Sports Med* 1994;22:680-686.
- Borbas P, Koch PP, Fucentese SF. Lateral patellofemoral ligament reconstruction using a free gracilis autograft. *Orthopedics* 2014;37:e665-e668.
- Beckert M, Crebs D, Nieto M, Gao Y, Albright J. Lateral patellofemoral ligament reconstruction to restore functional capacity in patients previously undergoing lateral retinacular release. *World J Clin Cases* 2016;4:202-206.