

# Neuroradiological findings of an adolescent with early treated phenylketonuria: is phenylalanine restriction enough?

Mayara Thays Beckhauser,<sup>1</sup>  
Mirella Maccarini Peruchi,<sup>2</sup>  
Gizele Rozone de Luca,<sup>1</sup>  
Katia Lin,<sup>3</sup> Sofia Esteves,<sup>4</sup>  
Laura Vilarinho,<sup>4</sup> Jaime Lin<sup>1</sup>

<sup>1</sup>Department of Biology, Medicine and Social Sciences, Universidade do Sul de Santa Catarina (UNISUL); <sup>2</sup>Department of Radiology, Hospital São João Batista; <sup>3</sup>Neurology Division, Department of Internal Medicine, Universidade Federal de Santa Catarina (UFSC), Santa Catarina, Brazil; <sup>4</sup>Medical Genetics Center, National Health Institute (INSA), Porto, Portugal

## Abstract

Phenylketonuria is caused by mutations in the enzyme phenylalanine hydroxylase gene, that can result in abnormal concentrations of phenylalanine on blood, resulting in metabolites that can cause brain damage. The treatment is based on dietary restriction of phenylalanine, and noncompliance with treatment may result in damage of the brain function. Brain abnormalities can be seen on magnetic resonance imaging of these individuals. Studies indicate that the appearance of abnormalities in white matter reflects high levels of phenylalanine on the blood. This case will show the clinical and neuroradiological aspects of a teenager with constant control of phenylalanine levels. Despite the continuous monitoring and early treatment, the magnetic resonance imaging identified impressive abnormalities in the white matter. This leads us to one question: is the restriction of phenylalanine sufficient to prevent changes in the white matter in patients with phenylketonuria?

## Introduction

Phenylketonuria (PKU) is an inborn error of metabolism, characterized by mutations of the phenylalanine hydroxylase (PAH) gene. Loss of PAH activity results in increased concentrations of Phenylalanine (Phe) in the blood and toxic concentrations in the brain.<sup>1</sup>

PKU is the most frequent inborn error of

amino acid metabolism with a prevalence that varies widely around the world. In Latin America, its prevalence varies between one case per 50.000 and one per 25.000 with a higher prevalence in Southern Latin America.<sup>2</sup>

When left untreated, PKU is the most common cause of mental retardation, with patients presenting progressive intellectual impairment, accompanied by a constellation of additional symptoms, which can include eczematous rash, autism, seizures, and motor deficits. Developmental disturbances, aberrant behavior, and psychiatric symptoms often become apparent as the child grows.<sup>3</sup>

However, since the widespread introduction of newborn screening and dietary Phe restriction, the outcome of this disorder has dramatically changed.<sup>4</sup> An early diagnosis and prompt intervention with its dietary restriction, which remains the mainstay of PKU management, allows most individuals to avoid severe mental disability.<sup>1</sup>

During infancy, adherence to the diet is straightforward because the parents take control of their nutritional intake.<sup>5</sup> As the children grow older, their adherence to treatment becomes increasingly difficult because meals have to be planned rigorously and the children cannot choose the food routinely consumed by their peers.

Consequently, compliance with the diet is often poor, especially when the patients reach adolescence.<sup>1</sup>

Due to those inconsistencies, little is known about clinical aspects and outcomes of early treated adolescents with PKU. Non-adherence to treatment and persistent exposure to high levels of Phe among these older patients, result in impairments of brain function characterized by deficits in executive functioning,<sup>6</sup> processing speed<sup>7</sup> and fine motor control.<sup>8</sup>

Herein we present the clinical and neuroradiological aspects of an adolescent patient, who despite all difficulties, followed successfully a lifelong restrictive dietotherapy for PKU

## Case Report

A 19-year-old young girl born to non-consanguineous parents, with an uneventful gestational history, who was born at term by normal delivery, was diagnosed with PKU on routine neonatal screening test and started dietotherapy at the age of 20-days-old. The diagnosis was confirmed through molecular analysis of the patient as well as the parents. Genetic analysis showed that she is compound heterozygous for the following mutations: p.L249F and p.R261Q. The father carries the first mutation and the mother the second. She maintained constant control of Phe levels with its dosage every 15 days on the first two years of

Correspondence: Dr. Jaime Lin – Department of Biology, Medicine and Social Sciences, Universidade do Sul de Santa Catarina (UNISUL). Av. José Acácio Moreira, Dehon. Tubarão, Santa Catarina, Brazil. Zip code: 88704-900. E-mail: linjaime@yahoo.com

Key words: phenylketonuria, adolescent, demyelination, white matter, phenylalanine.

Contributions: MTB, JL, first manuscript writing; MTB, JL, KL, GRdL, clinical data collecting and analyzing, manuscript writing, revising and final approving; MMP, neuroradiological data collecting, neuroimaging description preparing, manuscript revising and final approving; SE, LV, genetical analysis data collecting and describing, manuscript revising and final approving.

Conflict of interest: the authors report no conflicts of interest.

Received for publication: 4 April 2011.

Accepted for publication: 15 April 2011.

This work is licensed under a Creative Commons Attribution 3.0 License (by-nc 3.0).

©Copyright M.T. Beckhauser et al., 2011  
Licensee PAGEPress, Italy  
*Clinics and Practice* 2011; 1:e25  
doi:10.4081/cp.2011.e25

life, followed by Phe restriction with routine measurements in accordance to clinical guidelines. Her laboratory levels of Phe were kept under 2-6 mg/dL since 20 days-of-age. At present, the patient is a college undergraduate student, with normal educational achievements. A neuropsychological evaluation was performed with results compatible to her age and schooling. Upon neurological examination, she presents a slightly brisk patellar reflex, without any other pyramidal signs or other abnormalities. Magnetic resonance imaging (MRI) of the brain shows bilateral and symmetrical signs of demyelination (Figure 1).

The hospital's Ethic Commission approved this case report and the parents gave informed consent for publication.

## Discussion

PKU is one of the most important examples of successful treatment of an inborn error of metabolism. Since the adoption of widespread newborn screening, allowing an early diagnosis and the institution of the dietary treatment, the quality of life and the prognosis of the patients with PKU has dramatically changed.<sup>4,9</sup>

Although promising, long term management of PKU is not an easy task. Many adolescents and adults are unable to fully adhere to the Phe

restricted diet for the long term. As many as 75% of teenagers and probably an even greater fraction of adults have blood Phe levels above the desired range.<sup>10</sup> Many of these patients exhibit increasing non-compliance over time, eventually leading them to abandon treatment altogether.<sup>4</sup>

Despite all these difficulties, our patient succeeded in maintaining a lifelong dietary treatment for PKU, with complete adherence over the years. Unfortunately, even for this small fraction of individuals, there is a growing body of evidence that they are not doing so well.

From the neuroradiological point of view, in spite of frequently normal MRI findings among well treated PKU patients, conventional MRI revealed morphological abnormalities within their cerebral white matter, predominantly in the peritrigonal region, but less frequently also in the anterior and posterior periventricular regions with involvement of the subcortical white matter.<sup>11</sup>

Additionally, the prevalence of these white matter abnormalities tends to be higher and more severe among older patients, those who are off-treatment and those with high-Phe levels.<sup>12</sup>

The adequate compliance to treatment and the Phe levels is thought to be of fundamental importance to the occurrence of these white matter abnormalities. According to Cleary *et al.*, abnormalities of the white matter in PKU treated patients are more common on those who have discontinued the low-Phe diet during adolescence, with improvement among those who have resumed their treatment, indicating that the white matter appearance reflects the elevated blood Phe levels.<sup>13</sup>

Even in patients who underwent early and continuous treatment for PKU, as in ours, MRI has identified abnormalities in the white matter. Her white matter abnormalities were most-

ly found in regions adjacent to the lateral ventricles with diffusivity restriction on diffusion tensor imaging (DTI) sequence. MRI studies among early treated show typical abnormalities in regions adjacent to the lateral ventricles, as well as in the parieto-occipital white matter and genu of the corpus callosum.<sup>14</sup>

In the past, the importance of these abnormalities was understated due to the lack of association with clinical outcomes. More recently, however, researches have revealed relationships between white matter abnormalities, clinical outcomes and cognition.

According to Brumm *et al.* in spite of early dietary treatment and normal IQ, adults with PKU show deficits in cognitive functioning. Those deficits include a performance well below expectation on verbal learning and memory tasks, as well as other areas of cognitive weakness such as visual memory, expressive naming and selective executive skills.<sup>3</sup>

Using DTI, White *et al.* identified an age-related decrement in the microstructural integrity of the anterior white matter of the corpus callosum in children with early-and continuously-treated PKU.<sup>15</sup> They demonstrated a mean diffusivity abnormality within anterior regions of the corpus callosum that became increasingly pronounced with age. This restriction was hypothesized to be the result of the accumulation of intracellular debris produced as a byproduct of inadequate Phe metabolism.<sup>15</sup> This, in turn, could lead to the cognitive symptoms, since white matter permits interactions among brain regions that sub serve various cognitive abilities.<sup>15</sup>

Further research is needed to determine whether white matter hyperintensities, and compromises in their microstructural integrity are interrelated to PKU and whether these abnormalities might be related to other factors such as the physiological mechanisms underlying dopamine deficiency.<sup>15</sup>

It is important to note that, to date, investigations regarding the biochemical markers associated with executive function (EF) impairment among children with early and continuously treated PKU remain largely Phe-only focused, with little attention paid to other substances of the Phe pathway such as tyrosine (Tyr).

Disturbances arising from the biochemistry point-of-view associated with PKU are thought to primarily affect the dopaminergic systems in the brain due to the disruption of the metabolism of Phe to Tyr, a precursor of dopamine. A high Phe: Tyr ratio is hypothesized to lead to a reduction in dopamine synthesis within the brain, which may better explain EF deficits among children with PKU than Phe levels alone.<sup>16</sup> This may be the reason why individuals with early and continuously treated PKU continue to show high levels of EF impairment.

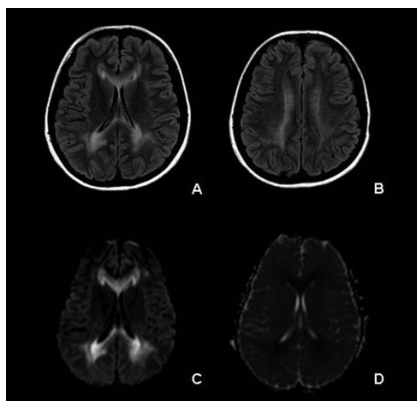
Our patient was under strict control of Phe

levels over her entire life, but only a single dosage of Tyr was performed during her childhood. This data could establish new managing and monitoring practices with continuous Tyr monitoring along with not only Phe restriction but also Tyr reposition to PKU patients.

We reported on a case of an adolescent girl with successful early and continuous treatment for PKU, who despite her efforts presents striking white matter abnormalities. We also reviewed current literature in order to explain these abnormalities, which finally pose the question: is phenylalanine restriction solely enough?

## References

1. Blau N, van Spronsen FJ, Levy HL. Phenylketouria. *Lancet* 2010;376:1417-27.
2. Borrajo GJ. Newborn screening in Latin America at the beginning of the 21st century. *J Inherit Metab Dis* 2007;30:466-81.
3. Brumm VL, Azen C, Moats RA, et al. Neuropsychological outcome of subjects participating in the PKU adult collaborative study: a preliminary review. *J Inherit Metab Dis* 2004;27:549-66.
4. Burton BK, Leviton L. Reaching out to the lost generation of adults with early-treated phenylketonuria (PKU). *Mol Genet Metab* 2010;101:146-8.
5. Blau N, Bélanger-Quintana A, Demirkol M, et al. Management of phenylketonuria in Europe: survey results from 19 countries. *Mol Genet Metab* 2010;99:109-15.
6. Christ SE, Huijbregts SC, de Sonnevill LM, White DA. Executive functions in early-treated phenylketonuria: profile and underlying mechanisms. *Mol Genet Metab* 2010;99 Suppl 1:S22-32.
7. Moyle JJ, Fox AM, Arthur M, et al. Meta-analysis of neuropsychological symptoms of adolescents and adults with PKU. *Neuropsychol Rev* 2007;17:91-101.
8. Pietz J, Dunkelmann R, Rupp A, et al. Neurological outcome in adult patients with early-treated phenylketonuria. *Eur J Pediatr* 1998;157:824-30.
9. Leuzzi V, Pansini M, Sechi E, et al. Executive function impairment in early-treated PKU subjects with normal mental development. *J Inherit Metab Dis* 2004;27:115-25.
10. Walter JH, White FJ, Hall SK, et al. How practical are recommendations for dietary control in phenylketonuria? *Lancet*. 2002;360:55-7.
11. Bick U, Fahrendorf G, Ludolph AC, et al. Disturbed myelination in patients with treated hyperphenylalaninaemia: evaluation with magnetic resonance imaging. *Eur J Pediatr* 1991;150:185-9.



**Figure 1.** Axial FLAIR MRI images (A and B) show symmetrical hyperintensity in the periventricular white matter, internal capsules and corpus callosum. The diffusion tensor imaging (C) shows signs of restriction, confirmed in the apparent diffusion coefficient map (D).

12. Anderson PJ, Leuzzi V. White matter pathology in phenylketonuria. *Mol Genet Metab* 2010;99 Suppl 1:S3-9.
13. Cleary MA, Walter JH, Wraith JE, et al. Magnetic resonance imaging in phenylketonuria: reversal of cerebral white matter change. *J Pediatr* 1995;127:251-5.
14. Ding XQ, Fiebler J, Kohlschütter B, et al. MRI abnormalities in normal-appearing brain tissue of treated adult PKU patients. *J Magn Reson Imaging* 2008;27:998-1004.
15. White DA, Connor LT, Nardos B, et al. Age-related decline in the microstructural integrity of white matter in children with early- and continuously-treated PKU: A DTI study of the corpus callosum. *Mol Genet Metab* 2010;99 Suppl1:S41-6.
16. Sharman R, Sullivan KA, Young RM, McGill JJ. Tyrosine monitoring in children with early and continuously treated phenylketonuria: results of an international practice survey. *J Inherit Metab Dis* 2010 [Epub ahead of print]