

Received: 2020.10.19

Accepted: 2021.03.11

Available online: 2021.05.27

Published: 2021.07.06

Primary Extranodal Follicular T-Cell Lymphoma and Ductal Breast Carcinoma Diagnosed by a Magnetic Resonance Imaging-Guided Vacuum-Assisted Biopsy: A Case Report

Authors' Contribution:

Study Design A
Data Collection B
Statistical Analysis C
Data Interpretation D
Manuscript Preparation E
Literature Search F
Funds Collection G

ABDEF 1,2

ABDE 1

ABDF 1

BD 3

ABE 1

AEF 1

BD 4

ABDEF 2

Rosaria Meucci**Chiara Adriana Pistolese****Tommaso Perretta****Maria Laura Luciani****Emanuela Beninati****Federica Di Tosto****Valeria D'Alfonso****Oreste Claudio Buonomo**

1 UOC of Diagnostic Imaging, Policlinico Tor Vergata (PTV) University, Rome, Italy

2 UOSD Breast Unit, Department of Surgical Science, Policlinico Tor Vergata (PTV) University, Rome, Italy

3 UOC Mammography Screening, St. Eugenio Hospital, Rome, Italy

4 Department of Surgical Pathology, St. Eugenio Hospital, Rome, Italy

Corresponding Author:Emanuela Beninati, e-mail: emanuela.beninati@gmail.com**Conflict of interest:**

None declared

Patient: Female, 62-year-old
Final Diagnosis: Primary non-Hodgkin lymphoma and ductal carcinoma in-situ
Symptoms: No specific symptoms
Medication: —
Clinical Procedure: —
Specialty: Radiology

Objective: Rare co-existence of disease or pathology
Background: Extranodal non-Hodgkin's lymphomas (NHLs) are most commonly low-grade B-cell lymphomas, and the breast is not an usual site for this condition. This case report describes a 62-year-old woman with a primary NHL and ductal carcinoma in situ (DCIS) of the left breast diagnosed by a magnetic resonance imaging (MRI)-guided vacuum-assisted breast biopsy. The simultaneous diagnosis of breast cancer and NHL is rare, with few cases described in the literature. Primary breast lymphomas account only for 0.04% to 0.5% of breast malignancies.
Case Report: In November 2016, a 62-year-old woman was treated for a peripheral T-cell lymphoma (follicular helper T-cell phenotype) of the left upper central breast; later she underwent periodic breast imaging follow-ups. In October 2018, MRI revealed a focal 33-mm non-mass contrast enhancement (according to the Breast Imaging Reporting and Data System –MRI lexicon of the American College of Radiology) in the lower external quadrant of the left breast. Neither mammography nor ultrasonography demonstrated any suspicious features. The multidisciplinary medical team performed an MRI-guided vacuum-assisted breast biopsy and the histological analysis confirmed the diagnosis of a DCIS. Subsequently, she underwent surgery resulting in eradication of the disease and has had regular follow-ups, including mammography, ultrasonography, and MRI.
Conclusions: This is a rare case of both a primary NHL of the breast and DCIS, which was detected only by MRI. It highlights the role of an MRI-guided vacuum-assisted breast biopsy, which allows an accurate and economic diagnosis in case of suspicious findings on MRI. We recommend the use of MRI in follow-ups for patients with previous breast lymphomas (high-risk patients).

Keywords: Breast Neoplasms • Image-Guided Biopsy • Lymphoma, Non-Hodgkin • Magnetic Resonance Imaging

Full-text PDF: <https://www.amjcaserep.com/abstract/index/idArt/929309>



1146



4



26



Background

The simultaneous presentation of breast cancer and a malignant lymphoma is rare [1-3]. The majority of cases are patients who exhibit breast cancer as a secondary malignancy, subsequent to the treatment of the Hodgkin lymphomas [3]. The simultaneous presentation of an extranodal non-Hodgkin lymphoma (NHL) and a primary breast lymphoma is rare; very few cases have been reported in the literature [4-11]. Primary breast lymphomas account for only 0.04% to 0.5% of breast malignancies. B-cell primary breast lymphomas are the most common, whereas T-cell lymphomas are rare and represent <15% of all NHLs [12]. This is a case report of a primary NHL and ductal carcinoma in situ (DCIS) of the left breast, diagnosed by a magnetic resonance imaging (MRI)-guided vacuum-assisted

breast biopsy in a 62-year-old woman. An MRI-guided vacuum-assisted breast biopsy [13-15] is a safe and accurate, minimally invasive technique that allows the characterization of suspicious lesions that are detectable only by MRI and should be used instead of more invasive and expensive surgical biopsies.

Case Report

In November 2016, a 62-year-old woman had an MRI of the breast, which identified a 13-mm homogenous mass enhancement in the left upper central breast. She underwent a local needle biopsy and then a bone marrow biopsy. A histological examination of the biopsy showed connective fibrous tissue infiltrated by a proliferation of small atypical lymphocytes with a diffuse

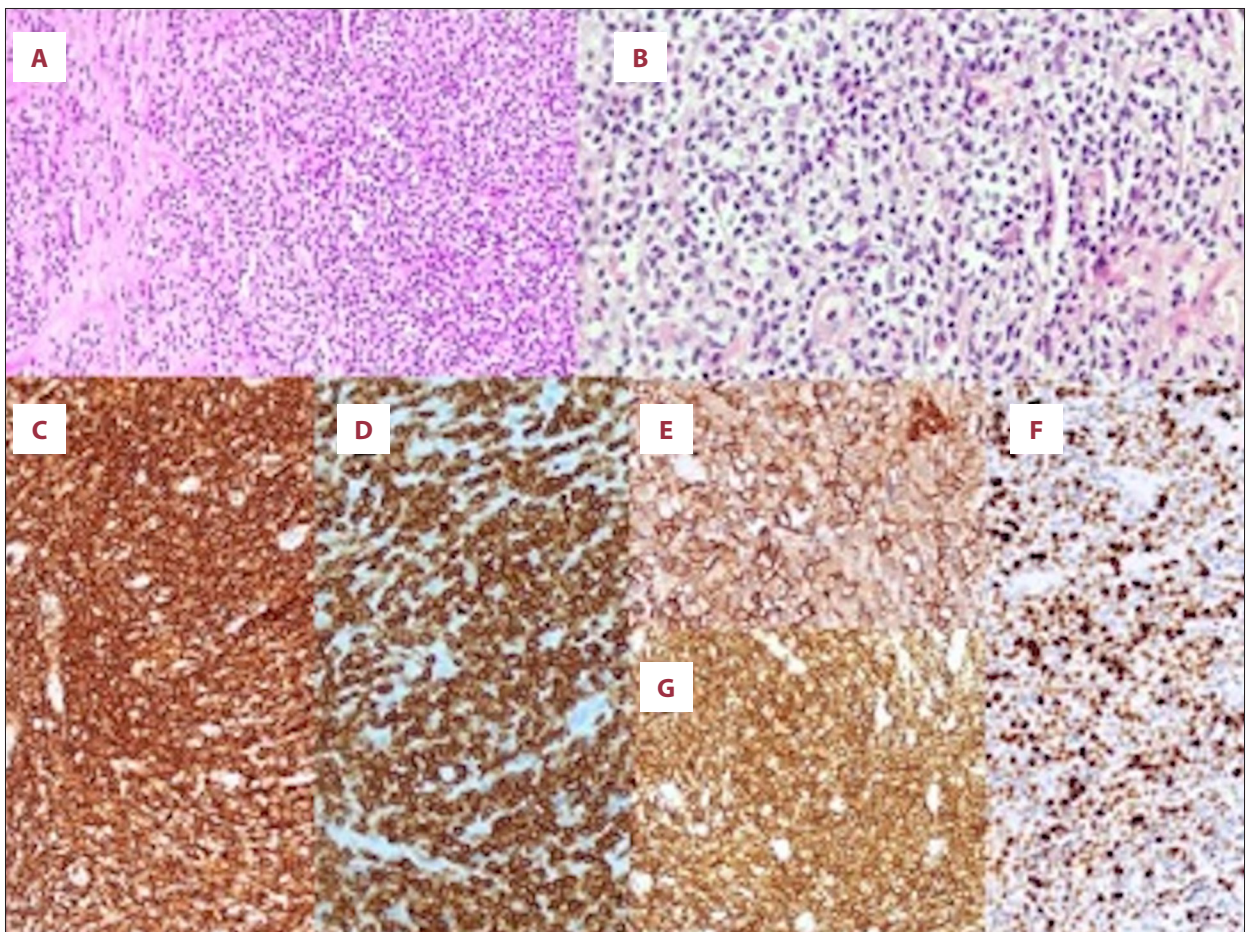


Figure 1. Histological photomicrographs for the peripheral follicular helper T-cell phenotype (breast): (A) A population of small atypical lymphocytes with a diffuse growth pattern, admixed eosinophils are present (hematoxylin and eosin stain, low magnification $\times 20$) (B) The lymphocytes showed clear cytoplasm and dark nuclei with irregular profiles and small nucleoli. Eosinophils are also evident (hematoxylin and eosin stain, high magnification $\times 40$). (C) Immunohistochemical stains showed a T-cell phenotype: CD5 (magnification $\times 10$). (D) Immunohistochemical stains showed a T-cell phenotype: CD3 (magnification $\times 20$). (E) Helper T-cell markers were present in the T-cell population as revealed by strong PD1 (magnification $\times 10$). (F) Immunohistochemical stains showed a T-cell phenotype: CD4 (magnification $\times 4$). (G) Proliferation index Ki67 60% to 70% (magnification $\times 10$).

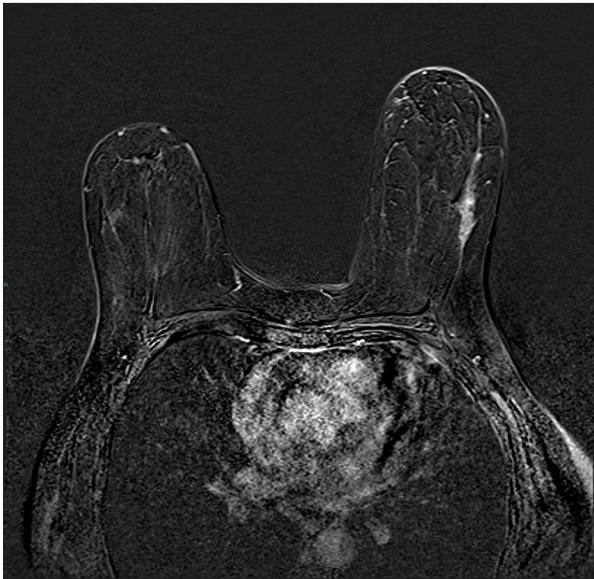

Figure 2. Appearance of the ductal carcinoma in situ on magnetic resonance imaging (MRI). The axial digital subtraction dynamic (MRI) sequence after an intravenous gadolinium injection showed a 33-mm non-mass contrast enhancement characterized by a regional enhancement distribution in the lower external quadrant of the left breast.

growth pattern, admixed with small eosinophils (Figure 1A). The lymphocytes had dark nuclei with irregular nuclear membranes, small nucleoli, and clear cytoplasm (Figure 1B). A T-cell phenotype was revealed by immunohistochemical stains. The

antigens CD5+ (Figure 1C), CD3+ (Figure 1D), CD43+, CD4+, PD1+, BCL6-/, CD10-, CXCL13-, CD8-, TIA1-, granzyme B-, perforin-, CD56-, CD57-, and CD30 were expressed by a subset of tumor cells, and the transcription factors ALFCD246-, PAX5-, and EBV encoded-mRNA were not present. These findings were in agreement with the diagnosis of a peripheral T-cell lymphoma according to the WHO 2017 classification of hematopoietic and lymphoid tissues. In this setting, the expression of markers, including PD1, CD4, and BCL6 suggested a follicular helper T-cell phenotype (Figure 1E, 1F). The proliferation index Ki67 was 60% to 70% (Figure 1G). She was started on 6 cycles of chemotherapy (CHOEP: cyclophosphamide, hydroxydaunorubicin, vincristine, etoposide, prednisolone) followed by 21 radiotherapy sessions localized to the left breast lesion. Then she underwent an autologous stem-cell transplant. Subsequently, in January 2018 and June 2018, she underwent positron emission tomography/computed tomography with 18(F)-fluorodeoxyglucose; both these examinations showed no significant uptake of the radiotracer in the left breast or in the nearby lymph nodes. Therefore, we diagnosed a radiological remission of the original lymphoma. Breast imaging follow-ups did not reveal any further lesions. In October 2018, the breast MRI showed a non-mass contrast enhancement (according to the Breast Imaging Reporting and Data System MRI lexicon of the American College of Radiology [BIRADS-MRI lexicon]) [16] measuring 33 mm (maximum transverse diameter), which was characterized by regional enhancement distributed in the lower external quadrant of the left breast (Figure 2). Neither mammography (MMG) nor ultrasonography (US) revealed any suspicious findings. The multidisciplinary medical

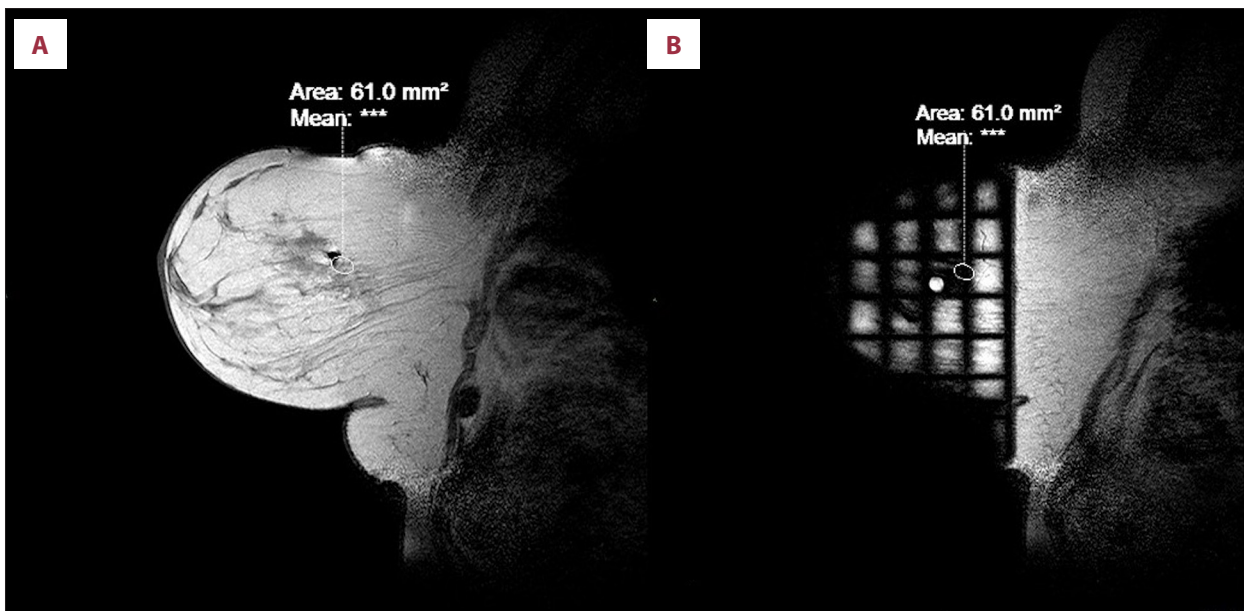


Figure 3. Preliminary steps of the magnetic resonance imaging-guided vacuum-assisted breast biopsy: (A) coordinates for needle placement based on the spatial relationship between the lesion, fiducial marker (solid white circle) and grid lines (B) considering slice thickness.

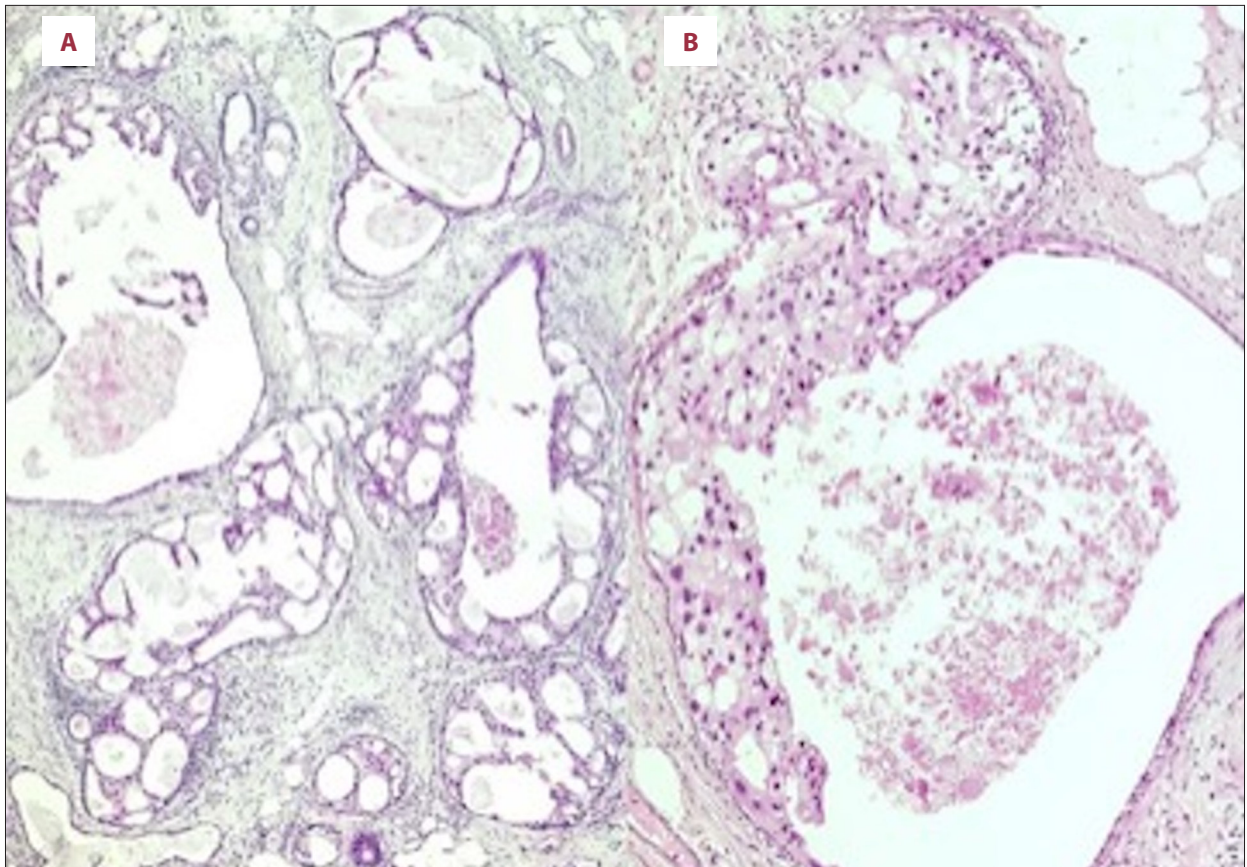


Figure 4. Histological photomicrographs of the ductal carcinoma in situ. (A) A cluster of ducts with atypical ductal hyperplasia and low-grade ductal carcinoma in situ with a micropapillary and cribriform growth pattern (hematoxylin and eosin stain, low magnification $\times 4$). (B) Ducts of the low-grade ductal carcinoma in situ, with apocrine differentiation and central comedonecrosis (hematoxylin and eosin stain, high magnification $\times 20$).

team decided to perform an MRI-guided vacuum-assisted breast biopsy in order to characterize the lesion (Figure 3A, 3B). It was performed with a free-hand approach by a radiologist with 10 years of experience in performing breast interventions using a 1.5 T MRI system (Philips Intera Achieva, Best, the Netherlands) equipped with a dedicated surface coil (Open Breast Array Coil, Invivo, Phillips, Amsterdam, the Netherlands). He employed an 8-gauge vacuum-assisted breast biopsy (VABB) device (Mammotome, Roma, Italy) with lateral access. The Mammotome MRI-dedicated VABB system consists of a control module that keeps the vacuum constant between 23 mm/Hg and 25 mm/Hg, which is the range used for stereotactic and US guidance. The MRI-guided biopsy was performed in 30 min. At the end of the procedure, the operator released an MRI-compatible titanium clip (Mammotome, Roma, Italy). He collected 12 histological specimens. The histological examination revealed a DCIS (B5a). After 2 weeks, she underwent a lower external quadrantectomy of the left breast on a 25-mm lesion occupied by atypical ductal hyperplasia (Figure 4A) and low-grade DCIS (G3) of the cribriform and micropapillary type with comedonecrosis and focal apocrine differentiation

(Figure 4B). The tumor was completely eradicated and she was discharged in good general condition.

Discussion

This case report describes the simultaneous extranodal localization of a peripheral T-cell lymphoma (follicular helper T-cell phenotype) and DCIS in the breast; this is rarely reported in the literature [7]. There is evidence supporting a possible pathophysiological connection between the peripheral T-cell lymphomas with follicular helper T-cell phenotypes and DCIS involving a common genetic background, etiologic factors, and the possibility that 1 disease causes the other [17]. A breast lymphoma can change the features of concomitant breast cancer by altering the axillary lymphatic vessels, which aid breast cancer dissemination [5] or through altering the lymph node microenvironment [4]. A higher risk for a second breast cancer was present in our patient due to the radiation therapy and chemotherapy administered as treatment. Patients with lymphomas have shown a rising trend of chronic immune depression,

which predisposes them to develop a second cancer. After the treatment of her lymphoma, the multidisciplinary team decided to follow up by combining MMG, US, and MRI. This approach was chosen for her specific risk factors (primary breast lymphomas, chemotherapy, and radiation therapy). As MRI was used, this follow-up allowed early identification of the metachronous lesions that would otherwise be unrecognized with other imaging methods. Compared to conventional imaging, MRI has a higher sensitivity that makes it possible to detect 20% more malignant lesions than MMG and US alone [18,19]. In our patient, the MMG and US examinations did not show any abnormal findings. It is rare that breast cancer and lymphoma are not identifiable by MMG and US. For a suspicious MRI-only lesion, an MRI-guided biopsy is recommended by the American Cancer Society and European Society of Breast Imaging [20,21]. In our case, the MRI-guided vacuum-assisted breast biopsy gave an early histological diagnosis of the suspicious lesions, although there were no corresponding features on MMG or US [22]. We used an MRI-guided vacuum-assisted breast biopsy protocol that collects a larger amount of tissue by collecting more specimens [23], as this avoids any procedural failures (ie, false negatives due to sub-sampling). The reported technical success rate of the free-hand MRI-guided vacuum-assisted breast biopsies with manual approaches is about 95% [23-26].

Conclusions

This report presented a rare case of primary NHL of the breast and DCIS, which was detected only by MRI. An MRI-guided vacuum-assisted breast biopsy provides an accurate and economic diagnosis in case of suspicious findings on MRI. We recommend that MRI should be used for the follow-up of patients with a history of breast lymphomas (high-risk patients).

Department and Institution Where Work Was Done

UOC of Diagnostic Imaging, Policlinico Tor Vergata University, Rome, Italy

Conflicts of Interest

None.

References:

1. Haberer S, Belin L, Le Scodan R, et al. Locoregional treatment for breast carcinoma after Hodgkin's lymphoma: The breast conservation option. *Int J Radiat Oncol Biol Phys.* 2012;82(2):e145-52
2. Cutuli B, Kanoun S, Tunon De Lara C, et al. Breast cancer occurred after Hodgkin's disease: Clinic-pathological features, treatments and outcome: analysis of 214 cases. *Crit Rev Oncol Hematol.* 2012;81(1):29-37
3. Elkin EB, Klem ML, Gonzales AM, et al. Characteristics and outcomes of breast cancer in women with and without a history of radiation for Hodgkin's lymphoma: A multi-institutional, matched cohort study. *J Clin Oncol.* 2011;29(18):2466-73
4. Barranger E, Marpeau O, Uzan S, Antoine M. Axillary sentinel node involvement by breast cancer coexisting with B-cell follicular lymphoma in non-sentinel nodes. *Breast J.* 2005;11(3):227-28
5. Cox J, Lunt L, Webb L. Synchronous presentation of breast carcinoma and lymphoma in the axillary nodes. *Breast.* 2006;15(2):246-52
6. Cuff KE, Dettrick AJ, Chern B. Synchronous breast cancer and lymphoma: A case series and a review of the literature. *J Clin Pathol.* 2010;63(6):555-57
7. Laudenschlager MD, Tyler KL, Geis MC, et al. A rare case of synchronous invasive ductal carcinoma of the breast and follicular lymphoma. *S D Med.* 2010;63(4):123-25
8. Tamaoki M, Nio Y, Tsuboi K, et al. A rare case of non-invasive ductal carcinoma of the breast coexisting with follicular lymphoma: A case report with a review of the literature. *Oncol Lett.* 2014;7(4):1001-6
9. Michalinos A, Vassilakopoulos T, Levidou G, et al. Multifocal bilateral breast cancer and breast follicular lymphoma: A simple coincidence? *J Breast Cancer.* 2015;18(3):296-300
10. Arana S, Vasquez-Del-Aguila J, Espinosa M, et al. Lymphatic mapping could not be impaired in the presence of breast carcinoma and coexisting small lymphocytic lymphoma. *Am J Case Rep.* 2013;14:322-25
11. Benoit L, Arnould L, Collin F, et al. Concurrent lymphoma and metastatic breast carcinoma in the axillary, confounding sentinel lymph-node biopsy. *Eur J Surg Oncol.* 2004;30(4):462-63
12. Muroya D, Toh U, Iwakuma N, et al. Primary breast peripheral T-cell lymphoma not otherwise specified: Report of a case. *Surg Today.* 2015;45(1):115-20
13. Liberman L, Bracero N, Morris E, et al. MRI-guided 9-gauge vacuum-assisted breast biopsy: initial clinical experience. *Am J Roentgenol.* 2005;185(1):183-93
14. Carneiro GAC, Pereira FPA, Lopes FPPL, Calas MJG. Magnetic resonance imaging-guided vacuum-assisted breast biopsy: Experience and preliminary results of 205 procedures. *Radiol Bras.* 2018;51(6):351-57
15. Speer ME, Huang ML, Dogan BE, et al. High risk breast lesions identified on MRI-guided vacuum-assisted needle biopsy: Outcome of surgical excision and imaging follow-up. *Br J Radiol.* 2018;91(1090):20180300
16. ACR BI-RADS® Atlas, Breast Imaging Reporting and Data System. Reston, VA, American College of Radiology. 2013, 5th edition
17. Cheung KJ, Tam W, Chuang E, Osborne MP. Concurrent invasive ductal carcinoma and chronic lymphocytic leukemia manifesting as a collision tumor in breast. *Breast J.* 2007;13(4):413-17
18. Schell AM, Rosenkranz K, Lewis PJ. Role of breast MRI in the preoperative evaluation of patients with newly diagnosed breast cancer. *Am J Roentgenol.* 2009;192(5):1438-44
19. Houssami N, Ciatto S, Macaskill P, et al. Accuracy and surgical impact of magnetic resonance imaging in breast cancer staging: Systematic review and meta-analysis in detection of multifocal and multicentric cancer. *J Clin Oncol.* 2008;26(19):3248-58
20. Saslow D, Boetes C, Burke W, et al. American Cancer Society guidelines for breast screening with MRI as an adjunct to mammography. *Cancer J Clin.* 2007;57(2):75-89
21. Mann RM, Kuhl CK, Kinkel K, Boetes C. Breast MRI: Guidelines from the European Society of Breast Imaging. *Eur Radiol.* 2008;18(7):1307-18
22. Plantade R, Thomassin-Naggara I. MRI vacuum-assisted breast biopsies. *Diagn Interv Imaging.* 2014;95(9):779-801
23. Schrading S, Strobel K, Keulers A, et al. Safety and efficacy of magnetic resonance-guided vacuum-assisted large-volume breast biopsy (MR-Guided VALB). *Invest Radiol.* 2017;52(3):186-93
24. Gristina L, Rescinito G, Garlaschi A, et al. Freehand 3T MR-guided vacuum-assisted breast biopsy (VAB): A five-year experience. *Acta Radiol.* 2018;59(5):540-45
25. Jung HN, Han BK, Ko EY, Shin JH. Initial experience with magnetic resonance-guided vacuum-assisted biopsy in Korean women with breast cancer. *J Breast Cancer.* 2014;17(3):270-78
26. Dogan BE, Le-Petross CH, Stafford JR, et al. MRI-guided vacuum-assisted breast biopsy performed at 3 T with a 9-gauge needle: Preliminary experience. *Am J Roentgenol.* 2012;199(5):W651-53