



CASE REPORT

# Case Report: A giant but silent adrenal pheochromocytoma – a rare entity [version 1; referees: 2 approved]

Sunil Munakomi, Saroj Rajbanshi, Prof Shailesh Adhikary

Department of General Surgery, B.P. Koirala Institute of Health Sciences, Dharan, Nepal

**v1** First published: 07 Mar 2016, 5:290 (doi: [10.12688/f1000research.8168.1](https://doi.org/10.12688/f1000research.8168.1))  
 Latest published: 07 Mar 2016, 5:290 (doi: [10.12688/f1000research.8168.1](https://doi.org/10.12688/f1000research.8168.1))

**Abstract**

Herein we report a rare entity of a giant adrenal pheochromocytoma in a fifty-year-old male presenting with a vague abdominal pain. A computerised tomogram of the abdomen revealed a well-defined left supraadrenal giant lesion with no evidence of invasion to surrounding structures. The patient underwent surgical excision without any untoward postoperative events. Histopathological study revealed a benign pheochromocytoma. This report highlights the importance of acknowledging the fact that sometimes a giant adrenal pheochromocytoma can present with paucity of clinical signs and symptoms. Thorough investigations and a multidisciplinary team approach may lead to a better outcome in these patients.

**Open Peer Review**

Referee Status:

	Invited Referees	
	1	2
version 1 published 07 Mar 2016	 report	 report
<b>1 Venugopal Sarveswaran, Sri</b> Ramakrishna Hospital India		
<b>2 Prasanna Kumar Reddy, Apollo Hospitals India, Nadeem Mushtaque, Apollo Hospitals India</b> <b>Vimalkumar Dhaduk, Apollo Hospitals India</b>		

**Discuss this article**

Comments (0)

**Corresponding author:** Sunil Munakomi ([sunilmunakomi@gmail.com](mailto:sunilmunakomi@gmail.com))

**How to cite this article:** Munakomi S, Rajbanshi S and Adhikary PS. **Case Report: A giant but silent adrenal pheochromocytoma – a rare entity [version 1; referees: 2 approved]** *F1000Research* 2016, 5:290 (doi: [10.12688/f1000research.8168.1](https://doi.org/10.12688/f1000research.8168.1))

**Copyright:** © 2016 Munakomi S *et al.* This is an open access article distributed under the terms of the [Creative Commons Attribution Licence](https://creativecommons.org/licenses/by/4.0/), which permits unrestricted use, distribution, and reproduction in any medium, provided the original work is properly cited.

**Grant information:** The author(s) declared that no grants were involved in supporting this work.

**Competing interests:** The authors declare no conflict of interest.

**First published:** 07 Mar 2016, 5:290 (doi: [10.12688/f1000research.8168.1](https://doi.org/10.12688/f1000research.8168.1))

## Introduction

Giant pheochromocytomas (> 7 cm in size) are rare entities with around 20 cases reported in the literature<sup>1-6</sup>. They do not present with the classical symptoms of pheochromocytomas<sup>6</sup>. Most patients present with vague discomfort while others may complain of a palpable abdominal mass. Operative surgery is the ideal management option<sup>7</sup>. There needs to be a multidisciplinary approach while managing such cases. Stringent preparation to combat crisis due to catecholamine surge (during tumor manipulation) and sudden decrease in peripheral vascular resistance (following lesional excision) need to be emphasized<sup>8,9</sup>. Presence of chromaffin cells in the extra-adrenal tissue is the only confirmative method of distinguishing the malignant variant from its benign counterpart<sup>10</sup>. Herein we highlight and discuss the management algorithm taken while managing one such case.

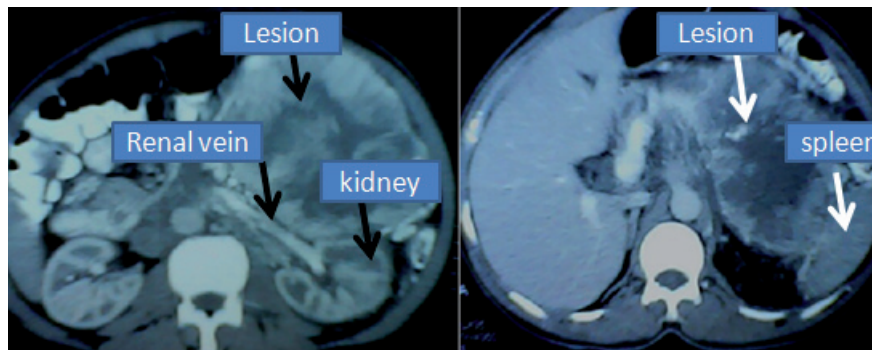
## Case report

A fifty-year-old male from Dhahran, Nepal presented to the surgical outpatient clinic with a vague symptom of abdominal discomfort. He had no history of trauma, persistent vomiting, altered bowel habits, change in the color of the stool or abdominal distension. There were no significant past medical or surgical illnesses. Family history of similar symptoms was also absent. Examination of the abdomen was normal except for slight discomfort during palpation in his left

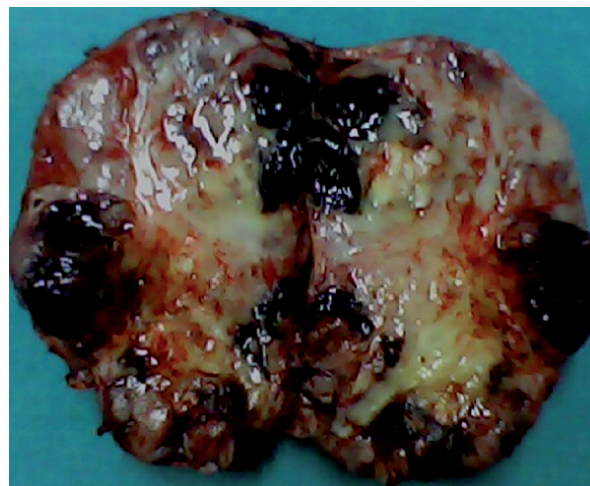
upper quadrant. Ultrasound examination of the abdomen revealed a huge left suprarenal mass. Computerised tomogram (CT) of the abdomen confirmed a giant mass of approximately 12×8 cm<sup>2</sup> in the left suprarenal region showing rim enhancement and areas of low attenuation within it. The left renal vein was normal and the lesion was slightly abutting the spleen (Figure 1).

The patient denied attacks of headache, chest pain, palpitation and sweating. The serum and urinary catecholamine levels were within normal range. The patient was kept for observation with 24 hour electrocardiography (ECG) and blood pressure monitoring (BP) which was normal.

The patient and his relatives were explained of the disease entity and were advised for surgery. With written consent, he was prepared for surgery. The anesthesiologists prepared medication (Intravenous (i.v.) Phentolamine (1 mg injection), Nitroprusside (4 mg drip) and Esmolol (30 mg injection) for potential intra-operative crisis pertaining to catecholamine surge during surgical manipulation. Vasoactive agents were also made available for combating sudden loss of peripheral vascular resistance following tumor removal. Early vascular control was secured. There was a well demarcated plane to dissect the tumor from the surrounding structures (Figure 2).



**Figure 1.** CT images showing the giant suprarenal lesion abutting the spleen but with no invasion of the kidney or the renal vein.



**Figure 2.** Cut specimen of the excised lesion showing areas of scattered hemorrhages.

The patient was extubated and was kept in the intensive care unit (ICU) for 48 hours. There were no untoward events in the post-operative period and the patient was discharged home on the 10<sup>th</sup> day. Histopathological study revealed zellballen nests of chromaffin cells with no invasion of the capsule (Figure 3), which is highly suggestive of a benign pheochromocytoma.

The patient is asymptomatic 4 years following surgery, and has been advised to follow up periodically in order to rule out early recurrence.

## Discussion

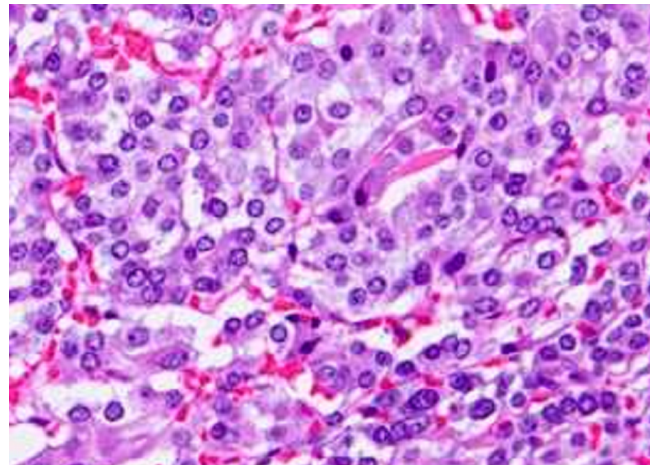
Pheochromocytomas typically present with the characteristic triad of paroxysmal attacks of headache, sweating and palpitation<sup>11</sup>. However giant lesions paradoxically may lack these symptoms<sup>6</sup>. The reasons for the same can be due of the presence of tumoral necrosis, high loads of interstitial tissue compared to chromaffin cells or the paucity of the release of the catecholamines due to encapsulation by the connective tissues<sup>6</sup>. This may also cause normal catecholamine values during their serum and urinary assays<sup>2</sup>.

CT scan is the image modality of choice to diagnose the condition<sup>4</sup>. However, in cases of giant lesions, there may be difficulties indetermining the organ of origin o leading to mis-diagnosis of the entity<sup>2</sup>.

Open surgical removal is the therapeutic target<sup>7</sup>. Laparoscopic removal is reserved only for smaller lesions<sup>12,13</sup>. Some authors have suggested preoperative embolisation of these lesion<sup>14</sup>. However, it may be tenacious due to major arterio-venous connections within the lesion<sup>6</sup>. The key to a successful outcome is the fine tuning between the surgeons and the anesthetist in the peri-operative period<sup>8,9</sup>. There needs to be minimal handling of the lesion and an early control of the adrenal vein so as to limit crisis due catecholamine surge<sup>6</sup>.

Pheochromocytoma of the adrenal gland scaled score (PASS) score has been described to differentiate between the benign and the malignant lesions<sup>15</sup>. But the hallmark of the malignant counterpart is the presence of the ectopic chromaffin cells in the extra-adrenal sites<sup>10</sup>.

The patients need to be on a periodic follow up so as to exclude the risk of recurrence<sup>16</sup>. There are still no set therapeutic guidelines in the management of the malignant lesions due to paucity of cases. Long term prognosis is dismal with five year survival of around 50% only<sup>17</sup>.



**Figure 3.** Histopathology revealing characteristic zellballen nests of cells separated by fibrovascular stroma.

## Conclusion

Though benign, surgery is advocated for giant pheochromocytomas. Early vascular control, minimal handling of the tumor and a multidisciplinary approach to combat potential intra-operative crisis are the cornerstones in managing such cases. Malignant counterparts need to be excluded histologically. Patients require regular follow up to rule out recurrence.

## Consent

Written informed consent was obtained from the patient for publication of this case report and any accompanying images and/or other details that could potentially reveal the patient's identity.

## Author contributions

Dr Sunil prepared the manuscript and obtained the pictures. Dr Saroj and Prof Shailesh revised and confirmed the final manuscript. All authors have seen and agreed to the final content of the manuscript.

## Competing interests

The authors declare no conflict of interest.

## Grant information

The authors declare that no funding was involved in supporting this work.

## References

1. Sarveswaran V, Kumar S, Kumar A, *et al.*: **A giant cystic pheochromocytoma mimicking liver abscess an unusual presentation - a case report.** *Clin Case Rep.* 2015; **3**(1): 64–68. [PubMed Abstract](#) | [Publisher Full Text](#) | [Free Full Text](#)
2. Wang HL, Sun BZ, Xu ZJ, *et al.*: **Undiagnosed giant cystic pheochromocytoma: A case report.** *Oncol Lett.* 2015; **10**(3): 1444–1446. [PubMed Abstract](#) | [Publisher Full Text](#) | [Free Full Text](#)
3. Korgali E, Dunder G, Gokce G, *et al.*: **Giant malignant pheochromocytoma with palpable rib metastases.** *Case Rep Urol.* 2014; **2014**: 354687. [PubMed Abstract](#) | [Publisher Full Text](#) | [Free Full Text](#)
4. Ambati D, Jana K, Domes T: **Largest pheochromocytoma reported in Canada: A case study and literature review.** *Can Urol Assoc J.* 2014; **8**(5–6): E374–E377. [PubMed Abstract](#) | [Publisher Full Text](#) | [Free Full Text](#)
5. Soufi M, Lahlou MK, Benamr S, *et al.*: **Giant malignant cystic pheochromocytoma: a case report.** *Indian J Surg.* 2012; **74**(6): 504–506. [PubMed Abstract](#) | [Publisher Full Text](#) | [Free Full Text](#)

6. Li C, Chen Y, Wang W, *et al.*: **A case of clinically silent giant right pheochromocytoma and review of literature.** *Can Urol Assoc J.* 2012; **6**(6): E267–E269.  
[PubMed Abstract](#) | [Free Full Text](#)
7. Staren ED, Prinz RA: **Selection of patients with adrenal incidentalomas for operation.** *Surg Clin North Am.* 1995; **75**(3): 499–509.  
[PubMed Abstract](#)
8. Adenekan A, Faponle A, Badmus T, *et al.*: **Anaesthetic management of giant phaeochromocytoma in a patient with chronic renal disease.** *J West Afr Coll Surg.* 2011; **1**(2): 112–122.  
[PubMed Abstract](#) | [Free Full Text](#)
9. Antedomenico E, Wascher RA: **A case of mistaken identity: giant cystic pheochromocytoma.** *Curr Surg.* 2005; **62**(2): 193–198.  
[PubMed Abstract](#) | [Publisher Full Text](#)
10. Glodny B, Winde G, Herwig R, *et al.*: **Clinical differences between benign and malignant pheochromocytomas.** *Endocr J.* 2001; **48**(2): 151–9.  
[PubMed Abstract](#) | [Publisher Full Text](#)
11. Rodríguez González JM, Parrilla Paricio P, Piñero Madrona A: **Feocromocitoma.** In: Sitges-Serra A, Sancho Insenser J, editors. *Cirugía Endocrina.* Madrid, Spain: Aran; 1999; 143–150.
12. Wang HS, Li CC, Chou YH, *et al.*: **Comparison of laparoscopic adrenalectomy with open surgery for adrenal tumors.** *Kaohsiung J Med Sci.* 2009; **25**(8): 438–44.  
[PubMed Abstract](#) | [Publisher Full Text](#)
13. Tiberio GA, Baiocchi GL, Arru L, *et al.*: **Prospective randomized comparison of laparoscopic versus open adrenalectomy for sporadic pheochromocytoma.** *Surg Endosc.* 2008; **22**(6): 1435–9.  
[PubMed Abstract](#) | [Publisher Full Text](#)
14. Wang D, Li H, Zhang Y, *et al.*: **Selective arterial embolization in giant pheochromocytoma.** *Zhong Hua Mi Niao Wai Ke Za Zhi.* 2011; **32**(5): 299–302.  
[Publisher Full Text](#)
15. Thompson LD: **Pheochromocytoma of the Adrenal gland Scaled Score (PASS) to separate benign from malignant neoplasms: a clinicopathologic and immunophenotypic study of 100 cases.** *Am J Surg Pathol.* 2002; **26**(5): 551–566.  
[PubMed Abstract](#)
16. Low G, Sahi K: **Clinical and imaging overview of functional adrenal neoplasms.** *Int J Urol.* 2012; **19**(8): 697–708.  
[PubMed Abstract](#) | [Publisher Full Text](#)
17. Eisenhofer G, Bornstein SR, Brouwers FM, *et al.*: **Malignant pheochromocytoma: current status and initiatives for future progress.** *Endocr Relat Cancer.* 2004; **11**(3): 423–36.  
[PubMed Abstract](#) | [Publisher Full Text](#)

# Open Peer Review

Current Referee Status:



---

## Version 1

Referee Report 12 September 2016

doi:[10.5256/f1000research.8785.r16138](https://doi.org/10.5256/f1000research.8785.r16138)



**Prasanna Kumar Reddy, Nadeem Mushtaque, Vimalkumar Dhaduk**

Department of Minimal Access Surgery, Apollo Hospitals, Chennai, India

The format of the paper and the language are good. Giant adrenal tumors are not that rare, but always pose a diagnostic dilemma.

The CT pictures are informative and remaining diagnostic work up was done well. Even though it is solitary, non functioning, and showing no evidence of capsular invasion or any distant metastasis, a lot of emphasis was given on malignancy. The size of the tumor does not have any significance on malignancy. However one has to be aware of malignant potential.

The technique was described well, but the importance of not breaching the capsule was not sufficiently emphasized. Intraoperative hemodynamic parameters were not highlighted.

Presently the procedure of choice is laparoscopic adrenalectomy even up-to the size of 12 cm in minimally invasive surgical units with expertise as left supra renal is easily amenable. Vascular control with the presently available gadgets is much easier and the manipulation of the tumors is very minimal.

Corrections:

- Abstract - supra adrenal gland was mentioned instead of supra renal gland.
- Case report - Line 9 instead of chest pain it is misspelled as cheat pain.

The conclusion, even though it is adequate, is too brief.

An adequate number of references were quoted.

Impression - A good paper contributing various facts of giant pheochromocytoma, even though it is a single case report.

**We have read this submission. We believe that we have an appropriate level of expertise to confirm that it is of an acceptable scientific standard.**

**Competing Interests:** No competing interests were disclosed.

Referee Report 22 April 2016

doi:10.5256/f1000research.8785.r13171



**Venugopal Sarveswaran**

Department of General Surgery, Sri Ramakrishna Hospital, Coimbatore, India

I feel the case report seems to be an original one, though such cases have been published previously.

It provides sufficient details for others to learn, like it emphasizes that such clinical condition must be kept in mind and adequate safety precautions must be taken while operating on such patients, though all cases will not have intra-operative complications.

It states the clinical condition and investigations done.

An adequate number of references have been sited.

Hence I feel the article is acceptable.

**I have read this submission. I believe that I have an appropriate level of expertise to confirm that it is of an acceptable scientific standard.**

**Competing Interests:** No competing interests were disclosed.

---