



Capmatinib-Induced Liver Injury as Emerging Toxicity of MET Inhibitors in Patients With NSCLC Pretreated With Immune Checkpoint Inhibitors

Monia Sisi, MD,^{a,b} Giovanni Vitale, MD, PhD,^c Michele Fusaroli, MD,^d Mattia Riefolo, MD,^e Valentina Giunchi, BSc,^d Antonietta D'Errico, MD,^e Andrea Ardizzoni, MD,^{a,b} Emanuel Raschi, MD, PhD,^d Francesco Gelsomino, MD^{a,b,*}

^aMedical Oncology, IRCCS Azienda Ospedaliero-Universitaria di Bologna, Bologna, Italy

^bDepartment of Medical and Surgical Sciences (DIMEC), Alma Mater Studiorum University of Bologna, Bologna, Italy

^cInternal Medicine Unit for the Treatment of Severe Organ Failure, Istituto di Ricovero e Cura a Carattere (IRCCS) Azienda Ospedaliero-Universitaria di Bologna, Bologna, Italy

^dPharmacology Unit, DIMEC, Alma Mater Studiorum University of Bologna, Bologna, Italy

^eDepartment of Pathology, Istituto di Ricovero e Cura a Carattere (IRCCS) Azienda Ospedaliero-Universitaria di Bologna, Bologna, Italy

Received 20 June 2023; revised 31 July 2023; accepted 12 August 2023
Available online - 19 August 2023

ABSTRACT

Safety data on MET inhibitors in patients with advanced NSCLC harboring MET exon 14 mutation and treated with frontline immune checkpoint inhibitors (ICIs) are still limited. Here, we describe clinical characteristics, liver biopsy features, and management of liver injury of two patients with a diagnosis of MET exon 14-mutant NSCLC receiving capmatinib after ICI failure. On the basis of histologic findings and exclusion of other potential causes, a diagnosis of drug-induced liver injury (DILI) associated with portal fibrosis was made in both cases. The use of hepatoprotective drugs, in addition to oral ursodeoxycholic acid, resulted in liver blood tests normalization. To provide a global safety perspective, we queried the Food and Drug Administration Adverse Event Reporting System and detected a robust disproportionality signal. Out of the 918 total reports with capmatinib from the Food and Drug Administration Adverse Event Reporting System database, DILI was

recorded in 43 cases (4.7%), mostly serious (93.0%) with hospitalization and death recorded in 25.6% and 16.3% of the cases, respectively. The median time to onset was 42 days, with discontinuation and positive dechallenge documented in 41.9% and 39.5% of the cases, respectively. Anti-programmed cell death protein-1 agents were coreported in 11 DILI cases. Only two cases of DILI out of 105 reports were found for tepotinib. Our data support a potential association between capmatinib and DILI in patients who have also been previously exposed to immunotherapy. Considering the potential implications for sequence strategy and timing of ICI and MET inhibitor, further investigation is warranted.

© 2023 The Authors. Published by Elsevier Inc. on behalf of the International Association for the Study of Lung Cancer. This is an open access article under the CC BY-NC-ND license (<http://creativecommons.org/licenses/by-nc-nd/4.0/>).

*Corresponding author.

Drs. Raschi and Gelsomino contributed equally to this work.

Disclosure: Dr. Ardizzoni received research grants from Celgene, Bristol-Myers Squibb, Ipsen, and Roche; and honoraria for advisory roles from Bristol-Myers Squibb, Merck Sharp & Dohme, ROCHE, AstraZeneca, and Eli Lilly outside of the submitted work. Dr. Gelsomino received honoraria or personal fees for the advisory role or consulting from Eli Lilly, Novartis, AstraZeneca, and Bristol-Myers Squibb outside the submitted work. Dr. Raschi reports personal fees from Novartis outside of the submitted work. The remaining authors declare no conflict of interest.

Cite this article as: Sisi M, Vitale G, Fusaroli M, et al. Capmatinib-induced liver injury as emerging toxicity of MET inhibitors in patients

with NSCLC pretreated with immune checkpoint inhibitors. *JTO Clin Res Rep.* 2023;4:100563.

Address for correspondence: Francesco Gelsomino, MD, Medical Oncology, Istituto di Ricovero e Cura a Carattere (IRCCS) Azienda Ospedaliero-Universitaria di Bologna, via Albertoni 15, 40138 Bologna, Italy. E-mail: francesco_gelsomino@aosp.bo.it or francesco.gelsomino3@unibo.it.

© 2023 The Authors. Published by Elsevier Inc. on behalf of the International Association for the Study of Lung Cancer. This is an open access article under the CC BY-NC-ND license (<http://creativecommons.org/licenses/by-nc-nd/4.0/>).

ISSN: 2666-3643

<https://doi.org/10.1016/j.jtocrr.2023.100563>

Keywords: MET inhibitors; Immune checkpoint inhibitors; Liver toxicity; Drug-induced liver injury; FDA Adverse Event Reporting System

Introduction

MET is a protooncogene that could be deregulated by de novo gene amplification or aberrant splicing and skipping of MET exon 14 (METex14) in about 3% to 4% of advanced NSCLC, particularly in adenocarcinoma and sarcomatoid histologic subtypes.¹ On the basis of the results from the two phase 2 GEOMETRY mono-1 (NCT02414139) and VISION (NCT02864992) trials,^{2,3} capmatinib and tepotinib (selective type Ib MET inhibitors) have been recently approved by the European Medicines Agency for use in patients with advanced METex14-mutant NSCLC after receiving immunotherapy or platinum-based chemotherapy, or both.

Therefore, safety data on MET inhibitors in patients previously exposed to immune checkpoint inhibitors (ICIs) are still limited. Capmatinib and tepotinib exhibited a manageable profile.⁴ Peripheral edema (11% and 7%), liver enzymes (alanine aminotransferase [ALT], 7% and 3%; aspartate aminotransferase [AST], 3% and 2%), lipase (7% and 3%), and amylase (4% and 3%) elevations were the most common grade 3 or higher toxicities for capmatinib and tepotinib, respectively.

Materials and Methods

We describe clinical characteristics, liver biopsy histology, and management of liver injury occurring in two consecutive patients with a diagnosis of METex14-mutant NSCLC who received capmatinib after first-line immunotherapy failure. After resolution of liver toxicity, two-dimensional shear-wave elastography (Aixplore method), a noninvasive ultrasound-based method for the assessment of tissue stiffness with diagnostic performance comparable to vibration-controlled transient elastography (FibroScan),^{5,6} was performed to evaluate hepatic fibrosis grade in both patients. Informed consent was obtained from both patients.

To provide a global safety perspective, we queried the Food and Drug Administration Adverse Event Reporting System (FAERS), a consolidated spontaneous reporting database in oncology. The methodologic approach is described in the [Supplementary Material](#).

Results

Case Reports

The patients' characteristics are reported in [Table 1](#). Both patients experienced severe immune-related toxicities on pembrolizumab requiring systemic steroids,

but no events in terms of liver toxicity. Within 6 to 8 weeks from the beginning of capmatinib 400 mg twice daily, both patients developed hepatocellular drug-induced liver injury (DILI) with an increase of transaminases (>10 to 30 times the upper limit of the reference range) and total bilirubin elevation ([Table 1](#)) and associated with signs of early acute liver failure leading to treatment discontinuation and patients' hospitalization. In both cases, no previous history of liver disease was reported. Differential diagnosis with viral, vascular, and autoimmune liver injury was investigated and such causes were ruled out ([Table 1](#)). A liver biopsy was performed on both patients. Histopathologic features of liver samples from patient #1 and patient #2 are illustrated in [Figure 1](#) (A1–D1 and A2–D2, respectively). According to histologic findings, exclusion of other potential causes and the Roussel Uclaf Causality Assessment Method scale (score of 11), a diagnosis of DILI associated with portal fibrosis (Ishak 3 and Metavir 3) was made in both cases. We avoided the use of steroids, preferring instead the administration of hepatoprotective agents (intravenous N-acetylcysteine and ademetionine) combined with anticholestatic drugs, such as oral ursodeoxycholic acid,⁷ with progressive normalization of liver function blood tests ([Fig. 2A](#) for patient #1 and [Fig. 2B](#) for patient #2).

Two-dimensional shear-wave elastography was performed at the time of DILI resolution and confirmed severe hepatic fibrosis in both patients (median value 12.3 kPa and 10.9 kPa, respectively). After treatment discontinuation and DILI resolution, both patients underwent radiologic tumor assessment with evidence of stable disease. Whereas patient 2 did not resume any anticancer therapy and passed away after 23.1 months from the initial diagnosis, patient 1 received third-line chemotherapy (carboplatin plus gemcitabine) up to four courses, with no liver impairment, and progressive disease as the best response. On the basis of the time elapsed from DILI onset (25 wk) and the last ICI administration (42 wk), a switch to another MET tyrosine kinase inhibitor was proposed. In August 2022, the patient started tepotinib 450 mg once daily with good tolerability and no evidence of liver toxicity but experiencing progressive disease (progression-free survival of 3.35 mo). No other anticancer therapy was started, and he passed away after 26.2 months from the diagnosis.

Pharmacovigilance Data From FAERS

Out of the 918 total reports with capmatinib, DILI was recorded in 43 cases (4.7%), mainly hepatotoxicity (n = 11), hepatic cytolysis (9), hepatitis (7), and ascites (5). Most cases (93.0%) were serious, with hospitalization and death recorded in 25.6% and 16.3% of the

Table 1. Patients' Characteristics

Characteristic	Patient #1	Patient #2
Age	64	82
Sex	M	F
Smoking habit	Never	Never
BMI	23.78	17.63
Histology	Squamous	Adenocarcinoma
Stage	IVB	IVB
PD-L1 TPS expression (clone SP263, Ventana), %	35	55
Other gene alterations (OncoPrint Focus Assay - ThermoFisher Scientific)	CDK4 amplification	No
Personal and or family history of autoimmune disease	No	No
Liver comorbidities	Unknown	Unknown
History of alcohol abuse	No	No
Concomitant drugs	Amlodipine 10 mg, allopurinol 150 mg, levothyroxine 100 mcg, pantoprazole 20 mg	Sitagliptin 100 mg, gliclazide 60 mg, metformin 500 mg, Enoxaparin 4000 UI, Insulin aspart, Insulin glargine, metoprolol 25 mg bid, Duloxetine 60 mg, Fentanyl TD 12 µg/h
ANA-reflex baseline	<1:80	1:160 speckled (anti-dsDNA, ENA/ANA, ANCA, anti-PR3, anti-MPO negative)
IgA, IgM, IgG	In reference range	In reference range
IgG subclasses	In reference range	In reference range
First-line therapy	Pembrolizumab/nab-paclitaxel/ carboplatin × 4 courses followed by pembrolizumab maintenance × 5 courses	Pembrolizumab 200 mg flat dose q21 × 14 courses
Best response	PR	PR
Treatment discontinuation	PD	PD
irAEs	Hypothyroidism, dermatitis, myositis, myasthenic syndrome	Polyneuropathy of small-caliber fibers
Time from ICI initiation to irAEs onset (wk)	29.86	18.86
Steroid	Yes	Yes
Time of steroid intake (wk)	6.71	8.57
Time from ICI discontinuation to capmatinib initiation (wk)	8.28	13.71
Time from capmatinib initiation to DILI evidence (wk)	8.86	5.71
Max ALT value (reference range)	1689 (<50 U/liter)	955 (<35 U/liter)
Max AST value (reference range)	512 (<50 U/liter)	543 (<35 U/liter)
Max total bilirubin value (reference range)	9.12 (<1.2 mg/dL)	4.64 (<1.2 mg/dL)
Max direct bilirubin value (reference range)	4.6 (<0.3 mg/dL)	2.89 (<0.3 mg/dL)
Max indirect bilirubin value (reference range)	4.52 (<0.9 mg/dL)	1.75 (<0.9 mg/dL)
Max GGT value (reference range)	308 (<55 U/liter)	173 (<38 U/liter)
Max ALP value (reference range)	255 (30-120 U/liter)	229 (30-120 U/liter)
MELD score	22	17
HAV/HBV/HCV/HEV/Herpes simplex 1-2/Parvovirus B19/CMV/EBV/HHV6/HHV8	Negative	Negative
Liver US + color Doppler	Negative for metastases and VOD	Negative for liver progressive disease and VOD
RUCAM scale	11 (>8; high probable)	11 (>8; high probable)

(continued)

Table 1. Continued

Characteristic	Patient #1	Patient #2
Other toxicities (including acute liver failure abnormalities)	G3 fibrinogen decreased; G2 hypoalbuminemia; G1 asthenia, nausea, peripheral edema, PT, and aPTT prolongation	G2 asthenia, diarrhea, and hypoalbuminemia; G1 abdominal discomfort, peripheral edema, PT, and aPTT prolongation
Treatment for DILI	N-acetyl-cysteine 159 mg/kg ev d1 → 100 mg/kg ev daily + Adenometionine 500 mg ev daily + UDCA 15 mg/kg daily	N-acetyl-cysteine 159 mg/kg ev d1 → 100 mg/kg ev daily + Adenometionine 500 mg ev daily + UDCA 6.66 mg/kg daily
Liver biopsy	Drug-induced liver damage associated with portal fibrosis (Ishak 3 Metavir 3)	Lobular and periportal necrosis associated with portal fibrosis (Ishak 3 Metavir 3)
PD-L1 TPS expression (clone SP263, Ventana) on hepatocyte	10%	30%
Fibroscan (2D-SWE Aixplorer method)	Median value 12.3 kPa IQR 1.6 kPa	Median value 10.9 kPa IQR 0.9 kPa

#, number; 2D-SWE, two-dimensional shear wave elastography; ALP, alkaline phosphatase; ALT, alanine aminotransferase; ANA, antinuclear antibodies; ANCA, anti-neutrophil cytoplasmic antibody; anti-dsDNA, anti-double stranded DNA; anti-MPO, anti-myeloperoxidase; anti-PR3, anti-proteinase-3; aPTT, activated partial thromboplastin time; AST, aspartate transaminase; bid, bis in die (twice daily); BMI, body mass index; CDK4, cyclin-dependent kinase 4; CMV, cytomegalovirus; DILI, drug-induced liver injury; EBV, Epstein Barr virus; ENA, extractable nuclear antigen; F, female; G1, grade 1; G2, grade 2; G3, grade 3; GGT, gamma-glutamyltransferase; HAV, hepatitis A virus; HBV, hepatitis B virus; HCV, hepatitis C virus; HEV, hepatitis E virus; HHV6, human herpesvirus 6; HHV8, human herpes virus 8; ICI, immune checkpoint inhibitor; IgA, immunoglobulin A; IgG, immunoglobulin G; IgM, immunoglobulin M; IQR, interquartile range; irAEs, immune-related adverse events; kPa, kilopascal; M, male; Max, maximum; MELD, model for end-stage liver disease; PD, progressive disease; PD-L1 TPS, programmed cell death ligand-1; PR, partial response; PT, prothrombin time; RUCAM, Roussel Uclaf Causality Assessment Method; TPS, tumor proportion score; UDCA, ursodeoxycholic acid; US, ultrasound; VOD, veno-occlusive disease.

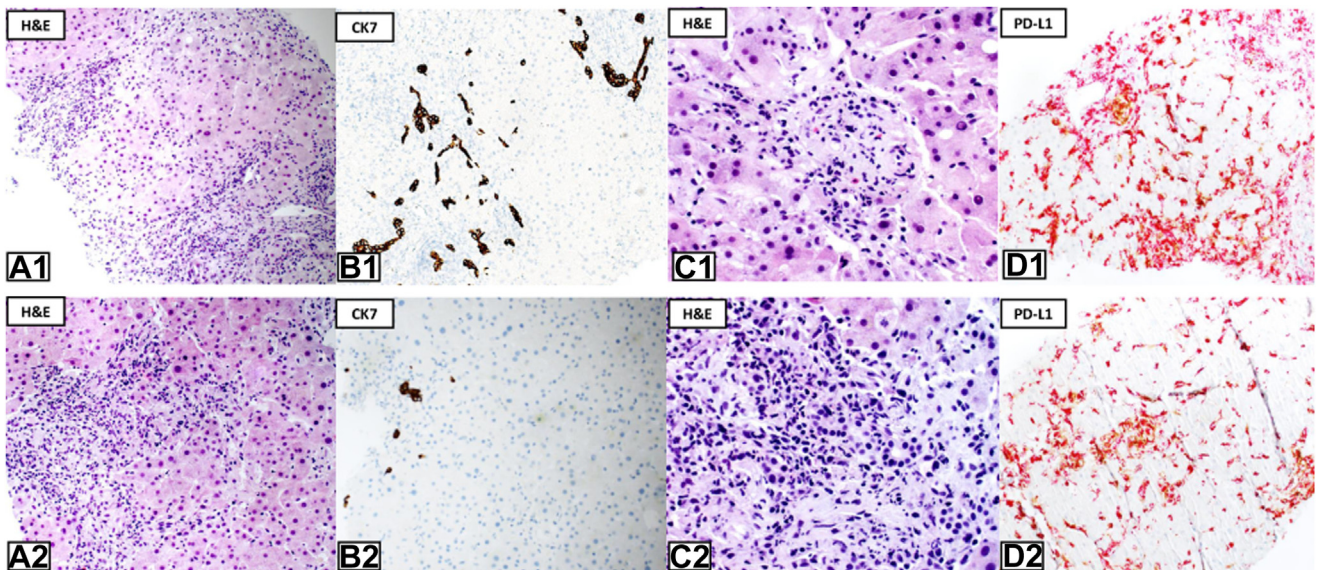


Figure 1. Liver histology from patient 1: (A1) Figure fibrotic septa with moderate chronic inflammation and periportal necrosis were present (H&E); (B1) biliary duct regression and biliary duct hyperplasia (CK7); (C1) inflammatory infiltrate comprised macrophages, lymphocytes and eosinophilic granulocytes (H&E); and (D1) double stain PD-L1 using antiPD-L1/CD274 (clone SP142; Spring) antibody, was expressed (in brown) in 10% of hepatocytes by a strong granular immunoreactivity in the cytoplasm of the liver cells, whereas CD68+ cells were expressed in red. Liver sample from patient 2: (A2) fibrotic septa with moderate chronic inflammation, periportal, and lobular necrosis were present (H&E); (B2) no findings of biliary regression and cholestasis (CK7); (C2) inflammatory infiltrate consisted of macrophages, lymphocytes, and occasional plasma cells (H&E); and (D2) double stain PD-L1, using antiPD-L1/CD274 (clone SP142; Spring) antibody, was expressed (in brown) 30% of hepatocytes, whereas CD68+ cells were expressed in red. In both biopsies, other lobular changes (i.e., steatosis, nuclear glycogenation) were absent and reticulin stain excluded sinusoidal fibrosis. H&E, hematoxylin, and eosin; PD-L1, programmed cell death ligand-1.

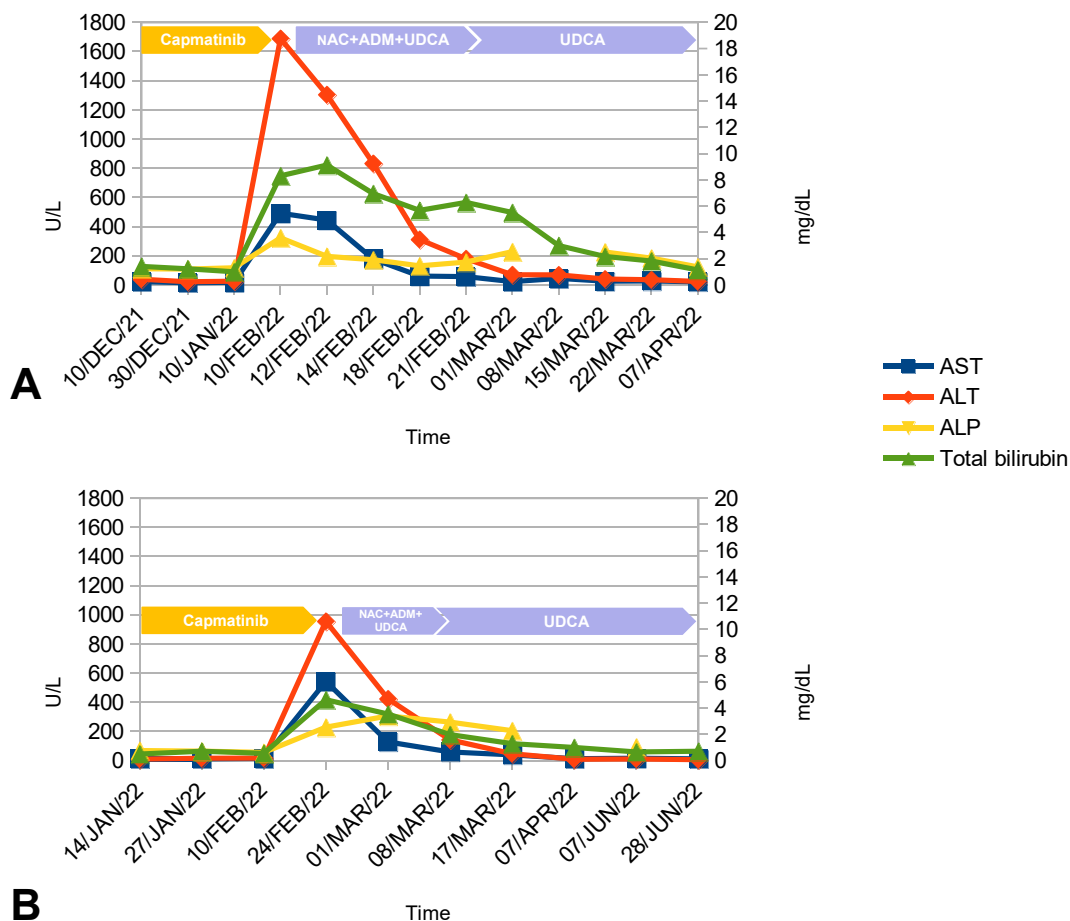


Figure 2. Curve trend of liver function blood tests in patient 1 (A) and patient 2 (B). ADM, adenomethionine; ALP, alkaline phosphatase; ALT, alanine aminotransferase; AST, aspartate aminotransferase; NAC, N-acetylcysteine; UDCA, ursodeoxycholic acid.

cases, respectively. Discontinuation was documented in 41.9% of cases and positive dechallenge in 39.5%. The median time to onset, calculated for 29 cases, was 42 days (interquartile range: 27–60). Anti-programmed cell death protein 1 (PD-1) agents were co-reported in 11 DILI cases, mainly spartalizumab ($n = 8$). In 10 (23.26%) patients, at least two drugs with hepatotoxic potential were reported, especially atorvastatin and metformin ($n = 4$ each).

We retrieved 105 reports with tepotinib, with only 2 cases (1.9%) of DILI (all without coreported ICI), recorded as a hepatobiliary disease ($n = 1$) and ascites (1). One case was classified as life-threatening, whereas the other one required hospitalization. The times to onset were of 63 and 380 days, without coreported drugs.

A consistent disproportionality was detected for capmatinib, but not for tepotinib, across all primary analyses (Supplemental Material): in sensitivity ones, a statistically significant disproportionality emerged for capmatinib in four out of six analyses, suggesting a potential association between this drug and serious

liver injury, also in naive patients without coreported ICI.

Discussion

To best of our knowledge, this is the first report that broadly describes the occurrence of serious DILI on capmatinib in two consecutive patients with NSCLC previously treated with ICI.

In the GEOMETRY mono-1 study, 60 (20%) of 298 pretreated patients with NSCLC had received immunotherapy. A higher incidence of both treatment-related serious adverse events and capmatinib discontinuation rate was reported among ICI-pretreated MET-mutant patients compared with patients who did not previously receive ICI. However, capmatinib exhibited a manageable liver toxicity profile across both subgroups. ALT elevation incidence was higher in the ICI-pretreated group (15.6% of all grades, 9.4% of grade ≥ 3) compared with the subgroup without ICI exposure (11.8% and 5.9%), although no substantial differences emerged.⁸

Among patients included in the VISION trial who received previous ICI, the incidence of elevated ALT and AST levels (of any grade) were like that observed in the overall study population (9.1% versus 8.6% and 7.6% versus 5.9%, respectively).⁹

We acknowledge the strengths and limitations of our report. First, the patient's clinical features, diagnostic workup and management were highly superimposable. These cases were also corroborated by pharmacovigilance analysis from FAERS with a robust disproportionality signal, suggesting a potential association between capmatinib and DILI. However, we are aware of the limitations of pharmacovigilance data such as the inability to infer firm causality and calculate true incidence, the lack of comprehensive clinical features, schedule/dosage (and exact sequencing/previous ICI exposure), laboratory and instrumental data, underlying/preexisting hepatic impairment.

Our hypothesis is that chronic liver damage, primarily promoted by ICI, could increase the susceptibility to DILI occurrence once capmatinib was commenced. Of note, capmatinib (and tepotinib) are not listed by LiverTox Bookshelf (<https://www.ncbi.nlm.nih.gov/books/NBK547852/>; accessed on July 24, 2023), a reference source on DILI for clinicians. With regard to biological plausibility, capmatinib exhibits some recognized physicochemical and pharmacokinetic properties associated with DILI susceptibility,¹⁰ such as high lipophilicity ($\log P \geq 3$), substantial cytochrome 3A4 metabolism (53%) and in vitro inhibition of hepatic uptake transporters (https://www.ema.europa.eu/en/documents/product-information/trabecta-epar-product-information_en.pdf; last updated January 25, 2023).

The histologic examination of our cases also does not disagree with the diagnosis of immune-mediated hepatitis. Although a typical picture of ICI-related hepatitis has not yet been defined, a pattern of lobular hepatitis occurs more frequently in patients receiving anti-PD-1 or programmed cell death ligand-1 (PD-L1) agents. Moreover, a mixed pattern characterized by the presence of periportal necrosis associated with biliary duct regression and hyperplasia has been described,^{11,12} including also in our cases. Notably, liver biopsies revealed low-moderate expression of PD-L1 on hepatocytes, although its significance is unknown. The increase of liver PD-L1 expression maybe linked to concomitant liver disease or silent hepatic metastases; this condition could trigger the synthesis of liver self-antigens and proinflammatory cytokines leading to activation of T cells involved in ICI-related DILI.¹³

Several studies have reported a higher incidence of adverse events by using sequential ICI and other tyrosine kinase inhibitors in NSCLC, including hypersensitivity reactions, hepatitis, and pneumonitis.¹⁴⁻¹⁷ In

addition to the treatment sequence, another relevant issue is whether the risk of liver toxicity on capmatinib may be time-dependent in patients previously exposed to ICI. In KRAS^{G12C}-mutant NSCLC, the time from ICI to sotorasib use (≤ 90 d versus > 90 d) correlated significantly with a higher risk of grade 3 or higher hepatotoxicity.¹⁸ In a French multicenter retrospective study, 102 patients with KRAS^{G12C}-mutant NSCLC received sotorasib, including 48 of them after ICI and 54 not in sequence (control group). The authors reported that severe sotorasib-related liver toxicity was threefold more frequent in the sequence group compared with the control group (33% versus 11%, $p = 0.006$).¹⁹

A phase 2 trial (CINC280J12201) investigating the combination of spartalizumab (anti-PD-1) and capmatinib as first-line treatment in patients with advanced METex14 NSCLC has halted patient enrollment during the run-in part (31 patients treated) because of safety. A total of 35% (all of grade ≥ 3) of treatment-related severe adverse events have been reported, leading to treatment discontinuation in all cases (22.6% for ALT elevation and 9.7% for AST elevation) with 80.6% of patients needing dose reduction/interruption (32.3% for peripheral edema, 25.8% each for elevated ALT and AST levels).²⁰

We only found a case report of severe hepatotoxicity during treatment with capmatinib preceded by anti-PD-1 pembrolizumab with a fatal outcome. In addition, in this case, N-acetylcysteine perfusion was initiated. Corticosteroids were not administered because an immune-mediated cause was not considered plausible, although a liver biopsy was not performed.²¹

Considering the potential implications for sequencing strategy and timing of these two different therapies, we suggest noninvasive transient elastography to ICI-exposed patients before starting a MET inhibitor to evaluate the presence of liver fibrosis related to chronic damage. In the presence of significant fibrosis, we propose to delay MET inhibitor, when feasible, by at least 3 months from ICI termination; alternatively, closer monitoring of transaminase enzymes could be considered (at least every 2 weeks, especially in the first 2 mo) in addition to prophylactic ursodeoxycholic acid or other hepatoprotective drugs once MET inhibitor has started.

For patients who develop severe liver toxicity, particularly in the presence of acute liver impairment, steroids should be avoided because of the high risk of infectious complications.

Finally, the occurrence of severe liver toxicity should not be considered a priori as an exclusion criterion for a subsequent rechallenge or switch to another MET inhibitor.

To conclude, we first histologically described the occurrence of acute liver injury on the fibrotic liver in

two patients with advanced NSCLC exposed to capmatinib and previously treated with ICI. A potential association between capmatinib and DILI in ICI-exposed patients was also supported by a robust pharmacovigilance signal in the FAERS database. These findings could also have significant implications for sequencing strategy and timing of immune checkpoint and MET inhibitors, at least in European countries.

Further investigation is warranted in the real-world setting to provide evidence of a possible hepatotoxic class effect shared by MET inhibitors and to better characterize drug- and patient-related risk factors.

CRedit Authorship Contribution Statement

Monia Sisi: Data curation, Investigation, Writing-original draft, Writing-review draft.

Giovanni Vitale: Conceptualization, Investigation, Validation, Writing-original draft, Writing-review draft.

Michele Fusaroli: Methodology, Software, Validation, Formal analysis, Investigation, Data curation, Writing-review draft.

Mattia Riefolo: Resources, Writing-review draft.

Valentina Giunchi: Methodology, Software, Validation, Formal analysis, Investigation, Data curation, Writing-review draft.

Antonietta D'Errico: Resources, Writing-review draft.

Andrea Ardizzoni: Conceptualization, Investigation, Validation, Writing-review draft, Supervision.

Emanuel Raschi: Conceptualization, Methodology, Software, Validation, Formal analysis, Investigation, Data curation, Writing-review draft, Supervision.

Francesco Gelsomino: Conceptualization, Investigation, Validation, Data curation, Writing-original draft, Writing-review draft, Supervision, Project administration.

Acknowledgment

Drs. Raschi and Ardizzoni are supported by Institutional Research Funds (Ricerca Fondamentale Orientata).

Supplementary Data

Note: To access the supplementary material accompanying this article, visit the online version of the *JTO Clinical and Research Reports* at www.jtocrr.org and at <https://doi.org/10.1016/j.jtocrr.2023.100563>.

References

1. Cancer Genome Atlas Research Network. Comprehensive molecular profiling of lung adenocarcinoma. *Nature*. 2014;511:543-550.
2. Wolf J, Seto T, Han JY, et al. Capmatinib in *MET* exon 14-mutated or *MET*-amplified non-small-cell lung cancer. *N Engl J Med*. 2020;383:944-957.
3. Paik PK, Felip E, Veillon R, et al. Tepotinib in non-small-cell lung cancer with *MET* Exon 14 skipping mutations. *N Engl J Med*. 2020;383:931-943.
4. Cortot A, Le X, Smit E, et al. Safety of *MET* tyrosine kinase inhibitors in patients with *MET* exon 14 skipping non-small cell lung cancer: a clinical review. *Clin Lung Cancer*. 2022;23:195-207.
5. Castera L, Fornis X, Alberti A. Non-invasive evaluation of liver fibrosis using transient elastography. *J Hepatol*. 2008;48:835-847.
6. Cassinotto C, Lapuyade B, Guiu B, et al. Agreement between 2-dimensional shear wave and transient elastography values for diagnosis of advanced chronic liver disease. *Clin Gastroenterol Hepatol*. 2020;18:2971-2979.e3.
7. Li M, Luo Q, Tao Y, Sun X, Liu C. Pharmacotherapies for drug-induced liver injury: A current literature review. *Front Pharmacol*. 2022;12:806249.
8. Vansteenkiste JF, Smit EF, Groen HJM, et al. Capmatinib in patients with *MET*ex14-mutated advanced nonsmall cell lung cancer who received prior immunotherapy: the phase II GEOMETRY mono-1 study. *Ann Oncol*. 2020;31(suppl 4):S830.
9. Le X, Sakai H, Felip E, et al. Tepotinib efficacy and safety in patients with *MET* exon 14 skipping NSCLC: outcomes in patient subgroups from the VISION study with relevance for clinical practice. *Clin Cancer Res*. 2022;28:1117-1126.
10. European Association for the Study of the Liver. Clinical Practice Guideline Panel: Chair; Panel members; EASL Governing Board representative. EASL clinical practice guidelines: drug-induced liver injury. *J Hepatol*. 2019;70:1222-1261.
11. De Martin E, Michot JM, Papouin B, et al. Characterization of liver injury induced by cancer immunotherapy using immune checkpoint inhibitors. *J Hepatol*. 2018;68:1181-1190.
12. Cohen JV, Dougan M, Zubiri L, Reynolds KL, Sullivan RJ, Misdraji J. Liver biopsy findings in patients on immune checkpoint inhibitors. *Mod Pathol*. 2021;34:426-437.
13. Suzman DL, Pelosof L, Rosenberg A, Avigan MI. Hepatotoxicity of immune checkpoint inhibitors: an evolving picture of risk associated with a vital class of immunotherapy agents. *Liver Int*. 2018;38:976-987.
14. McCoach CE, Rolfo C, Drilon A, et al. Hypersensitivity reactions to seliperatinib treatment with or without prior immune checkpoint inhibitor therapy in patients with NSCLC in LIBRETTO-001. *J Thorac Oncol*. 2022;17:768-778.
15. Lin JJ, Chin E, Yeap BJ, et al. Increased hepatotoxicity associated with sequential immune checkpoint inhibitor and crizotinib therapy in patients with non-small cell lung cancer. *J Thorac Oncol*. 2019;14:135-140.
16. Oshima Y, Tanimoto T, Yuji K, Tojo A. EGFR-TKI-associated interstitial pneumonitis in nivolumab-treated patients with non-small cell lung cancer. *JAMA Oncol*. 2018;4:1112-1115.

17. Schoenfeld AJ, Arbour KC, Rizvi H, et al. Severe immune-related adverse events are common with sequential PD-(L)1 blockade and osimertinib. *Ann Oncol*. 2019;30:839-844.
18. Rakshit S, Bansal R, Potter A, et al. Time from immune checkpoint inhibitor to sotorasib correlates with risk of hepatotoxicity in non-small cell lung cancer. *J Thorac Oncol*. 2022;17(suppl):S186.
19. Chour A, Denis J, Mascaux C, et al. Brief report: Severe sotorasib-related hepatotoxicity and non-liver adverse events associated with sequential anti-PD(L)1 and sotorasib therapy in KRASG12C-mutant lung cancer [e-pub ahead of print]. *J Thorac Oncol*. <https://doi.org/10.1016/j.jtho.2023.05.013>. Accessed May 25, 2023.
20. Wolf J, Heist R, Kim TM, et al. Efficacy and safety of capmatinib plus spartalizumab in treatment-naïve patients with advanced NSCLC harboring *MET* exon 14 skipping mutation. *Ann Oncol*. 2022;33(suppl):S1007-S1008.
21. Valencia Soto CM, Martínez Callejo V, García-Avello Fernandez-Cueto A, et al. Severe hepatotoxicity during treatment with capmatinib [e-pub ahead of print]. *J Oncol Pharm Pract*. <https://doi.org/10.1177/10781552231173120>. Accessed July 23, 2023.