



Received: 2014.03.01
Accepted: 2014.03.26
Published: 2014.09.07

Authors' Contribution:

- A** Study Design
- B** Data Collection
- C** Statistical Analysis
- D** Data Interpretation
- E** Manuscript Preparation
- F** Literature Search
- G** Funds Collection

The Doppler Ultrasonographic Evaluation of Hemodynamic Changes in Hepatic Vascular Structures in Patients with Hepatosteatosi

Mehmet Karasin^{BC}, Ozlem Tokgoz^{ADG}, İsmail Serifoglu^{EF}, İlker Oz^F, Oktay Erdem^F

Department of Radiology, Bulent Ecevit University, School of Medicine, Zonguldak, Turkey

Author's address: Ozlem Tokgoz, Department of Radiology, Bulent Ecevit University, School of Medicine, Zonguldak, Turkey, e-mail: h_tokgoz@hotmail.com

Background:

The hemodynamic changes in hepatic vascular structures of hepatosteatosi patients were examined using Doppler ultrasonography.

Material/Methods:

Ninety hepatosteatosi patients, classified as mild, moderate or severe, and 30 healthy volunteers were included in this 120-person study. The height, weight, liver size, blood lipids and blood liver function tests of the subjects were measured. Those values were compared in the patient and control groups. In the patient and control groups, color duplex Doppler ultrasonography was used to examine portal vein peak velocity, portal vein flow volume, hepatic artery resistive index (RI), hepatic artery pulsatility index (PI) and hepatic artery flow volume.

Results:

Similarly to the degree of hepatosteatosi, increases in body mass index, liver size, liver enzyme levels and blood lipid levels were statistically significant ($p < 0.05$). While the difference in portal vein peak velocity in the hepatosteatosi and control groups was not statistically significant, there was an increasing reduction in the degree of steatosi ($p > 0.05$). As the degree of hepatosteatosi increased, there was a reduction in hepatic artery flow volume, portal vein flow volume and total flow volume that was not statistically significant. In the mild hepatosteatosi group, hepatic artery RI and PI values were statistically significantly lower than in the other groups ($p < 0.05$). In the severe hepatosteatosi group, although the hepatic artery RI and PI values were not statistically significant, there was a minimal increase compared to the other groups.

Conclusions:

It is believed that those results were caused by a reduction in liver compliance and hepatic vascular compliance, in addition to resistance increase in vascular structures.

MeSH Keywords:

Hepatic Artery • Portal Vein • Ultrasonography, Doppler, Color

PDF file:

<http://www.polradiol.com/abstract/index/idArt/890608>

Background

Hepatosteatosi, fattening of the liver, is a pathology defined as more than 5% fat in the liver [1]. With a silent clinical tableau the main causes of hepatosteatosi are alcohol, diabetes mellitus (DM), obesity, medications, toxins, hyperlipidemia and hepatitis. Its observed frequency, especially related to obesity, is increasing. While the early-stage hepatosteatosi does not cause serious problems, without treatment the increasing severity may lead to inflammation (steatohepatitis) and in the late stages, cirrhosis [2].

Hepatosteatosi, a reversible condition, is definitively diagnosed by histopathology, but in daily practice it can be diagnosed by radiology with high accuracy. Ultrasonography (USG), computed tomography (CT) and magnetic resonance imaging (MRI) can be used. On CT, liver parenchyma density is significantly lower than spleen parenchyma and on MRI the chemical shift method can be used to measure fat content. As USG is non-invasive, cheap and repeatable, it is widely used to diagnose hepatosteatosi and other liver diseases. Hepatosteatosi on USG is indicated by increased parenchymal echogenicity, loss of gloss on vein walls and washout, and increase in sound

attenuation leading to no visualization of the posterior sections of the liver. Using these results, three groups can be identified; mild, moderate and severe [3]. USG also allows hemodynamic measurements of vascular structures, which is not possible with other techniques. Doppler USG can be used to examine the flow patterns in the main vascular structures of the liver; the portal vein, hepatic vein and hepatic artery. In this regard, spectral investigations using Doppler USG can provide important information.

In the literature, studies on hepatosteatosis and hemodynamic changes it causes in vascular structures of the liver focus on changes in hepatic vein flow forms and on flow parameters of the hepatic artery. It is reported that the normal triphasic flow form in hepatic veins becomes monophasic due to reduction of hepatic compliance in steatosis [4]. Again, due to similar effects of steatosis, there is a compensatory increase in hepatic arterial flow due to pressure on portal triad structures, and resistivity index (RI) decrease [5].

This study aimed to evaluate possible hepatic artery (HA) and portal vein (PV) flow changes in hepatosteatosis patients using Doppler USG.

Material and Methods

This study was prospectively planned. Permission was granted for the study by an ethics committee. Patients above the age of 18 with hepatosteatosis diagnosed by USG with no pathology of the hepatobiliary system, other than hepatosteatosis, were included in the study. Patients with conditions that may affect hemodynamic measurements, such as mass in the liver, cirrhosis, heart failure, hypertension and chronic renal failure, were not included in the study. The control group comprised people without hepatosteatosis or any known illness. People below the age of 18 were not included in the study. As hemodynamic changes in liver vascular structures are known after eating, 8 hours of fasting were required before examination. Ultrasonography examinations were performed with a General Electric Logiq 9 device with a 3.5 MHz convex probe. Patients in the supine position were examined from subcostal or intercostal approaches. On the midclavicular line in the sagittal plane, the craniocaudal size of the liver was measured. After hepatosteatosis diagnosis was confirmed, the degree of hepatosteatosis was classified as mild (grade I), moderate (grade II) or severe (grade III) using USG data.

Patients with a slight increase in the diffusion of liver echogenicity, with normal echogenicity of the diaphragm and intrahepatic vein walls were classified as grade I hepatosteatosis. Increased liver echogenicity, with minimal washout of intrahepatic vein walls and diaphragm echogenicity were evaluated as grade II hepatosteatosis. Patients with a definite increase in liver echogenicity with posterior segments of the liver not clearly visible and intrahepatic vein walls and diaphragm partly or fully obscured were classified as grade III hepatosteatosis.

After hepatosteatosis investigation was completed, portal vein and hepatic artery were examined using color duplex

Doppler. Patients were examined in supine or left lateral decubitus position. A 3.5 MHz convex probe was used. Vascular structures were investigated with gray scale, color Doppler and spectral Doppler USG.

Portal vein between splenoportal junction and intrahepatic bifurcation was visualised as an anechoic tubular structure on gray-scale images. On color Doppler, the lumen was fully filled with homogeneous color and flow direction was towards the liver. On spectral exam the sample window was located in the center of the lumen. The flow cursor was placed parallel to the portal flow. While the portal flow was examined, the angle was held between 30–60 degrees. For that reason, the majority of patients were examined in the left lateral decubitus position. As portal vein flow reflects the respiratory phase, flow measurements were made while the patients held their breath.

After the patient inhaled and held their breath, the flow spectrum was examined and images were frozen to measure and record portal vein diameter, velocity, and flow volume.

The hepatic artery was examined by Doppler USG after deep inspiration, in right intercostal or subcostal direction. The diameter of the hepatic artery is much smaller than of the portal vein and due to anatomic variations, it was difficult to observe in some patients. The majority of examinations showed the hepatic artery anterior and slightly diagonal to the portal vein on a 30–60-degree angled image. On spectral examination, at least three consecutive wave forms were used to measure hepatic artery diameter, peak systolic speed, end diastolic speed, RI, PI, and flow volume.

After USG examination was complete, the patients' height and weight were measured and body mass index (BMI) was calculated.

SPSS 13.0 and Minitab 14.12 programs were used for analyses in this study. Continuous variables were given as mean, standard deviation, minimum and maximum values; categorical variables were given as frequency and percentages. Normal distribution of variables was tested with the Shapiro-Wilk test. Comparison of normally distributed variables in 3 or more groups was completed with one-way analysis of variance (ANOVA). Paired comparisons used the post-hoc test. Variables not compliant with parametric tests were compared using the Mann-Whitney U test for paired comparisons and Kruskal Wallis test for 3 or more group comparisons. Relationships between continuous variables were interpreted using the Spearman correlation coefficient. A p value of less than 0.05 was accepted as significant.

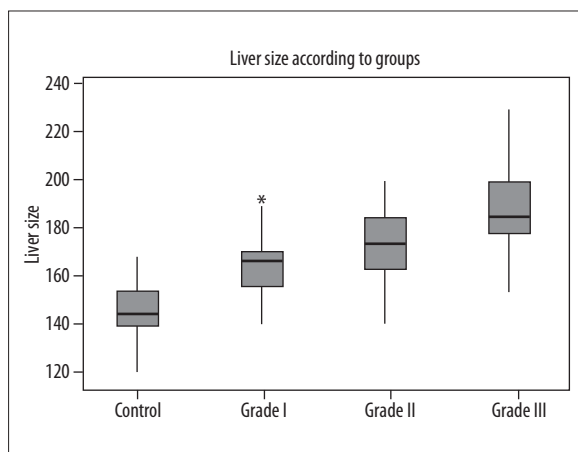
Results

A total of 120 cases were evaluated. The control group of 30 healthy people without hepatosteatosis, and other groups of mild (grade I), moderate (grade II) and severe (grade III) hepatosteatosis, comprised 30 patients in each group. The control group comprised 9 males and 21 females between the age of 18 and 61; grade I hepatosteatosis group included 12 males and 18 females between the age of 25 and 74; grade II hepatosteatosis group included 11 males and 19 females between the age of 26 and 67 while

Table 1. Mean liver size, BMI and portal vein peak velocity values according to groups and relevant p values.

Variables	Group 1 (Control group)	Group 2 (Grade I hepatosteatosi)	Group 3 (Grade II hepatosteatosi)	Group 4 (Grade III hepatosteatosi)	p value*
Liver size	147.12±10.5	165.17±12.6	173.0±15.2	189.17±17.7	0.001
BMI	24.42±3.9	30.57±6.9	30.6±6.0	36.17±7.0	0.002
Portal vein peak velocity	43.32±16.9	39.03±13.0	40.50±13.7	35.5±12.15	0.309

BMI – body mass index. Data were given as mean ± standard deviation. * Kruskal-Wallis test.

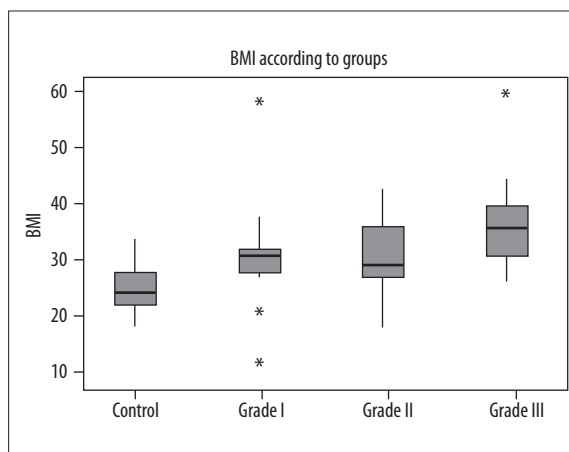
**Figure 1.** Liver size according to groups.

the grade III hepatosteatosi group included 8 males and 22 females between the age of 23 and 79.

Liver size was examined using ultrasonography and mean values were calculated for each group (Table 1). When the groups were compared with each other, statistically significant differences were found ($p=0.001$). As the degree of hepatosteatosi increased, the liver size increased (Figure 1). Mean BMI was calculated for each group (Table 1). When comparing the groups with each other, a statistically significant difference was found ($p=0.002$). As the degree of hepatosteatosi increased, BMI increased as well (Figure 2). In the correlation analysis, liver size and BMI were positively correlated with hepatosteatosi ($r=0.605$).

The liver enzymes and blood lipid profiles of all subjects in the study were examined. ALT and AST values for liver enzymes were measured. For blood lipids, total cholesterol, triglycerides (TG), LDL and HDL values were also measured. Mean values were calculated for the groups and compared with the control group and themselves. There was a significant increase in liver enzymes and total cholesterol in blood with increase in the degree of hepatosteatosi ($p<0.05$). There was an increase in LDL levels with the degree of hepatosteatosi at the limit of significance ($p=0.05$). As hepatosteatosi degree increased, there was an increase in TG levels that was not statistically significant ($p=0.105$). As hepatosteatosi degree increased, there was a significant decrease in HDL levels ($p<0.05$).

While portal vein peak velocity measured on Doppler USG was not significant between the groups, there was

**Figure 2.** Body mass index (BMI) according to groups.

a decrease with increase in the degree of hepatosteatosi ($p=0.305$) (Table 1).

Between the groups there were no significant statistical differences in hepatic artery flow volume ($p=0.479$), portal vein flow volume ($p=0.415$), total hepatic flow volume ($p=0.297$) and hepatic perfusion index ($p=0.912$). Between the groups there was a statistically significant difference in hepatic artery RI ($p=0.043$) and hepatic artery PI ($p=0.034$) (Table 2).

When we compared hepatic artery (HA) RI and PI values in Group 2 (grade I hepatosteatosi) and Group 1 (control); we observed a reduction that was not statistically significant. Comparing HA RI and PI values in Group 3 (grade II hepatosteatosi) and Group 4 (grade III hepatosteatosi) with Group 1 (control), there was an increase that was not statistically significant. To identify paired groups where HA RI and PI values were significant, groups were compared using the Mann-Whitney U test. Results indicated a significant increase between Group 2 and Group 3 (HA RI $p=0.014$; HA PI $p=0.038$), and between Group 2 and Group 4 (HA RI $p=0.035$; HA PI $p=0.010$) with increase in the degree of hepatosteatosi (Table 3).

Discussion

Definitive diagnosis of hepatosteatosi requires histopathology. Pathologically, hepatosteatosi is defined as liver fat ratio greater than 5%, but in daily practice it is mainly diagnosed incidentally or while testing increases of the liver enzyme level using USG. In a study comparing

Table 2. Doppler ultrasonographic parameters according to groups and relevant *p* values.

Variables	Group 1 (Control group)	Group 2 (Grade I hepatosteatosi)	Group 3 (Grade II hepatosteatosi)	Group 4 (Grade III hepatosteatosi)	<i>p</i> value*
Portal vein flow volume	925.7±411	1001.1±494	929.6±381	796.7±268	0.415
Hepatic artery flow volume	177.9±105.8	190.2±129.3	188.7±127.7	134.5±58.1	0.479
Total flow volume	1103.7±431.3	1191.3±577.2	1118.4±412.6	931.3±266.7	0.297
Hepatic perfusion index	0.825±0.103	0.838±0.08	0.825±0.094	0.845±0.075	0.912
Hepatic artery RI	0.628±0.108	0.622±0.068	0.669±0.071	0.668±0.722	0.043
Hepatic artery PI	1.138±0.406	1.092±0.224	1.229±0.264	1.290±0.310	0.034

RI – resistivity index; PI – pulsatility index. Data were given as mean ± standard deviation. * Kruskal-Wallis test.

Table 3. Mean hepatic artery RI and PI values according to groups and relevant *p* values for double-group comparisons.

	Hepatic artery RI	<i>p</i> value*	Hepatic artery PI	<i>p</i> value*
Group 1 Group 2	0.623±0.11 0.622±0.11	0.896	1.138±0.41 1.092±0.22	0.902
Group 1 Group 3	0.623±0.11 0.669±0.07	0.087	1.138±0.41 1.229±0.26	0.107
Group 1 Group 4	0.623±0.11 0.668±0.72	0.090	1.138±0.41 1.290±0.31	0.051
Group 2 Group 3	0.622±0.11 0.669±0.07	0.014	1.092±0.22 1.229±0.26	0.038
Group 2 Group 4	0.622±0.11 0.668±0.72	0.035	1.092±0.22 1.290±0.31	0.010
Group 3 Group 4	0.669±0.07 0.668±0.72	0.804	1.229±0.26 1.290±0.31	0.640

RI – resistivity index; PI – pulsatility index. Data were given as mean ± standard deviation. * Kruskal-Wallis test.

histopathological results with USG, USG had 77% specificity, 88% sensitivity, 77% positive predictive and 67% negative predictive values [6]. As the amount of fattening increased, USG sensitivity increased [7,8].

Hepatosteatosi may cause a wide spectrum of pathologies, from simple fattening, steatohepatitis with accompanying inflammation, and at advanced stages, cirrhosis that may result in hepatocellular carcinoma [9].

When diagnosing portal hypertension, a frequent complication of cirrhosis, the safe, highly accurate, non-invasive, easily repeated technique of Doppler USG may be used [10]. Hepatosteatosi is known to be a parenchymal pathology of the liver and may progress to cirrhosis. In this study, the use of Doppler USG in hepatosteatosi monitoring, similar to the one used in chronic hepatitis and cirrhosis, was researched.

In this study 120 subjects between the age of 18 and 79 were examined. Four groups of 30 subjects, normal (control) or with mild, moderate, and severe hepatosteatosi,

were created and compared. When comparing groups in terms of liver size and BMI, there was a difference in mean values and that difference was statistically significant. As the degree of hepatosteatosi increased, there was a significant increase in the liver size and body mass index. Additionally, correlation between BMI and liver size turned out to be statistically significant ($r=0.605$).

Liver enzymes and blood lipid values were measured and compared for all subjects. ALT, AST, TG, total cholesterol and LDL showed significant increases with increasing degree of hepatosteatosi. TG values increased with the degree of hepatosteatosi, but that was not statistically significant. HDL values showed a statistically significant decrease as the degree of hepatosteatosi increased.

Portal vein flow revealed a biphasic pattern and was affected by e.g. respiration or hunger/satiation. In previous studies, examinations were carried out during normal respiration, whereas in our study, patients held deep inspiration breath during the examination. In this way, monophasic flow was created in the portal vein and we were able to

prevent fluctuations due to respiration. We believe that thanks to that, more accurate measurements were provided.

When comparing the portal vein peak velocity between the control group and hepatosteatosi groups and between the hepatosteatosi groups, we found a reduction (though statistically insignificant) linked to the degree of steatosis ($p > 0.05$). In an MRI study of 35 hepatosteatosi patients and 29 controls, Ulasan et al. used Doppler USG for examinations and found a significant proportional reduction in portal vein velocity in the hepatosteatosi group compared to the control group [11].

Solhjo et al. studied 31 patients with hepatosteatosi, some diagnosed histopathologically, and 31 controls using Doppler USG to measure portal vein mean velocity. There was a significant decrease in portal vein mean velocity in the hepatosteatosi group [12].

In a study of 60 obese and 20 healthy adults, Erdogmus et al. found a significant reduction in portal vein mean flow velocity, portal vein peak velocity and portal vein minimum velocity in patients with a fatty liver and concluded that, this was due to vascular compliance reduction as a result of fat infiltration into the liver [13].

Balci et al. divided 140 patients into 4 groups based on BMI and found that, independent of BMI, there was an inverse correlation between degree of fat infiltration and both portal venous PI and portal vein mean velocity values. They concluded that this was caused by reduced parenchymal and vascular compliance. Additionally they proposed that limits on the expansion of the liver capsule and increased volume of hepatocytes due to fattening may cause venous compression [14].

Mohammadi et al. studied 160 patients grouped as mild, moderate or severe hepatosteatosi and controls. They compared portal vein peak velocity and mean velocity with hepatic artery RI and hepatic vein phasicity. There was an inverse correlation between hepatic flow parameters and the degree of fattening, and as the degree of hepatosteatosi increased there was a reduction in the parameters [15].

In the current study, comparing portal vein flow volume, HA flow volume, total flow volume (portal vein flow volume + HA flow volume) and hepatic perfusion index (hepatic arterial flow volume/total hepatic flow volume) between control and hepatosteatosi groups and between hepatosteatosi groups, showed no statistically significant differences ($p > 0.05$). HA flow volume, portal vein flow volume and total flow volume were increased in grade I and grade II hepatosteatosi groups compared to controls, but that was not statistically significant. When comparing the grade III hepatosteatosi group with the control group, we found a reduction that was not statistically significant. As the severity of fattening increases, the hepatocyte volume increase may put pressure on vascular structures causing a reduction in flow volume. This may also be due to reduced parenchymal and vascular compliance. Studies in the literature have concluded that as the degree of hepatosteatosi increases, flow volume decreases [16,17].

Magalotti et al. evaluated patients with non-alcoholic fatty liver disease confirmed by biopsy, and found that after 6 months of diet and pharmacological treatment, liver echogenicity recovered, liver volume significantly decreased, and portal vein flow and discharge significantly increased. They reported that B-mode and Doppler USG could be used for observation and monitoring of hepatosteatosi treatment [18].

Hepatosteatosi affects the portal vein earlier than the arterial system, causing reduction in portal flow and portal flow volume. To compensate for this reduction, hepatic artery flow volume increases. As the degree of fattening increases, the compensatory situation ceases and arterial flow is affected, causing a reduction in arterial flow, though not to the extent of the reduction in portal volume. In hepatosteatosi, as the degree of steatosis increases, the hepatic perfusion index increases [17]. In our study, when hepatic perfusion index values were compared between the control and hepatosteatosi groups and between the hepatosteatosi groups, no statistically significant difference was observed ($p > 0.05$). However, while not statistically significant, an increase in hepatic perfusion index values was observed in the hepatosteatosi group compared to the control group. Kakkos et al. evaluated 41 obese patients and 18 volunteers, and found out that the hepatic perfusion index was significantly higher in the obese group when compared to controls. Additionally, they recorded a positive correlation between that index and serum AST and TG levels [17].

In our study, there was a significant difference in HA RI and PI between the groups (Table 2). Comparisons within the groups were made to identify which group caused the difference: grade I hepatosteatosi patients had lower RI and PI values than the other groups, and the difference was due to that group. Between the other groups and the control group, no difference was noticed. Similar studies in the literature have found that as the degree of hepatosteatosi increased, HA RI and PI values decreased [18]. However, we did not observe this in our trial. The only reduction in RI and PI values, though not significant, was found between grade I hepatosteatosi and control groups. In addition to those results, although not statistically significant, there was a minimal increase in hepatic artery RI and PI values in the severe steatosis group, when compared to the other groups. This contradicts the data in the literature. It is thought that this increase may be caused by an increase in the resistance within vascular structures in the liver linked to hepatosteatosi.

Mohammadinia et al. in a study of 80 subjects in mild, moderate and severe hepatosteatosi group and a control group, used color Doppler and spectral Doppler USG to examine HA RI. There was a significant reduction in HA RI values as the degree of hepatosteatosi increased [18]. Mihmanli et al. reported a correlation between increased degree of steatosis and reduction in HA RI values. They argued that fat infiltration caused compression of the portal triad structures. That infiltration affected the portal vein earlier, and caused a reduction in portal flow, which led to increased compensatory HA diastolic flow, causing RI to decrease [19].

Conclusions

In conclusion, hepatosteatosis is a pathology of the parenchyma of the liver that may advance to cirrhosis. Thus it requires monitoring. Hepatosteatosis causes hemodynamic changes in the liver, namely hepatic vascular compliance

reduction and resistance increase in vascular structures. These hemodynamic changes which vary with the degree of steatosis can be identified with Doppler USG. Therefore, Doppler USG can be used for monitoring and follow-up of hepatosteatosis.

References:

1. Bass NN: Toxic and Drug-Induced Liver Disease. In: Bennett JC, Plum F: Cecil Textbook of Medicine. W.B. Saunders Company, Philadelphia, 1996; 772-76
2. El Hassan AY, Ibrahim EM et al: Fatty infiltration of the Liver: Analysis of prevalence, radiological and clinical features and influence on patient management. *Br J Radiol*, 1992; 65: 774-78
3. Gore RM: Diffuse liver disease. In: Gore RM, Levine MS, Laufer I (eds.), *Textbook of Gastrointestinal Radiology*. Philadelphia: Saunders, 1994; 1968-2017
4. Gazelle GC, Lee MJ, Mueller PR: Cholangiographic segmental anatomy of the liver. *Radiographics*, 1994; 14: 1005-13
5. Sherlock S, Dooley J: Anatomy and Function. Sherlock S, Dooley J. (editors) *Diseases of the Liver and Biliary System* 11th Edition. Oxford: Blackwell Science Ltd., 1997: 1-15
6. Van Leeuwen DJ: Liver biopsy: who should do it and who will show up in court? *Am J Gastroenterol*, 2002; 97: 1285-88
7. Tchelepi H, Ralls PW, Radin R et al: Sonography of diffuse liver disease. *J Ultrasound Med*, 2002; 21: 1023-32
8. Saadeh S, Younossi ZM, Remer EM et al: The utility of radiological imaging in nonalcoholic fatty liver disease. *Gastroenterology*, 2002; 123: 745-50
9. Ong JP, Younossi ZM: Approach to the diagnosis and treatment of nonalcoholic fatty liver disease. *Clin Liver Disease*, 2005; 9: 617-34
10. Ohnishi K, Saito M, Nakayama T et al: Portal venous hemodynamics in chronic liver disease: effects of posture change and exercise. *Radiology*, 1985; 155: 757-61
11. Ulsan S, Yakar T, Koc Z: Evaluation of portal venous velocity with Doppler ultrasound in patients with nonalcoholic fatty liver disease. *Korean J Radiol*, 2011; 12: 450-55
12. Solhjo E, Mansour-Ghanaei F, Moulaei-Langorudi R et al: Comparison of portal vein Doppler indices and hepatic vein Doppler waveform in patients with nonalcoholic Fatty liver disease with healthy control. *Hepat Mon*, 2011; 11: 740-44
13. Erdogmus B, Tamer A, Buyukkaya R et al: Portal Vein Hemodynamics in Patients with Non-Alcoholic Fatty Liver Disease. *Tohoku J Exp Med*, 2008; 215: 89-93
14. Balci A, Karazincir S, Sumbas H et al: Effects of Diffuse Fatty Infiltration of the Liver on Portal Vein Flow Hemodynamics. *J Clin Ultrasound*, 2008; 36: 134-40
15. Mohammadi A, Ghasemi-rad M, Zahedi H et al: Effect of severity of steatosis as assessed ultrasonographically on hepatic vascular indices in non-alcoholic fatty liver disease. *Med Ultrason*, 2011; 13: 200-6
16. Magalotti D, Marchesini G, Ramilli S et al: Splanchnic hemodynamics in nonalcoholic fatty liver disease: effect of a dietary/pharmacological treatment. A pilot study. *Dig Liver Dis*, 2004; 36: 406-11
17. Kakkos SK, Yarmenitis SD, Tsamandas AC et al: Fatty liver in obesity: Relation to Doppler perfusion index measurement of the liver. *Scand J Gastroenterol*, 2000; 35: 976-80
18. Mohammadinia AR, Bakhtavar K, Ebrahimi-Daryani N et al: Correlation of hepatic vein Doppler waveform and hepatic artery resistance index with the severity of nonalcoholic fatty liver disease. *J Clin Ultrasound*, 2010; 38: 346-52
19. Mihmanli I, Kantarci F, Yilmaz MH et al: Effect of diffuse fatty infiltration of the liver on hepatic artery resistance index. *J Clin Ultrasound*, 2005; 33: 95-99