

Received: 2015.11.27
Accepted: 2016.01.28
Published: 2016.09.07

Comparison of Surgical Outcomes Between Short-Segment Open and Percutaneous Pedicle Screw Fixation Techniques for Thoracolumbar Fractures

Authors' Contribution:
Study Design A
Data Collection B
Statistical Analysis C
Data Interpretation D
Manuscript Preparation E
Literature Search F
Funds Collection G

ABCDE 1 **Zhiguo Fu***
B 2 **Xi Zhang***
BC 2 **Yaohua Shi**
E 1 **Qirong Dong**

1 Department of Orthopaedics, The Second Affiliated Hospital of Soochow University, Suzhou, Jiangsu, P.R. China
2 Department of Orthopedics, The Changzhou Hospital of Traditional Chinese Medicine, The Affiliated Hospital of Nanjing University of Chinese Medicine, Changzhou, Jiangsu, P.R. China.

* These authors contributed equally to this work
Qirong Dong, e-mail: qdong_su2015@163.com
Departmental sources

Corresponding Author:
Source of support:

Background: This study aimed to compare the surgical outcomes between open pedicle screw fixation (OPSF) and percutaneous pedicle screw fixation (PPSF) for the treatment of thoracolumbar fractures, which has received scant research attention to date.





Material/Methods: Eight-four patients with acute and subacute thoracolumbar fractures who were treated with SSPSF from January 2013 to June 2014 at the Changzhou Hospital of Traditional Chinese Medicine (Changzhou, China) were retrospectively reviewed. The patients were divided into 4 groups: the OPSF with 4 basic screws (OPSF-4) group, the OPSF with 4 basic and 2 additional screws (OPSF-6) group, the PPSF with 4 basic screws (PPSF-4) group, and the PPSF with 4 basic and 2 additional screws (PPSF-6) group. The intraoperative, immediate postoperative, and over 1-year follow-up outcomes were evaluated and compared among these groups.

Results: Blood loss in the PPSF-4 group and the PPSF-6 group was significantly less than in the OPSF-4 group and the OPSF-6 group ($P < 0.05$). The OPSF-6 group exhibited significantly higher immediate postoperative correction percentage of anterior column height of fractured vertebra than the other 3 groups ($P < 0.05$), and higher correction of sagittal regional Cobb angle and kyphotic angle of injured vertebra than in the PPSF-4 and -6 groups ($P < 0.05$). In addition, there was no significant difference in the correction loss of percentage of anterior column height, and loss of sagittal Cobb angle and kyphotic angle of fractured vertebrae at final follow-up among the 4 groups ($P > 0.05$).

Conclusions: OPSF with 6 screws had an advantage in the correction of injured vertebral height and kyphosis, and PPSF reduced the intraoperative blood loss of patients.

MeSH Keywords: **Conversion to Open Surgery • Internal Fixators • Spinal Fractures • Surgical Procedures, Minimally Invasive**

Full-text PDF: <http://www.medscimonit.com/abstract/index/idArt/896882>

 3692  2  1  25



Background

Thoracolumbar fracture accounts for 50–74% of spinal injuries [1]. Although for some patients with thoracolumbar fractures without neurologic deficit, non-operative treatments obtain good clinical outcomes [2,3], short-segment pedicle screw fixation (SSPSF) without fusion is widely adopted as a more effective treatment means by stabilizing the fractures, correcting spinal kyphotic deformity, and restoring the height of injured vertebra, which thus maintains good functional outcomes [4–11]. Open pedicle screw fixation (OPSF), a type of SSPSF, is a conventional technique for the treatment of thoracolumbar fractures. OPSF with the 4 basic screws is widely used in the management of thoracolumbar fractures, while the loss of vertebral column height and kyphotic angel, as well as the loosening and breakage of the pedicle screws after the surgery, are still challenging issues [12–14]. Two additional screws for OPSF in the fractured vertebra body are reported to improve the construct stiffness and flexion stability, thereby producing better outcomes (e.g., recovering and maintaining the vertebral height, correcting kyphosis) and reducing complications (e.g., the incidence of screw pullout, instrumentation failure, worsening of spinal kyphosis after surgery, and progressive deformity) [15–20].

Recently, to reduce the adverse effects associated with the conventional open approaches, such as iatrogenic muscle denervation and pain, percutaneous pedicle screw fixation (PPSF) systems have been introduced in the treatment of spinal fractures, which involve 4 basic percutaneous pedicle screws in the vertebra above and below the injury level (for PPSF-4 screw fixation) and 2 additional percutaneous pedicle screws in the fractured vertebrae (for PPSF-6 screw fixation) [21–23]. It has been shown that, compared with OPSF, PPSF produces significantly better outcomes, such as less intraoperative blood loss, shorter surgical time, and less postoperative pain, but does not still exhibit significant advantages in the correction of vertebral body angles or Cobb angles during follow-up [11,21–23].

Few studies have compared the efficacies of PPSF and OPSF for thoracolumbar fractures [24]. In the present study, we retrospectively compared the efficacy of OPSF (with 4 or 6 screws) and PPSF (with 4 or 6 screws) for the treatment of patients with thoracolumbar fractures at the Changzhou Hospital of Traditional Chinese Medicine, Changzhou, China.

Material and Methods

Patients

Ninety-eight patients with thoracic or lumbar vertebral fractures who underwent surgical management through posterior

transpedicular screw fixation between January 2013 and June 2014 at the Changzhou Hospital of Traditional Chinese Medicine were primarily retrospectively reviewed. Patient inclusion criteria were: 1) acute or subacute thoracolumbar fracture (T10–L2) at a single level; 2) interval from injury to surgery within 72 h for acute thoracolumbar fractures, and interval within 4–14 days for subacute thoracolumbar fractures; and 3) follow-up period of more than 12 months. We excluded patients with severe osteopenia (defined as bone mineral density [BMD] t score <–2.5), pathologic fractures, spinal cord or cauda equina injury, or those who previously received spine surgery due to trauma. Eighty-four cases were finally included in this study. The study was approved by the Ethics Committee of Changzhou Hospital of Traditional Chinese Medicine.

All patients underwent postero-anterior and lateral X-ray examination, computed tomography (CT) scan (including CT in combination with a 3-dimensional reconstruction in some cases), BMD measurement, and magnetic resonance imaging (MRI) examination to determine the types of fractures. Fracture types were determined by Denis classification system [25]. Patients were classified into the OPSF-4 group (14 cases, treated by OPSF with 4 basic screws), the OPSF-6 group (41 cases, treated by OPSF with 4 basic and 2 additional screws), the PPSF-4 group (16 cases, treated by PPSF with 4 basic screws), and the PPSF-6 group (13 cases, treated by PPSF with 4 basic and 2 additional screws).

Surgical procedure

All surgical procedures were performed under general anesthesia. Patients were placed in hyperextension in the prone position with abdomen hanging free through a bolster set under the chest and iliacs. The pedicles of the fractured vertebra and those of the vertebra above and below the injury level (referred as upper and lower vertebra, respectively) were positioned by C-arm X-ray examination, and were then marked on the corresponding skin. Pressure was then applied to the spinous process of the fractured vertebra with Denis Type I and II.

In OPSF-4 or -6 screw fixation, the spine was exposed through a routine posterior midline approach. According to the approximate normal sagittal spinal curvature of the fracture region, the rods were pre-flexed. After inserting, the pedicle screws were positioned by C-arm X-ray examination, and were then fixed with rods. Finally, 1–2 drainage tubes were placed in the suction. For OPSF-4 technique, 4 monoaxial screws (Wego Holding Co., Weihai, China) were inserted into the upper and lower vertebra. Prior to cephalic distraction with a reducing tool, the locking nuts of the lower vertebral pedicle screws were tightened, followed by distraction; the locking nuts of the upper vertebral screws were subsequently tightened. For OPSF-6 screw technique, in addition to the 4 basic monoaxial screws into the

upper and lower vertebra, 2 short monoaxial or polyaxial pedicle screws (Wego Holding Co., Weihai, China) were inserted into the fractured vertebra. For fractures of Denis Type IA and IIA, the locking nuts of pedicle screws in the fractured vertebra were tightened first, followed by the cephalic and caudalis distraction, respectively. Thereafter, the locking nuts screws in the upper and lower vertebra were tightened. For other Denis types of fractures, the locking nuts of pedicle screws in fractured vertebra and those in the lower vertebra were tightened first, followed by the cephalic distraction, after which the locking screw nuts in the upper vertebra were tightened.

In PPSF-4 or -6 screw fixation, the skin was incised approximately 2 cm along the directions of 3 o'clock (left) and 9 o'clock (right) with reference to the above skin marker of pedicles. Lumbodorsal fascia was then shorn. Under the C-arm guidance, the needle was passed through the pedicle into the vertebral body, whereby a guide wire was then inserted into the vertebral body. The dilation tubes were gradually placed through the guide wire, and the last one was withheld. Pedicles advancing to the junctions between the pedicles and vertebral body were tapped for screw insertion; the hollow pedicle screws were then inserted into the pedicles and vertebral body. Finally, the guide wire and dilation tubes were removed. Neither cross-linking nor drainage was involved. For PPSF-4 technique, the monoaxial hollow pedicle screw system (Wego Holding Co.) was used in 8 patients, where the rods were pre-flexed according to the approximate normal sagittal spinal curvature of the fracture region. The procedures of distraction and fixation were similar to those of the OPSF-4 group. The polyaxial hollow pedicle screw system (Medtronic, Inc., Minneapolis, MN) was used in another 8 patients, where the rods did not need to be pre-flexed and polyaxial screws could not carry out distraction. For PPSF-6 screw technique, the procedures of pre-flexing of rods, distraction, and fixation were similar to those of OPSF-6 screw technique. The monoaxial hollow pedicle screws were inserted into the upper and lower vertebra, and 2 short polyaxial hollow pedicle screws were additionally inserted into the fractured vertebra.

Postoperative treatment

After the OPSF-4 or -6 screw surgery, the drainage tubes were removed when the drainage volume was less than 50 ml within 24 h. For all the patients, the postero-anterior and lateral X-ray examination and CT scan (including CT in combination with 3-dimensional reconstruction in some cases) were performed routinely. All patients except those with fractures in the pelvis or lower limb were encouraged get be out of bed to walk with a lumbar bracing starting on the third postoperative day, and the bracing was kept for up to 3 months. Lumbar bending was forbidden during the first 3 months. The implants were allowed to be removed at 12 months after surgery.

Radiographic measurement

The reference anterior column height of the fractured vertebra was defined as half of the sum of the heights of upper and lower vertebra. The anterior column height percentage of fractured vertebra was calculated as the ratio of the actual height of the fractured vertebra to the reference anterior column height. Sagittal region Cobb angle was calculated as the angle between the upper vertebral superior endplate and lower vertebral inferior endplate of the fractured vertebra. Correction value was the immediate postoperative value minus preoperative value, and the correction loss value was the immediate postoperative value minus the final follow-up value.

Follow-up

All the patients were followed-up for 12–31 months and had postero-anterior and lateral X-ray examinations at 6 weeks, 3 months, 6 months, and 12 months after the operation. The anterior column height, sagittal regional Cobb angle, and kyphotic angle of the fractured vertebra were measured on the lateral X-ray views before and immediately after the surgery, as well as at the final follow-up, using a picture-archiving and communication system (Jiangsu Sesan Technology Co., Changzhou, China). The placement of the implanted pedicle screws and anatomical morphology of the fractured vertebra were observed by postoperative CT.

Statistical analysis

Data are presented as the mean \pm standard deviation, and analyzed using the SPSS software for Windows V13.0 (SPSS Inc., Chicago, IL, USA). The χ^2 test was used to compare the sex distribution among the groups. One-way analysis of variance and the following SNK-q test (equal variances) were used to compare the operation time; pain visual analogue scale (VAS) on the operation day; immediate postoperative correction percentage of the anterior column height, and correction of sagittal regional Cobb angle and kyphotic angle of injured vertebra; and correction loss of percentage of anterior column height, and sagittal regional Cobb angle at the last follow-up between the 4 groups. In addition, for the comparison of the intraoperative blood loss, postoperative drainage, and correction loss of injured vertebral kyphotic angle at final follow-up among the 4 groups, the Dunnett T3 test (unequal variances) was used. *P* value <0.05 was considered statistical significance for all the tests.

Table 1. Patients' basic characteristics.

	OPSF-4 group (n=14)	OPSF-6 group (n=41)	PPSF-4 group (n=16)	PPSF-6 group (n=13)	F/ χ^2 value	P value
Age (mean/range, years)	44.8 (26–64)	47.9 (22–77)	50.5 (21–67)	48.6 (31–61)	0.873	0.459
Gender (male/%)	9 (64.3%)	17 (41.5%)	8 (50%)	8 (69.2%)	3.030	0.387
Injury mechanisms						
Falling from height	5	15	4	1		
Traffic accident	4	13	5	5		
Tumbling			7			
Dropping down				7		
Impacted by hard objects	1					
Injured spinal level						
T11	1		1			
T12		1	4	4		
L1	6	24	8	5		
L2	7	16	3	4		
Denis classification						
Type I	7	8	1	6		
Type II	6	17	14	7		
Type III	1	3	1			
Preoperative duration (days)	5.2±2.0 (3–8)	5.2±2.2 (1–11)	4.6±1.6 (3–9)	5.1±2.5 (2–10)	0.289	0.833
Preoperative percentage of anterior column height of fractured vertebra (%)	68.8±11.3	66.1±13.6	67.3±10.8	69.0±10.9	1.873	0.141
Preoperative sigmoidal regional Cobb angle (°)	9.2±5.9	12.1±6.3	14.3±6.9	9.9±4.0	1.979	0.124
Preoperative injured vertebral kyphotic angle (°)	16.8±5.9	17.5±5.3	14.3±5.5	13.8±4.7	1.913	0.135

P<0.05 represented statistically significance.

Results

Patients' basic characteristics

There were a total of 84 patients (42 males and 42 females). The mean age was 49.4±12.3 years. Basic characteristics assessed were age, sex, injury mechanisms, injured spine levels, preoperative duration (interval between injury and operation), fracture classifications, and preoperative radiological parameters of the fractured vertebra, shown in Table 1.

In addition, the OPSF-4 group had 3 cases with associated injuries, including 1 with left talus fracture, 1 with right pubis fracture and open wound in the right elbow and wrist,

and 1 with soft tissue injury in the left forearm. The OPSF-6 group had 12 cases with associated injuries: 5 with multiple soft tissue injuries, 2 with sacral fractures, 2 with calcaneus fractures, 1 with right acetabular fracture and dislocation in the hip center, 1 with left acetabular fracture, and 1 with mild craniocerebral injury. The PPSF-4 group had 4 cases with associated injuries: 1 with left pubis and iliac fracture and right tibia and fibula fracture, 1 with right acetabular fracture, 1 with multiple soft tissue injuries, and 1 with left foot injury. The PPSF-6 group had 2 cases associated with multiple soft tissue injuries.

There was no significant difference in age, sex, preoperative duration, preoperative percentage of anterior column height,

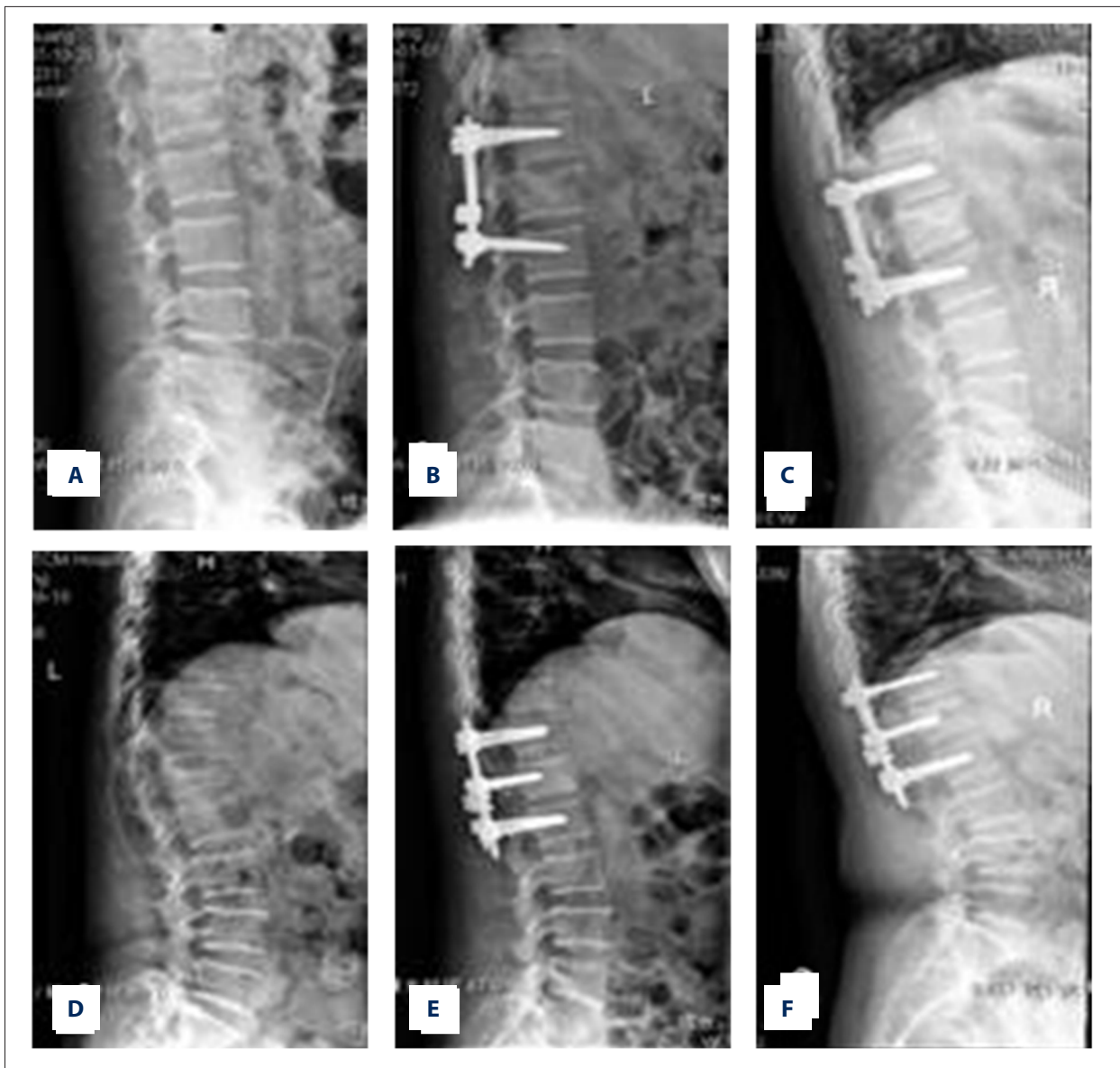


Figure 1A–F. Lateral X-ray radiographs of vertebral fractures of representative patients from OPSF-4, -6, PPSF-6, and -6 screw groups before, immediately after, and 12 months after the surgery. (A–C) Lateral view radiographs of a 47-year-old male patient with Denis type IB vertebral fracture (at L1) in the OPSF-4 group before (A), immediately after (B), and 12 months after the surgery (C). (D–F) Lateral view radiographs of a 57-year-old female patient with type IIB vertebral fracture (at L2) in the OPSF-6 group before (D), immediately after (E), and 12 months after the surgery (F).

preoperative sagittal regional Cobb angle, or kyphotic angle of fractured vertebra among the 4 groups (all $p > 0.05$, Table 1, Figure 1).

Intraoperative and postoperative outcomes

There was no significant difference in operation time or pain VAS on the operation day among the 4 groups ($P > 0.05$). There was a significant difference in the amount of intraoperative blood loss, postoperative drainage, immediate postoperative

correction percentage of anterior column height, correction of sagittal regional Cobb angle, and kyphotic angle of the fractured vertebra among the 4 groups (all $P < 0.05$, Table 2, Figure 1). Further analysis showed that intraoperative blood loss in the PPSF-4 (97.5 ± 27.9 ml) and -6 (110.0 ± 10.7 ml) screw groups was significantly less than in the OPSF-4 (251.4 ± 132.8 ml) and -6 (236.1 ± 123.8 ml) screw groups ($P < 0.05$); however, there was no significant difference between the OPSF-4 and -6 screw groups or between the PPSF-4 and -6 groups ($P > 0.05$, Table 2). There was no significant difference in postoperative drainage

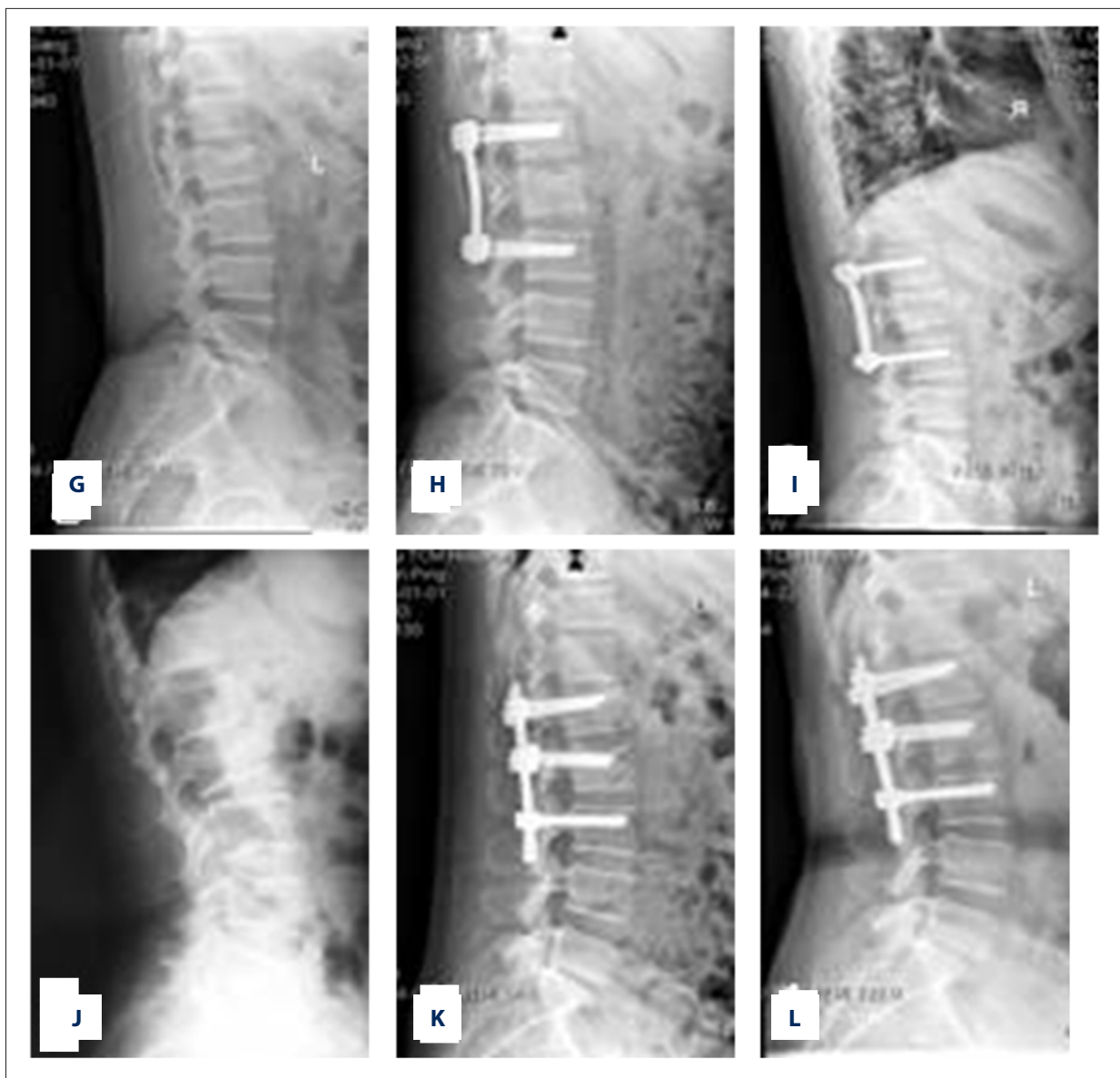


Figure 1G–L. Lateral X-ray radiographs of vertebral fractures of representative patients from OPSF-4, -6, PPSF-6, and -6 screw groups before, immediately after, and 12 months after the surgery. (G–I) Lateral view radiographs of a 45-year-old male patient with type IB vertebral fracture (at L2) in the PPSF-4 group before (G), immediately after (H), and 12 months after the surgery (I). (J–L) Lateral view radiographs of a 51-year-old female patient with type IIB vertebral fracture (at L2) in the PPSF-6 group before (J), immediately after (K), and 12 months after the surgery (L).

between the OPSF-4 (356.4 ± 171.8 ml) and -6 (249.4 ± 156.9 ml) groups ($P > 0.05$), and no drainage was found in the PPSF-4 and -6 groups (Table 2).

The OPSF-6 group exhibited significantly higher immediate postoperative correction percentage of anterior column height of fractured vertebra than the other 3 groups ($P < 0.05$), as well as higher correction of sagittal regional Cobb angle and kyphotic angle of the fractured vertebra than in the PPSF-4 and -6 groups ($P < 0.05$, Table 2). We found no significant difference in

the above parameters among the OPSF-4, PPSF-4, and PPSF-6 groups ($P > 0.05$, Table 2, Figure 1).

Follow-up outcomes

There were no incision infections in any groups. All fractures were healed during the follow-up period. Misplacement was recorded in a few pedicle screws, including 2 pedicle screws with a small converging angle in the OPSF-6 screw group, 1 with perforation of anterior vertebral body, and 1 partly out

Table 2. Comparison of the outcomes between OPSF-4, OPSF-6, PPSF-4 and PPSF-6 screw groups.

	OPSF-4 group (n=14)	OPSF-6 group (n=41)	PPSF-4 group (n=16)	PPSF-6 group (n=13)	F value	P value
Operation time (min)	89.2±18.9	100.7±21.3	88.8±16.4	98.8±18.5	1.641	0.187
Intraoperative blood loss (ml)	251.4±132.8	236.1±123.8	97.5±27.9* [#]	110.0±10.7* [#]		
Pain VAS on operation day	3.6±2.5	4.7±2.2	3.5±2.1	4.1±1.6	1.748	0.165
Postoperative drainage (ml)	356.4±171.8	249.4±156.9	0	0		
Follow-up duration (months)	22.6±6.0	21.5±5.7	18.8±3.4	18.9±5.2	2.095	0.107
Correction percentage of anterior column height of fractured vertebra (%)	21.0±11.3	29.4±13.8	13.5±10.0 [#]	14.0±9.8 [#]	8.399	<0.001
Correction of sagittal regional Cobb angle (°)	7.3±7.0	9.3±6.6	5.0±3.8 [#]	5.7±3.0 [#]	2.789	0.046
Correction of injured vertebral kyphotic angle (°)	9.3±6.4	11.7±5.0	5.7±4.1 [#]	7.3±5.6 [#]	5.364	0.002
Correction loss percentage of anterior column height (%)	6.3±5.1	5.9±5.2	5.9±4.2	4.5±3.1	0.261	0.853
Correction loss of sagittal regional Cobb angle (°)	6.1±4.3	4.4±2.9	3.9±2.9	3.3±2.6	1.326	0.276
Correction loss of injured vertebra kyphotic angle (°)	3.2±2.9	2.4±1.7	2.3±1.6	2.4±1.8		

* $P < 0.05$ compared with OPSF-4 group; # $P < 0.05$ compared with OPSF-6 group.

of the pedicle and vertebral body in the PPSF-6 screw group. In addition, 2 pedicle screws were pulled out below the fractured vertebra in 1 case in the PPSF-6 screw group.

There was no significant difference in the follow-up period among the 4 groups ($P > 0.05$), indicating the follow-up outcomes are comparable. There was no significant difference among the 4 groups in the correction loss of the percentage of anterior column height, loss of sagittal regional Cobb angle, or kyphotic angle of the fractured vertebra at the final follow-up (all $P > 0.05$, Table 2, Figure 1).

Discussion

In this study we systematically compared the surgical efficacies with regard to intraoperative, postoperative, and follow-up outcomes between OPSF-4, OPSF-6, PPSF-4, and PPSF-6 screw fixations for thoracolumbar fractures. The results indicated obvious correction of the percentage of anterior column height, sagittal regional Cobb angle, and kyphotic angle of fractured vertebra in all patients immediately after and more than 1 year after the surgery, confirming that SSPSF is safe and effective for the treatment of thoracolumbar fractures.

Intraoperative blood loss in the PPSF-4 or -6 screw group was significantly less than in the OPSF-4 and -6 screw groups. Postoperative drainage occurred in the OPSF-4 and -6 screw groups, but was not observed in the PPSF-4 or -6 screw groups, indicating the advantages of PPSF fixation for thoracolumbar fractures. Of note, intraoperative blood loss showed no significant difference between the OPSF-4 and -6 screw groups or between PPSF-4 and -6 screw groups. The reasons might be as follows. Two additional screws in the fractured vertebra were mainly to improve and maintain the reduction of fracture instead of decreasing the intraoperative blood loss. The 2 extra screws for the fixation increased (although insignificantly) surgery time in the OPSF-6 vs. OPSF-4 screw groups and in the PPSF-6 vs. PPSF-4 screw groups, which might have increased the intraoperative blood loss to some extent in PPSF-6 vs. PPSF-4 screw groups. Similarly, given the primary intention of the addition of 2 extra screws in the fractured vertebra, it is understandable that OPSF-6 fixation did not significantly reduce the postoperative drainage compared with OPSF-4 fixation.

Interestingly, the percentage of anterior column height of the fractured vertebra obtained best correction by OPSF-6 screw fixation than by other techniques, including PPSF-4 and -6 fixation, which is consistent with results of Guven's study [18]. Similarly, the correction of sagittal regional Cobb angle and kyphotic angle of the fractured vertebra in this study was

significantly larger in the OPSF-6 screw group than in the PPSF-4 and -6 screw groups. These results do not exhibit advantages of PPSF technique in the vertebral fracture correction in comparison with OPSF technique, especially OPSF-6 screw fixation. The possible reasons are the following. First, for OPSF-6 screw technique, placement of patients in hyperextension in the prone position in combination with distraction tools for fracture reduction lead to better recovery of the height of the fractured vertebra and intervertebral space, especially when cephalic and caudalis distraction were performed simultaneously for fractures of Denis type IA and IIA. In contrast, for PPSF surgery, the distraction for fracture depended on patient hyperextension in the prone position and pressure put on the spinous process; as a result, the recovery of anterior column height of fractured vertebra was relatively poor. Second, for OPSF-6 screw fixation, pre-flexed rods on the basis of the normal spinal sagittal curvature of the fractured region plus monoaxial pedicle screws could effectively correct sagittal regional Cobb angle and kyphotic angle of the fractured vertebra; in contrast, since the sagittal curvature of the fracture region in PPSF fixation could not be visually obtained, rods were pre-flexed according to the surgeons' experience and estimation, which might thus limit the utility of monoaxial pedicle screws in angle correction. Third, since the Sextant system with polyaxial pedicle screws was used in PPSF surgery, the distraction could not be as easily performed as in OPSF-6 surgery, and fracture reduction partly depended on patient position and manual reduction, which might make it difficult to carry out the angular correction. Fourth, the inconsistency of the present results and the anticipated advantages of PPSF in vertebral fracture correction might be also related to our patient inclusion and exclusion criteria, as well as the limited sample size in this study. We plan to perform another study with a larger sample size and stratification of thoracolumbar fracture types to validate these results.

Some clinical studies reported shorter operation time for PPSF compared with OPSF [11,23]; however, but the present study showed there was no significant difference in operation time among the 4 groups, which is in agreement with the results of Wang et al. [24]. There are 2 possible reasons for this discrepancy: 1) the operations were not carried out by the same surgeons or those with similar experience; and 2) although OPSF and PPSF shared some similar surgical procedures, OPSF was carried out earlier than PPSF worldwide, including in our hospital, and surgeons have developed better mastery of this technique compared to PPSF. PPSF has only recently begun to be used at our hospital, and our surgeons are still learning to use it.

Pain VAS on surgery day was insignificantly lower in PPSF than in OPSF, which was in accordance with result of Wang et al. [24]. In our next study, with larger sample size, we intend to

determine whether PPSF significantly reduces the postoperative pain VAS compared to OPSF.

Reportedly, the additional 2 pedicle screws into the fractured vertebra can provide stress dispersion and improve biomechanical stability [23], which achieves better fracture correction. Consistently, the present study revealed the advantages of OPSF-6 screw fixation in the correction of the percentage of anterior column height, and correction of sagittal regional Cobb angle and kyphotic angle of the fractured vertebra in comparison with the corresponding OPSF-4 screw fixation. However, the PPSF-6 screw fixation did not exhibit superiority to the corresponding PPSF-4 screw fixation. This may be related to the inherent default SSSPF technique. There is some space within the fractured vertebra, and the irregular space results in so-called "egg shell" vertebra due to the distraction procedure during the SSSPF fixation, which might cause insufficient support for the anterior column or anterior-middle columns of the fractured vertebra. In the SSSPF procedures, the patients are encouraged to be out of bed early after the surgery, but at this time the fractures are usually not healed and the fractured thoracolumbar vertebra after SSSPF surgery cannot completely bear the trunk load of the body. These factors might consequently influence the correction of fractured vertebra in the 6- and 4-screw fixation groups. For these reasons, it is not surprising that PPSF-6 screw fixation did not show superiority in the correction of thoracolumbar fractures compared to the corresponding PPSF-4 screw fixation. Because of other reasons mentioned above, OPSF-6 screw fixation still showed apparent advantages in the fractured vertebral correction over OPSF-4 screw fixation.

Few studies have compared the efficacy of PPSF vs. OPSF fixation for thoracolumbar fractures. Wang et al. showed that PPSF-4 and -6 screw fixations both achieved significant improvement in vertebral body angle, sagittal Cobb angle, and anterior height of the fractured vertebra when compared with OPSF-4 screw fixation, and that the follow-up correction of the sagittal Cobb angle was less in the PPSF-6 group than in the PPSF-4 group [24]. Contrary to the results of Wang et al., the present study demonstrated that correction of the percentage of anterior column height and correction of sagittal regional Cobb angle and kyphotic angle of fractured vertebra by PPSF (including PPSF-4 and -6 screw fixation) were significantly less than those in OPSF-6 screw fixation. In addition, we found no significant difference in the follow-up correction of the above parameters among patients receiving OPSF-4 and -6 and PPSF-4 and -6 screw fixation. Further studies are needed to verify these results.

This study systematically compared the intraoperative, postoperative, and follow-up outcomes between OPSF-4, OPSF-6, PPSF-4, and PPSF-6 screw fixation for thoracolumbar fractures,

which will be helpful in the clinical selection and development of related surgical approaches for thoracolumbar fractures. As a new and promising technique, with more experience and mastery by surgeons and further improvement in China, it is anticipated that PPSF (including PPSF-4 and -6 screw fixation) will exhibit better efficacy in the treatment of thoracolumbar fractures.

There are some limitations in our study. This was a retrospective study based on reviewing the collected clinical information of the patients instead of prospectively designing and carrying out the study. This might have caused selection bias. The number of included patients was too small for optimal statistical analysis and the follow-up period was relatively short. Future prospective studies with more patients and longer follow-up period are warranted.

References:

1. Korovessis P, Baikousis A, Zacharatos S et al: Combined anterior plus posterior stabilization versus posterior short-segment instrumentation and fusion for mid-lumbar (L2-L4) burst fractures. *Spine (Phila Pa 1976)*, 2006; 31(8): 859-68
2. Shen WJ, Shen YS: Nonsurgical treatment of three-column thoracolumbar junction burst fractures without neurologic deficit. *Spine (Phila Pa 1976)*, 1999; 24(4): 412-15
3. Weinstein JN, Collalto P, Lehmann TR: Thoracolumbar "burst" fractures treated conservatively: a long-term follow-up. *Spine (Phila Pa 1976)*, 1988; 13(1): 33-38
4. Tezeren G, Kuru I: Posterior fixation of thoracolumbar burst fractures: short-segment pedicle fixation versus long-segment instrumentation. *J Spinal Disord Tech*, 2005; 18(6): 485-88
5. Wang ST, Ma HL, Liu CL et al: Is fusion necessary for surgically treated burst fractures of the thoracolumbar and lumbar spine?: A prospective, randomized study. *Spine (Phila Pa 1976)*, 2006; 31(23): 2646-52; discussion 2653
6. Dai LY, Jiang LS, Jiang SD: Posterior short-segment fixation with or without fusion for thoracolumbar burst fractures. A five to seven-year prospective randomized study. *J Bone Joint Surg Am*, 2009; 91(5): 1033-41
7. Xu BS, Tang TS, Yang HL: Long-term results of thoracolumbar and lumbar burst fractures after short-segment pedicle instrumentation, with special reference to implant failure and correction loss. *Orthop Surg*, 2009; 1(2): 85-93
8. Gelb D, Ludwig S, Karp JE et al: Successful treatment of thoracolumbar fractures with short-segment pedicle instrumentation. *J Spinal Disord Tech*, 2010; 23(5): 293-301
9. Kim HY, Kim HS, Kim SW et al: Short segment screw fixation without fusion for unstable thoracolumbar and lumbar burst fracture: A prospective study on selective consecutive patients. *J Korean Neurosurg Soc*, 2012; 51(4): 203-7
10. Khare S, Sharma V: Surgical outcome of posterior short segment transpedicle screw fixation for thoracolumbar fractures. *J Orthop*, 2013; 10(4): 162-67
11. Vanek P, Bradac O, Konopkova R et al: Treatment of thoracolumbar trauma by short-segment percutaneous transpedicular screw instrumentation: prospective comparative study with a minimum 2-year follow-up. *J Neurosurg Spine*, 2014; 20(2): 150-56
12. McLain RF, Sparling E, Benson DR: Early failure of short-segment pedicle instrumentation for thoracolumbar fractures. A preliminary report. *J Bone Joint Surg Am*, 1993; 75(2): 162-67
13. Alanay A, Acaroglu E, Yazici M et al: Short-segment pedicle instrumentation of thoracolumbar burst fractures: does transpedicular intracorporeal grafting prevent early failure? *Spine (Phila Pa 1976)*, 2001; 26(2): 213-17
14. Butt MF, Farooq M, Mir B et al: Management of unstable thoracolumbar spinal injuries by posterior short segment spinal fixation. *Int Orthop*, 2007; 31(2): 259-64
15. Shen WJ, Liu TJ, Shen YS: Nonoperative treatment versus posterior fixation for thoracolumbar junction burst fractures without neurologic deficit. *Spine (Phila Pa 1976)*, 2001; 26(9): 1038-45
16. Shin TS, Kim HW, Park KS et al: Short-segment pedicle instrumentation of thoracolumbar burst-compression fractures; short term follow-up results. *J Korean Neurosurg Soc*, 2007; 42(4): 265-70
17. Hwang JU, Hur JW, Lee JW et al: Comparison of posterior fixation alone and supplementation with posterolateral fusion in thoracolumbar burst fractures. *J Korean Neurosurg Soc*, 2012; 52(4): 346-52
18. Guven O, Kocaoglu B, Bezer M et al: The use of screw at the fracture level in the treatment of thoracolumbar burst fractures. *J Spinal Disord Tech*, 2009; 22(6): 417-21
19. Farrokhi MR, Razmkon A, Maghami Z, Nikoo Z: Inclusion of the fracture level in short segment fixation of thoracolumbar fractures. *Eur Spine J*, 2010; 19(10): 1651-56
20. Bolesta MJ, Caron T, Chinthakunta SR et al: Pedicle screw instrumentation of thoracolumbar burst fractures: Biomechanical evaluation of screw configuration with pedicle screws at the level of the fracture. *Int J Spine Surg*, 2012; 6: 200-5
21. Palmisani M, Gasbarrini A, Brodano GB et al: Minimally invasive percutaneous fixation in the treatment of thoracic and lumbar spine fractures. *Eur Spine J*, 2009; 18(Suppl.1): 71-74
22. Ni WF, Huang YX, Chi YL et al: Percutaneous pedicle screw fixation for neurologic intact thoracolumbar burst fractures. *J Spinal Disord Tech*, 2010; 23(8): 530-37
23. Lee JK, Jang JW, Kim TW et al: Percutaneous short-segment pedicle screw placement without fusion in the treatment of thoracolumbar burst fractures: is it effective?: Comparative study with open short-segment pedicle screw fixation with posterolateral fusion. *Acta Neurochir (Wien)*, 2013; 155(12): 2305-12; discussion 2312
24. Wang H, Zhou Y, Li C et al: Comparison of open versus percutaneous pedicle screw fixation using the sextant system in the treatment of traumatic thoracolumbar fractures. *J Spinal Disord Tech*, 2014; [Epub ahead of print]
25. Denis F, Armstrong GW, Searls K, Matta L: Acute thoracolumbar burst fractures in the absence of neurologic deficit. A comparison between operative and nonoperative treatment. *Clin Orthop Relat Res*, 1984; (189): 142-49

Conclusions

SSPSF is safe and effective for the treatment of thoracolumbar fractures. PPSF significantly reduced the intraoperative blood loss compared to OPSF. OPSF 6-screw fixation achieved significantly greater improvement in the correction of percentage of anterior column height compared with OPSF-4 and PPSF-4 and -6 screw fixation, and also exhibited significantly better improvement in the correction of sagittal regional Cobb angle and kyphotic angle of fractured vertebra than PPSF-4 and -6 fixation. We found no significant difference in the correction loss found between OPSF and PPSF fixation at the final follow-up.