



Received: 2015.08.10
Accepted: 2015.10.02
Published: 2016.03.27

Authors' Contribution:

- A** Study Design
- B** Data Collection
- C** Statistical Analysis
- D** Data Interpretation
- E** Manuscript Preparation
- F** Literature Search
- G** Funds Collection

Positive Outcome After a Small-Caliber Gunshot Fracture of the Upper Cervical Spine without Neurovascular Damage

Thula Walter^{1ABCDEF}, Philipp Schwabe^{2CDEF}, Klaus-Dieter Schaser^{2BCDEF},
Martin Maurer^{3ABCDEF}

¹ Department of Radiology, Charité University Medicine Berlin, Berlin, Germany

² Department of Musculoskeletal Surgery, Charité University Medicine Berlin, Berlin, Germany

³ Department of Radiology, University Hospital Bern, Inselspital, Bern, Switzerland

Author's address: Martin Maurer, Department of Radiology, University Hospital Bern, Inselspital, Bern, Switzerland,
e-mail: martin.maurer@insel.ch

Summary

Background:

Gunshot wounds to the cervical spine most frequently concur with serious injuries to the spinal cord and cervical vessels and often have a fatal outcome.

Case Report:

We describe the case of a 35-year-old male with a complex fracture of the C2 vertebra body and a mandibular fracture after a penetration gunshot to the cervical spine. Computed tomography (CT) at admission revealed the exact extent of the fractures and the small caliber bullet lodged next to the C2 vertebra. In this rare and extremely lucky case no collateral vascular or neurological damage was detected. Eighteen months after surgical bullet removal and posterior C1–C3 fusion complete bone healing of the C2 vertebra was achieved and there were no secondary neurovascular deficits.

Conclusions:

Immediate surgical C1–C3 fixation resulted in an excellent outcome without secondary neurovascular deficits in this rare case of traumatic complex C2 vertebral fracture caused by a gunshot injury.

MeSH Keywords:

Axis • Spinal Fractures • Tomography Scanners, X-Ray Computed • Trauma, Nervous System • Wounds, Gunshot

PDF file:

<http://www.polradiol.com/abstract/index/idArt/895529>

Background

Most gunshot wounds occur in the thorax and abdomen [1,2]. However, gunshot wounds in civilians are one of the three leading causes of spinal cord injury. Many of these penetrating injuries of the cervical spine result in devastating collateral damage to the cervical vessels and the neural axis [3,4]. We present the rare case of a small-calibre shot of the C2 vertebra without collateral neurological or vascular injuries of the neck.

Case Report

A 35-year-old man was brought to the emergency department (ED) after two business associates shot him twice with a small-caliber pistol (7 mm bullet caliber) from a

distance of less than one meter, once in the neck and once in the right hand.

Upon admission the patient was fully conscious, alert and breathing spontaneously (Glasgow Coma Scale, GCS, 15). General inspection of the patient revealed a through-and-through gunshot wound of the right hand, as well as a gunshot entrance wound at the right cheek but no exit wound. After admission an increasing swelling of the neck became apparent. The patient was fiber-optically intubated and a standard imaging protocol in accordance with Advanced Trauma Life Support (ATLS™) guidelines was performed. The conventional radiographs revealed a C2 fracture and a small-caliber bullet lodged laterally to the left C1/C2 facet joint and a fracture of the right mandibula (Figure 1A). Multiplanar computed tomography (CT) – reformations of

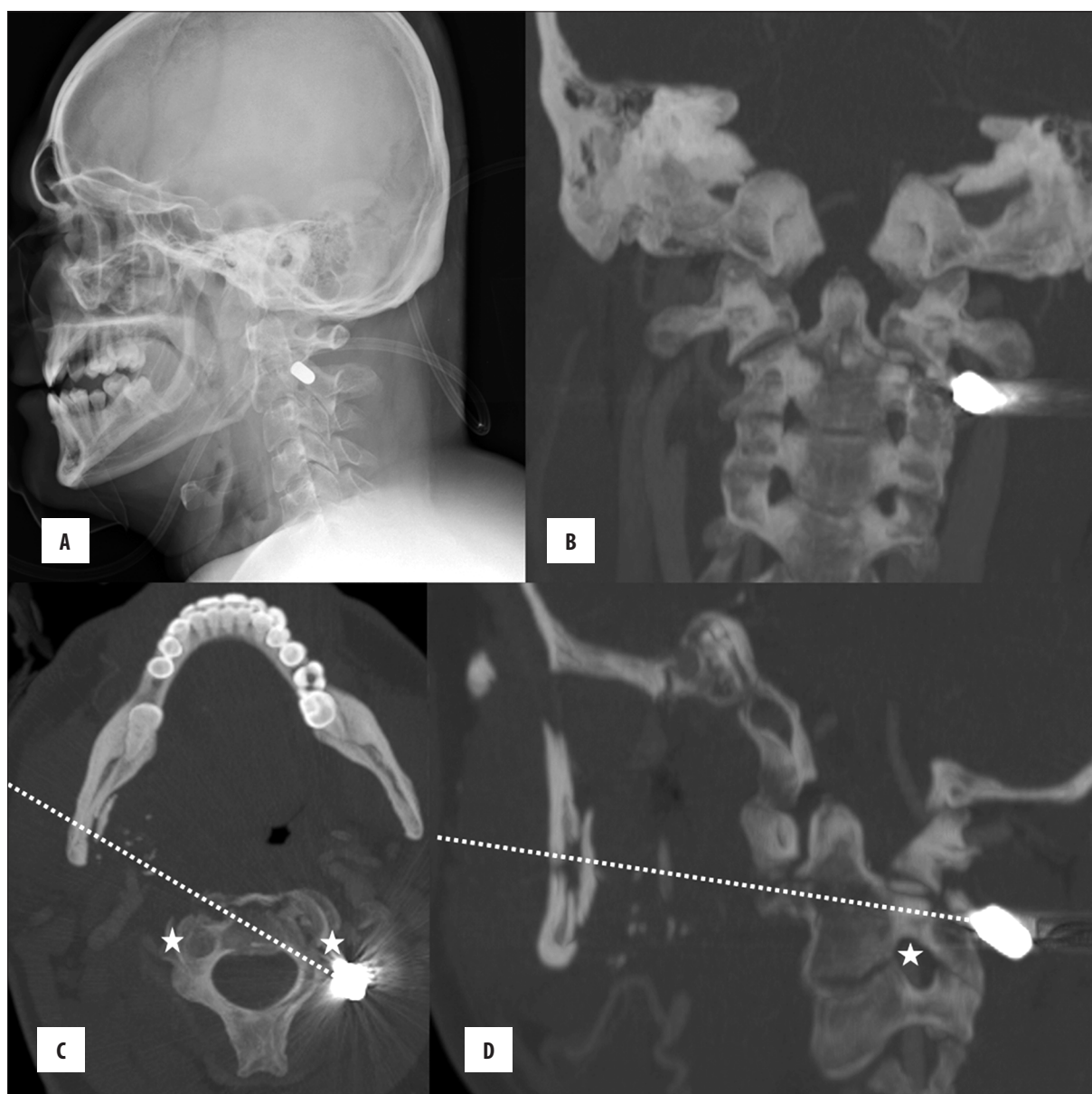


Figure 1. Conventional radiography shows the bullet in projection close proximity to the C1/C2 facet joint (A). Coronal (B), axial (C) and sagittal (D) CT reformations of the cervical spine show the trajectory of the bullet and the resulting complex fracture of the basis of the C2 vertebra (Benzel fracture Type 2 [4]) leaving the cervical spinal cord and left vertebral artery intact. The dotted lines indicate the bullet path (C, D), the asterisks indicate sensible vessel structures like the vertebral artery (C, D).

the cervical spine showed a complex fracture of the body and the dens of the C2 vertebra, which had been penetrated by the bullet (Figures 1, 2). Most astonishingly, no vascular or neurological damage, which often concurs with such a trauma, was evident on CT images and in CT angiography (CTA, Figure 2).

Following posterior approach to the craniovertebral junction, surgical removal of the bullet and closed reduction with fixation of the cervical vertebrae by posterior Harms-Goel fusion of C1–C3 (Figure 3) was performed. Wound debridement of the right hand and cheek (maxillofacial surgeon) was simultaneously arranged. Eighteen months after treatment follow-up CT imaging showed an almost complete consolidation of the fractured C2 vertebra (Figure 4).

Discussion

In penetrating ballistic traumas to the cervical region the radiological assessment of fractures, vascular and neurological trauma is paramount in the management of hemodynamically and neurologically stable patients [5–7].

Although ballistic trauma to the spine is mainly the domain of military medicine, the incidence of civilian gunshot victims in urban settings is substantial and continues to increase [1,8]. Overall, gunshot wounds of the cervical spine comprise only about 1.5% of all gunshot lesions of the spine [9]. Moreover, gunshot trauma to the cervical spine most often results in major collateral damage, the most frequent being brainstem compression, penetration

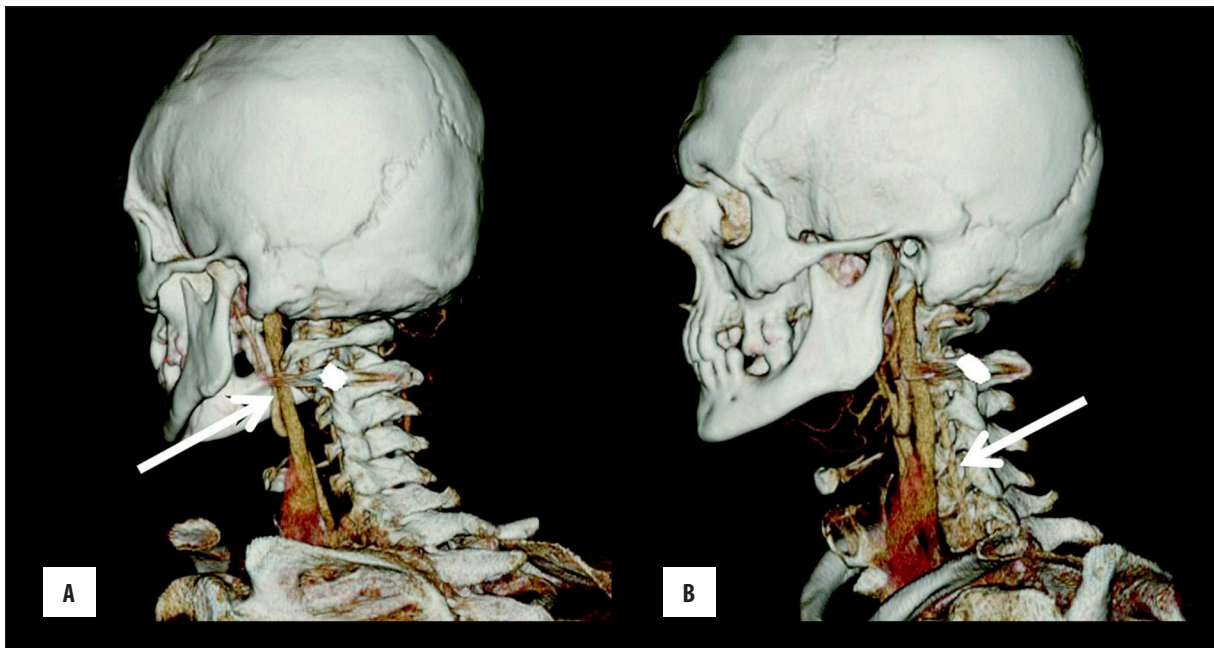


Figure 2. Intact left carotid artery (A, arrow) and intact left vertebral artery (B, arrow) on rotated 3D CT reformations to analyze the bullet path and the vessel anatomy.

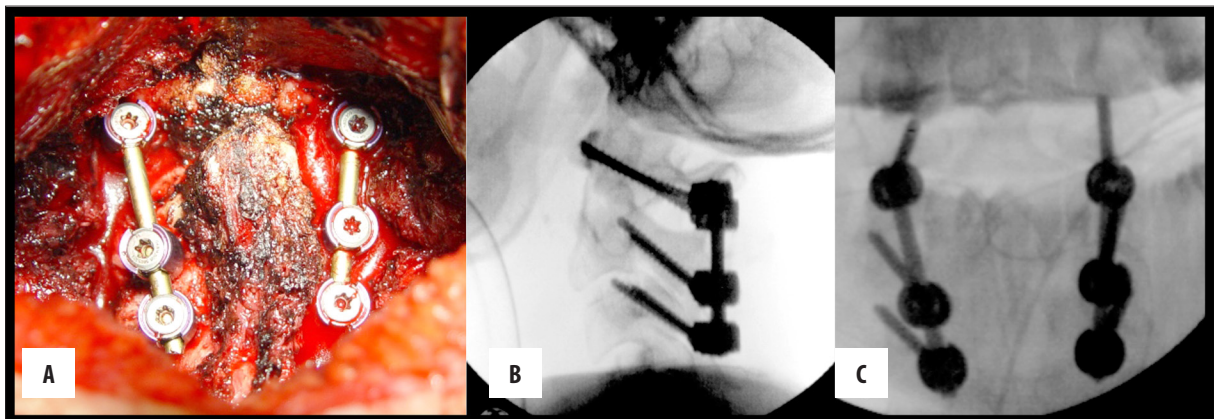


Figure 3. Postoperative radiograph with complete fixation construct C1–C3 intraoperatively (A), and in a radiographically lateral (B) and anterior-posterior (C) view.

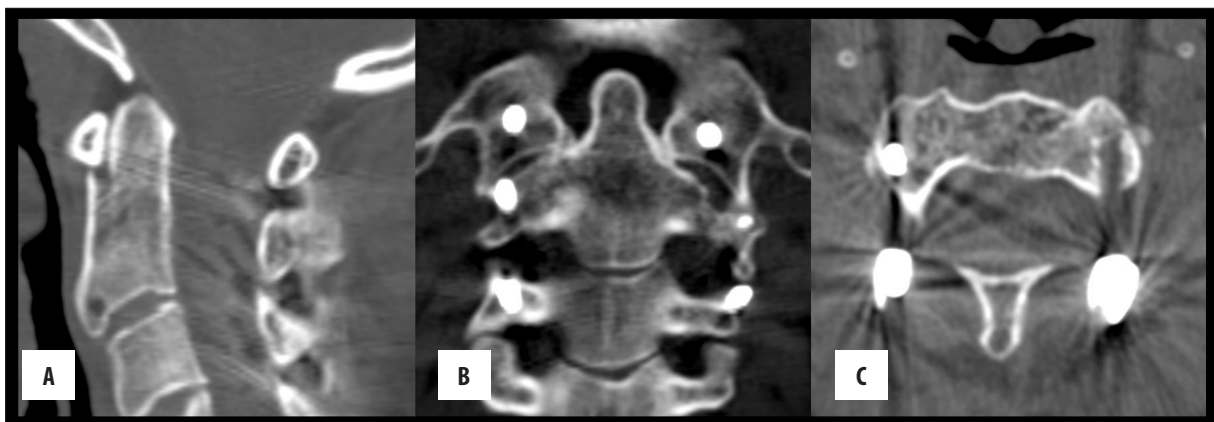


Figure 4. Sagittal (A), coronal (B) and axial (C) CT-images 18 months after bullet removal and dorsal stabilization of the cervical spine with spondylodesis. The bone structure of the C2 vertebral body healed completely.

into vascular structures, which often result in a massive stroke [3,7,10].

Due to the high likeliness of vascular involvement after a penetrating gunshot trauma to the cervical spine, CTA is generally recommended in patients with a suspected arterial injury [11,12]. Gunshot wounds to the head, as opposed to stabbing or blunt trauma bear the additional risk of the bullet fragmenting upon impact, causing further damage and making retrieval of fragments more complex [1,6,8]. Beam hardening or streak artifacts caused by bullet fragments can make exact localization difficult. In these cases, CT scout images can be helpful in addition to regular CT images [1].

References:

1. Offiah C, Twigg S: Imaging assessment of penetrating craniocerebral and spinal trauma. *Clin Radiol*, 2009; 64: 1146–57
2. Kane T, Capen DA, Waters R et al: Spinal cord injury from civilian gunshot wounds: the Rancho experience 1980–88. *J Spinal Disord*, 1991; 4: 306–11
3. Ramasamy A, Midwinter M, Mahoney P, Clasper J: Learning the lessons from conflict: pre-hospital cervical spine stabilisation following ballistic neck trauma. *Injury*, 2009; 40: 1342–45
4. Benzel EC, Hart BL, Ball PA et al: Fractures of the C-2 vertebral body. *J Neurosurg*, 1994; 81: 206–12
5. Medzon R, Rothenhaus T, Bono CM et al: Stability of cervical spine fractures after gunshot wounds to the head and neck. *Spine*, 2005; 30: 2274–79
6. Petridis AK, Doukas A, Barth H, Mehdorn M: Outcome of craniocerebral gunshot injuries in the civilian population. Prognostic factors and treatment options. *Cent Eur Neurosurg*, 2011; 72: 5–14
7. Willis BK, Greiner F, Orrison WW, Benzel EC: The incidence of vertebral artery injury after midcervical spine fracture or subluxation. *Neurosurgery*, 1994; 34: 435–41
8. Bono CM, Heary RF: Gunshot wounds to the spine. *Spine J*, 2004; 4: 230–40
9. Waters RL, Adkins RH, Yakura J, Sie I: Profiles of spinal cord injury and recovery after gunshot injury. *Clin Orthop Relat Res*, 1991; 267: 14–21
10. Dalgic A, Okay O, Nacar O et al: Vertebral artery insult at the transverse foramina by gun shot wounds: report of two cases. *Turk Neurosurg*, 2009; 19: 413–16
11. Munera F, Soto JA, Nunez D: Penetrating injuries of the neck and the increasing role of CTA. *Emerg Radiol*, 2004; 10: 303–9
12. Schroeder JW, Baskaran V, Aygun N: Imaging of traumatic arterial injuries in the neck with an emphasis on CTA. *Emerg Radiol*, 2010; 17: 109–22

Conclusions

In conclusion, the uniqueness of the presented case rests upon the fact that despite the substantial trauma to the cervical spine, i.e. fracture of the C2 basis, the patient did not suffer from collateral damage to the carotid and vertebral arteries or the spinal cord/nerve roots. ATLS™ standard imaging protocols are effective in this patient collective and due to the high likeliness of vascular damage, CTA is also recommended. Final surgical treatment with stable atlantoaxial screw fixation is the key to prevent patients from secondary complications caused by posttraumatic spinal instability.