

A small series of pole sport injuries

Florian Dittrich,¹ Sascha Beck,²
Manuel Burggraf,³ Andre Busch,⁴
Marcel Dudda,³ Marcus Jäger,⁴
Max Daniel Kauther³

¹Department for Orthopaedics and Orthopaedic Surgery, Saarland University Medical Center and Saarland University Faculty of Medicine; Joint Centre Bergisch Land, Department for Orthopaedics, Sana Fabricius Clinic Remscheid, Remscheid;
²Clinic for Orthopaedics and Trauma Surgery, Sportsclinic Hellersen, Lüdenscheid; ³Clinic of Trauma, Hand and Reconstructive Surgery;
⁴Department of Orthopaedics and Traumatology, University of Duisburg-Essen, Germany

Abstract

Pole sport is a relatively new athletic sport that is gaining increasing popularity and for which national and international championships are held. It evolved from pole dance and harbours the risk of falls from heights of up to three metres. Currently, no studies on pole sport injuries are available. This is the first description of a small series of five pole sport injuries. A retrospective review of the case histories and radiological findings was performed, and in addition, a follow-up interview was carried out. All the patients were female and had a mean age of 27.2 years. Most injuries were located in the head, neck or spine. The use of proper training equipment like landing mats and grip aids could probably reduce accidents.

Introduction

Pole sport combines choreographed elements of dance, gymnastics and acrobatics executed on a vertical pole of up to three metres height with a diameter ranging between 50 and 40 mm. Over the past ten years, pole sport has evolved from the negatively connoted “pole dance” to a nationally and internationally organized non-sexual form of sport. It is becoming increasingly popular in dance and fitness studios and places high demands on the physical fitness, grip strength and coordination of the athletes.¹

Training and performance harbour the

risk of serious accidents, including falls onto the head from great height, but there are very few current publications about traumas in pole sport. Wamelink *et al.* describe the accumulated occurrence of stress fractures of the fifth metatarsal in the case of excessive metatarsal adduction as a result of pole sport.² We report on a small series of five pole sport accidents treated in our clinic.

Case Report

Between 2011 and 2017, four female patients presented with acute injuries sustained during pole sport. One patient was injured twice. The average age of the patients at the time of their accident was 27 (± 4.3) years.

The medical reports and radiological findings were evaluated retrospectively. In addition, a standardised survey of clinical parameters was carried out within the framework of the follow-up investigation during a telephone interview.

A total of seven inpatient days and eight further consultations resulted from the five pole sport injuries treated in our clinic.

The first patient, 32 years old, was diagnosed with a dislocated clavicle fracture (A2, Allmann Type 1) (Figure 1) after falling on her head. She was treated with open reduction and internal fixation by plate. Follow-up examination after 17 months showed that the fracture had healed primarily with no further problems.

A 31 years old suffered isolated transverse process fractures of L2 to L4 and a pelvic contusion (Figure 2). She was conservatively with primary inpatient therapy.

The third patient was injured twice due to falls on her head. At the age of 22, she suffered a mild traumatic brain injury without loss of consciousness. Two years later, she presented with a cervical spinal distortion (Quebec Task Force II°). Both injuries were treated conservatively.

The fourth patient sprained her ankle after falling from a low height. The ankle was stabilized in a splint and full weight-bearing was permitted.

All patients returned to the same level of pole sport.

Discussion

Despite its rising popularity, little has been reported about accidents in pole sport. We found a young and physically fit patient group who had suffered atypical headfirst falls. Injuries to the head, spine and shoulder

Florian Dittrich, Department for Orthopaedics and Orthopaedic Surgery, Saarland University Medical Center and Saarland University Faculty of Medicine, Kirrberger Straße, Building 37-38, D-66421 Homburg/Saar, Germany.
Tel.: 0049- 6841/16-24520
E-mail: Florian.Dittrich@uk-essen.de

Key words: Pole dance; pole sport; trauma; prevention.

Contributions: FD: conception and design, manuscript writing; SB, MB, AB: editing of manuscript; MD, MJ: drafting the article and revision of final draft; MDK: conception, intellectual content and final approval.

Conflict of interest: The authors declare no potential conflict of interest.

Funding: We acknowledge the support provided by Deutsche Forschungsgemeinschaft (DFG, German Research Foundation) and Saarland University as part of the Open Access Publishing funding program.

Ethics approval and consent to participate:

Availability of data and materials: Data and materials are available within the text.

Received for publication: 1 September 2019.
Accepted for publication: 16 April 2020.

This work is licensed under a Creative Commons Attribution NonCommercial 4.0 License (CC BY-NC 4.0).

©Copyright: the Author(s), 2020
Licensee PAGEPress, Italy
Orthopedic Reviews 2020;12:8308
doi:10.4081/or.2020.8308

region were mainly the result of falls occurring during the performance of overhead elements, so-called “inversions”. The accident mechanism produces a high level of kinetic energy and should not be underestimated by the trauma surgeon. Landing mats around the base of the pole as well as the additional safety measure of having a trainer present were not used in any of the cases. In line with the intensive use of landing mats in other acrobatic sports like gymnastics, safety equipment should be used in pole sport. Our findings correspond to the observations by Ruscello *et al.*, who identified the forces acting on a pole athlete. They reported that high positive and negative vertical acceleration rates of up to 2G and rotation of 400° per second are reached in pole sport.³ We believe that many people performing pole sport do not fulfil the physical requirements necessary to withstand these forces.

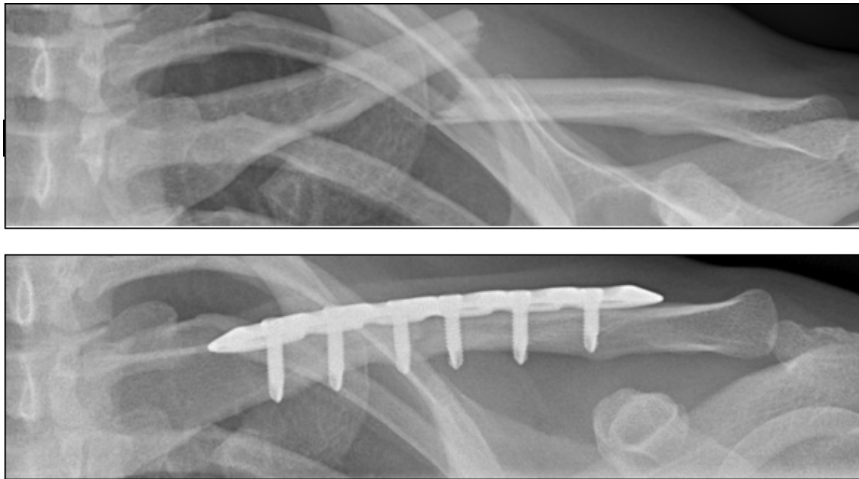


Figure 1. X-ray of left clavicle: A) At the time of the accident, B) 6 months after trauma.

Conclusions

Pole sport must be considered an acrobatic sport with a serious potential for injury rather than a dance sport. In cases of trauma sustained during pole sport it is essential to document the exact history of the accident and to carry out further diagnostics. To prevent injuries, we recommend special landing mats, training in how to fall safely, the presence of a trainer and no consumption of alcohol before the activity due to the performance-oriented requirements of this sport.

References

1. Nawrocka A, Mynarski A, Powerska A et al. Effects of exercise training experience on hand grip strength, body composition and postural stability in fitness pole dancers. *J Sports Med Phys Fitness* 2016;57:1098-103.
2. Wamelink KE, Marcoux JT, Walrath SM. Rare proximal diaphyseal stress fractures of the fifth metatarsal associated with metatarsus adductus. *J*

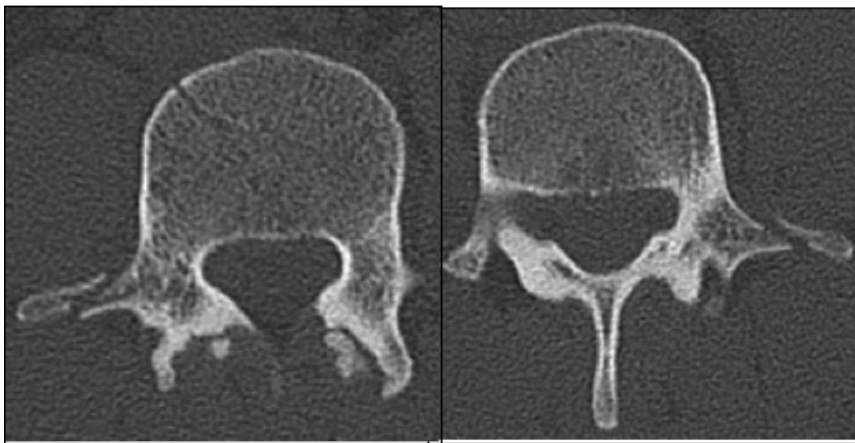


Figure 2. CT scan showing a transverse process fracture of L4.