


# Minimally Invasive Posterior Cervical Foraminotomy Versus Anterior Cervical Fusion and Arthroplasty: Systematic Review and Meta-Analysis

Global Spine Journal  
2022, Vol. 12(7) 1573–1582  
© The Author(s) 2021  
Article reuse guidelines:  
[sagepub.com/journals-permissions](https://sagepub.com/journals-permissions)  
DOI: 10.1177/21925682211055094  
[journals.sagepub.com/home/gsj](https://journals.sagepub.com/home/gsj)  


Andrew Platt, MD<sup>1</sup> , Richard G. Fessler, MD, PhD<sup>1</sup>, Vincent C. Traynelis, MD<sup>1</sup>, and John E. O'Toole, MD, MS<sup>1</sup>

## Abstract

**Study Design:** Systematic review and meta-analysis.

**Objectives:** Patients with lateral cervical disc and foraminal pathology can be treated with anterior and posterior approaches including anterior cervical discectomy and fusion (ACDF), cervical total disc arthroplasty (TDA), and minimally invasive posterior cervical foraminotomy (MIS-PCF). Although MIS-PCF may have some advantages over the anterior approaches, few comparative studies and meta-analyses have been done to assess superiority.

**Methods:** This study includes a systematic review of the literature and meta-analysis of studies directly comparing minimally invasive posterior cervical foraminotomy to either anterior cervical discectomy and fusion or cervical total disc arthroplasty.

**Results:** In comparing patients undergoing ACDF and MIS-PCF, operative time ranged from 68 to 97.8 minutes in the ACDF group compared to 28 to 93.9 minutes in the MIS-PCF group. Mean postoperative length of stay ranged from 33.84 to 112.8 hours in the ACDF group compared to 13.68 to 83.6 hours in the MIS-PCF group. The total complication rates were 3.72% in the ACDF group and 3.73% in the MIS-PCF group. A random-effects model meta-analysis was carried out which failed to show a statistically significant difference in the complication rate between the two procedures (OR .91; 95% CI 0.13, 6.43;  $P = .92$ ,  $I^2 = 59\%$ ). The total reoperation rate was 3.5% in the ACDF group and 5.4% in the MIS-PCF group. A random-effects model meta-analysis was carried out which failed to show a statistically significant difference in the reoperation rate between the two procedures (OR .66; 95% CI 0.33, 1.33;  $P = .25$ ,  $I^2 = 0$ ). In comparing patients undergoing TDA and MIS-PCF, operative time ranged from 90.3 to 106.7 minutes in the TDA group compared to 77.4 to 93.9 minutes in the MIS-PCF group. Mean postoperative length of stay ranged from 103.2 to 165.6 hours in the TDA group and 93.6 to 98.4 hours in the MIS-PCF group. The complication rate ranged from 23.5 to 28.6% in the TDA group and 0 to 14.3% in the MIS-PCF group. The overall reoperation rates were 2.6% in the TDA group and 10.2% in the MIS-PCF group.

**Conclusions:** There is no clear superiority between MIS-PCF and ACDF/TDA in terms of operative time, postoperative length of stay, or rate of complications/reoperations. Further studies with increased follow-up intervals >48 months, and higher sample sizes are necessary to determine the true superiority of MIS-PCF and anterior neck approaches in treatment of lateral disc and foraminal pathology.

## Keywords

minimally invasive foraminotomy, disc replacement, spondylosis, anterior cervical discectomy and fusion, radiculopathy, decompression, degenerative, cervical

<sup>1</sup>Department of Neurosurgery, Rush University Medical Center, Chicago, IL, USA

## Introduction

Cervical radiculopathy can be characterized by a constellation of symptoms related to cervical nerve root compression

### Corresponding Author:

Andrew Platt, Department of Neurosurgery, Rush University Medical Center, 1725 W. Harrison St., Suite 855, Chicago, IL 60612 USA.  
Email: [andrewplatt2014@gmail.com](mailto:andrewplatt2014@gmail.com)



Creative Commons Non Commercial No Derivs CC BY-NC-ND: This article is distributed under the terms of the Creative Commons Attribution-NonCommercial-NoDerivs 4.0 License (<https://creativecommons.org/licenses/by-nc-nd/4.0/>) which permits non-commercial use, reproduction and distribution of the work as published without adaptation or alteration, without further permission provided the original work is attributed as specified on the SAGE and Open Access pages (<https://us.sagepub.com/en-us/nam/open-access-at-sage>).

including upper extremity pain, paresthesia, and weakness.<sup>1,2</sup> Following failure of non-operative management, surgical intervention is indicated which can be performed with several techniques. Originally described in two cadaveric studies in 2000, minimally invasive posterior cervical foraminotomy (MIS-PCF) has gained popularity as a minimally invasive treatment for lateral spinal canal pathology causing radiculopathy.<sup>3,4</sup> Although initial case series focused on minimally invasive endoscopic approaches, microscopic, and percutaneous endoscopic (full-endoscopic) approaches have also been described.<sup>5-8</sup>

Anterior cervical discectomy and fusion (ACDF) is widely employed in the treatment of cervical radiculopathy and myelopathy. Anterior cervical approaches, in general, minimize muscular dissection which is required in open posterior and to a lesser extent in minimally invasive posterior approaches. This results in decreased postoperative pain and a decreased risk of postoperative infection.<sup>9</sup> Anterior approaches, however, have several disadvantages including dysphagia, vocal cord paresis, and risk of damage to critical anatomic structures. In comparison to any non-fusion procedure, some anterior cervical fusion patients may develop symptomatic non-union. There is some evidence that ACDF may promote adjacent segment disease, the symptomatic presentation of a patient with radiologic findings of degeneration above or below a fused segment. Hilibrand et al.<sup>10</sup> found that the rate of symptomatic adjacent segment disease occurred at an incidence of 2.9% per year and predicted that 25.6% of patients would have adjacent segment disease within 10 years of anterior cervical arthrodesis. First reported in the 1990s cervical total disc arthroplasty (TDA), also known as cervical total disc replacement (CTDR), has gained popularity as a way to treat cervical myelopathy and radiculopathy and limit the rate of adjacent segment disease by preserving motion.<sup>11</sup>

MIS-PCF has some benefits over TDA and ACDF as it avoids pseudoarthrosis, anterior approach-related complications, and is motion preserving thus potentially limiting the development of adjacent segment disease. Few comparative studies and meta-analyses have been done to assess superiority of these basic techniques for the treatment of lateral canal and foraminal pathology. This study presents a systematic review of the literature and meta-analysis of studies directly comparing MIS-PCF to ACDF or TDA in terms of operative/hospital admission metrics including operative time, hospital length of stay, complications, and reoperations.

## Methods

### Protocol

This study includes a systematic review of the literature conducted in accordance with the Preferred Reporting Items for Systematic Reviews and Meta-Analysis (PRISMA) statement.<sup>12</sup>

### Eligibility Criteria, Information Sources, Search

Online databases PubMed, the Cochrane Library, and Scopus, were used to identify clinical studies comparing minimally invasive posterior cervical foraminotomy to anterior cervical discectomy and fusion or cervical total disc arthroplasty. Specific MeSH terms and key words including “cervical foraminotomy,” “anterior cervical discectomy and fusion,” “minimally invasive foraminotomy,” “anterior cervical fusion,” “posterior foraminotomy,” “ACDF,” “anterior cervical discectomy,” “cervical arthroplasty,” and “cervical disc replacement,” were used in various combinations to identify studies of interest. Additional manual searches through cited references were performed.

### Study Selection

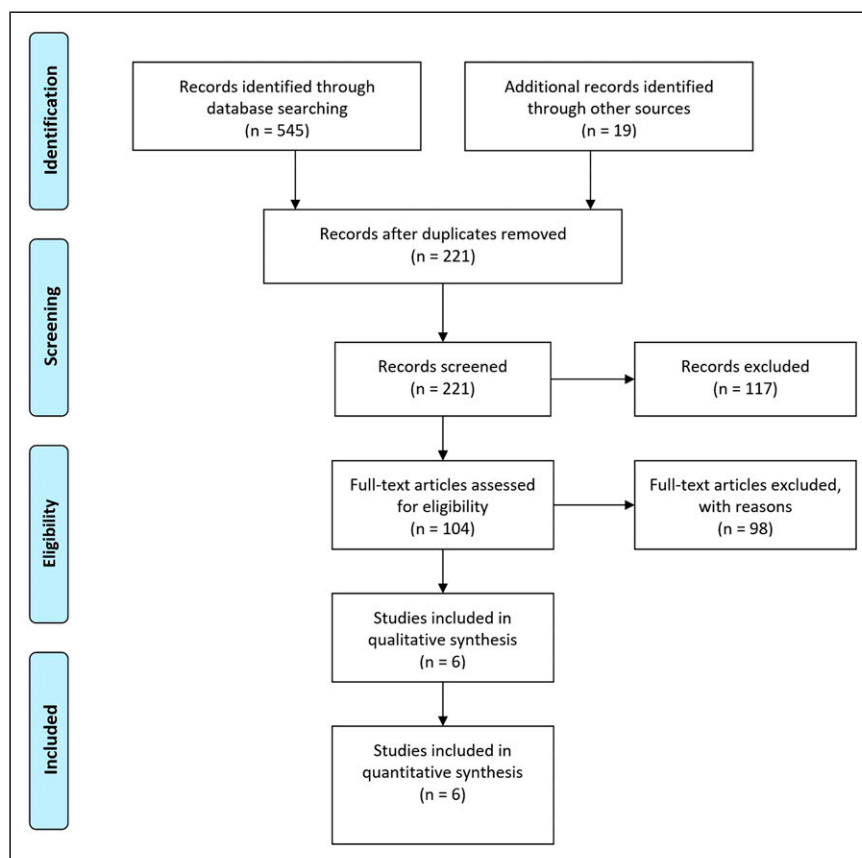
Directly comparative studies including randomized controlled trials, prospective/retrospective cohort and case-control studies were included in further analysis. Non-English publications, editorials, conference abstracts, errata, book chapters, systematic reviews, meta-analyses, case reports, and case series were excluded. Only studies directly comparing minimally invasive posterior cervical foraminotomy by an endoscopic or tubular system to anterior cervical discectomy and fusion or cervical total disc arthroplasty were included in analysis. Studies that included open posterior cervical foraminotomies performed from a midline incision with a subperiosteal dissection or that did not specifically define the operative technique were excluded. Studies that included anterior cervical foraminotomies were excluded and studies that included patients with cervical myelopathy were excluded.

### Data Collection Process, Data Items

Studies were evaluated for differences in operative/hospital admission metrics including operative time, hospital length of stay, complications, and reoperations.

### Summary Measures, Synthesis of Results, Risk of Bias, Additional Analyses

Meta-analysis was only performed if there were three or more studies that evaluated the same variable. An odds ratio and 95% confidence interval were calculated for dichotomous outcomes which were then pooled by random-effects model meta-analysis. All statistical tests were performed using RevMan 5.3 (Copenhagen: The Nordic Cochrane Centre, The Cochrane Collaboration, 2014). An  $I^2$  test was performed for each comparison to test statistical heterogeneity with  $I^2$  values exceeding 25%, 50%, and 75% indicating a low, moderate, and high degree of heterogeneity, respectively. For all meta-analyses, outcomes were pooled with weights calculated by the inverse-variance method. A  $P$ -value  $< .05$  was used to assess statistical significance. Each study included in meta-analysis



**Figure 1.** A flow chart of study inclusion and exclusion.

was further assessed for risk of bias. Specifically, studies were evaluated for selection bias, performance bias, detection bias, attrition bias, and reporting bias. Each study was assigned a corresponding level of evidence according to the scale adopted by the North American Spine Society, January 2005.<sup>13</sup>

## Results

### Systematic Review

In total 221 abstracts were reviewed of which 117 were excluded. One hundred and four full text articles were assessed of which 98 were excluded. Studies were excluded for including cervical foraminotomies from an anterior approach. Several studies were excluded for not comparing posterior cervical foraminotomy to ACDF or TDA.<sup>9,36-50</sup> Studies were also excluded for including open posterior cervical foraminotomies within a comparative group or if it was unclear from the study methods whether the group was exclusively done in a minimally invasive fashion.<sup>9,36-50</sup> Kim et al.<sup>51</sup> 2018 was excluded for not including operative/hospital admission metrics. Helseth et al.<sup>52</sup> 2019 met the majority of inclusion criteria and was directly comparative in nature, however, was excluded for including patients with cervical myelopathy. Overall six studies were included in quantitative

synthesis including four studies that directly compare MIS-PCF to ACDF, one study that directly compares MIS-PCF to TDA, and one study that compares MIS-PCF to both ACDF and TDA.<sup>53-58</sup> A flow chart of study inclusion and exclusion is shown in [Figure 1](#).

### MIS-PCF Compared to ACDF

Five studies were included that met inclusion criteria and directly compared outcomes between patients undergoing MIS-PCF and ACDF ([Table 1](#)).<sup>53-57</sup> Of the five studies Ruetten et al. represents the only randomized controlled trial to compare the two surgical modalities; the remainder of studies were retrospective cohort series. Minimally invasive techniques varied per study and included a full-endoscopic/percutaneous approach in Ruetten et al. and a microscopic tubular retractor-assisted approach in Dunn et al.<sup>53,56</sup> Lin et al.<sup>57</sup> reported that the first 11 included cases were done in a microscopic tubular retractor assisted fashion, whereas the remaining 10 cases were done using full-endoscopic technique. Mansfield et al. did not specify the exact technique that was used, however, discussion with the primary investigator of the study revealed that a microscopic tubular retractor assisted approach was utilized.<sup>59</sup> Young et al.<sup>55</sup> described an operative technique utilizing a series of minimally invasive self-retaining speculums prior to the

availability of tubular retractors. All patients were treated for cervical radiculopathy without myelopathy. Three of the five included studies specified that all patients presented preoperatively with lateral disc herniations.<sup>53,54,57</sup> Overall 693 patients were included in the ACDF group and 294 patients were included in the MIS-PCF group. Each study comparing MIS-PCF to ACDF was found to have a high risk of bias (Figure 2).

Two studies compared mean operative time and found it to range from 68 to 97.8 minutes in the ACDF group compared to 28 to 93.9 minutes in the MIS-PCF group (Table 2).<sup>53,57</sup> The difference reached statistical significance in Ruetten et al. Two studies compared postoperative length of stay which ranged from 33.84 to 112.8 hours in the ACDF group compared to 13.68 to 83.6 hours in the MIS-PCF group. The difference reached statistical significance in Mansfield et al.<sup>54</sup>

Three studies compared postoperative complications and found the frequency to range between 1.8% and 6.0% in the ACDF group and 0% and 14.3% in the MIS-PCF group (Table 2).<sup>53,56,57</sup> Of all patients in the ACDF group who suffered a complication the most common was pseudoarthrosis (36% of total complications), followed by dysphagia (21% of total complications), infection (14% of total complications), and hematoma (7% of total complications). In the MIS-PCF group the most common reported complication was transient hypoesthesia. Only one study, Lin et al.,<sup>57</sup> found the relationship to be statistically significant with a higher complication rate in the MIS-PCF group. The total complication rates were 3.72% in the ACDF group and 3.73% in the MIS-PCF group. A random-effects model meta-analysis was carried out which failed to show a statistically significant difference in the complication rate between the two procedures (OR .91; 95% CI 0.13, 6.43;  $P = .92$ ,  $I^2 = 59\%$ ) (Figure 3).

Five studies compared postoperative reoperation and found the frequency to range between 0% and 5.7% and 0% and 14.3% for ACDF and MIS-PCF, respectively (Table 2).<sup>53-57</sup> Of note Mansfield et al.<sup>54</sup> reported two reoperations following ACDF, one of which was a lumbar laminectomy which was not included for the purpose of this analysis. Lin et al.<sup>57</sup> was the only study to find the reoperation rate to be significantly different with a higher reoperation rate in the MIS-PCF group. Of the studies that met inclusion, 54% of the reoperations following ACDF involved the adjacent level compared to 38% following MIS-PCF. The total reoperation rate was 3.5% in the ACDF group and 5.4% in the MIS-PCF group. A random-effects model meta-analysis was carried out which failed to show a statistically significant difference in the reoperation rate between the two procedures (OR .66; 95% CI 0.33, 1.33;  $P = .25$ ,  $I^2 = 0$ ) (Figure 4).

### MIS-PCF Compared to TDA

Two studies were included that met inclusion criteria and directly compared outcomes between patients undergoing MIS-PCF and TDA (Table 3).<sup>57,58</sup> Both studies were retrospective cohort series. Kim et al.<sup>58</sup> 2017 included 17 patients

who underwent TDA with a Prestige LP cervical disc (Medtronic Sofamor Danek, Memphis, TN) and compared outcomes to 18 patients who underwent microscopic MIS-PCF with a tubular retractor system approach. In addition to the 21 patients previously mentioned who underwent MIS-PCF, Lin et al.<sup>57</sup> included 21 patients who underwent TDA. Patients undergoing TDA in Lin et al.<sup>57</sup> were significantly younger with a mean age of 41.9 compared to a mean age of 53.4 in the MIS-PCF group. All patients were treated for cervical radiculopathy without myelopathy. Both studies specified that all patients presented preoperatively with lateral disc herniations. Overall 38 patients were included in the TDA group and 39 in the MIS-PCF group.

Both included studies compared operative/hospital admission metrics (Table 4). Operative time ranged from 90.3 to 106.7 minutes in the TDA group compared to 77.4 to 93.9 minutes in the MIS-PCF group.<sup>57,58</sup> The relationship was statistically significant with a shorter mean operative time in the MIS-PCF group in Kim et al. 2017.<sup>58</sup> Mean postoperative length of stay ranged from 103.2 to 165.6 hours in the TDA group and 93.6 to 98.4 hours in the MIS-PCF group. Kim et al.<sup>58</sup> 2017 also found the relationship to be statistically significant with a shorter postoperative length of stay in the MIS-PCF group.

The complication rate ranged from 23.5 to 28.6% in the TDA group and 0 to 14.3% in the MIS-PCF group (Table 4).<sup>57,58</sup> Kim et al. 2017 found the relationship to be statistically significant with a decreased complication rate with MIS-PCF. Of patients who experienced a complication after TDA the most common reported cause was heterotopic ossification (40% of total complications) followed by hoarseness (20% of total complications) and dysphagia (20% of total complications). The overall complication rate was 26.3% in the TDA group compared to 7.7% in the MIS-PCF group. The rate of reoperation ranged from 0 to 4.8% in the TDA group and 5.6 to 14.3% in the MIS-PCF group with neither studying finding the difference to be statistically significant (Table 4).<sup>57,58</sup> In the TDA group only one patient underwent reoperation which was done at the index level. In the MIS-PCF group 4 patients underwent reoperation of which one (25%) involved an adjacent level. The overall reoperation rates were 2.6% in the TDA group and 10.2% in the MIS-PCF group.

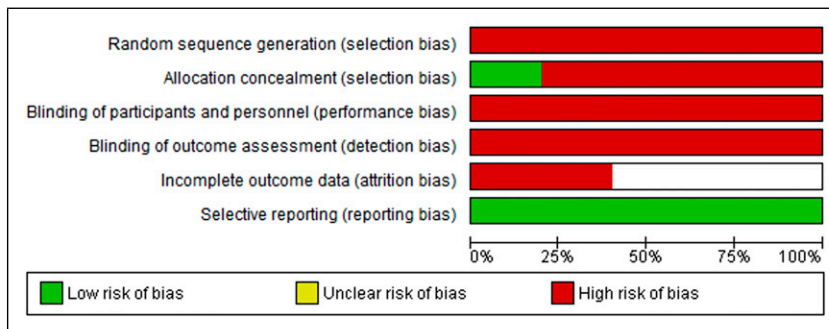
### Discussion

Since first being described in 2000, minimally invasive posterior cervical foraminotomy has gained popularity as a minimally invasive motion preserving treatment for cervical radiculopathy.<sup>3,4</sup> There are few studies that have been done directly comparing outcomes following minimally invasive posterior cervical foraminotomy and open posterior cervical foraminotomy.<sup>6,28,60-62</sup> Only one previous meta-analysis has evaluated directly comparative studies which found a trend towards decreased hospital length of stay and decreased postoperative analgesic usage following MIS-PCF.<sup>63</sup> Five studies have directly compared operative time between patients

**Table 1.** Studies Included in Quantitative Synthesis Directly Comparing MIS-PCF to ACDF.

Study	Study type	Level of evidence	Intervention (# of patients)	Mean age (years)	Mean follow-up (months)
Ruetten et al, 2008 <sup>53</sup>	RCT	II	ACDF (84) MIS-PCF (91)	NR NR	24 24
Mansfield et al, 2014 <sup>54</sup>	RCS	III	ACDF (76) MIS-PCF (21)	49 49	NR NR
Young et al, 2015 <sup>55</sup>	RCS	III	ACDF (268) MIS-PCF (112)	47.4 50.2	141.6 81.6
Dunn et al, 2018 <sup>56</sup>	RCS	III	ACDF (210) MIS-PCF (49)	49.9 49	44.9 42.9
Lin et al, 2019 <sup>57</sup>	RCS	III	ACDF (55) MIS-PCF (21)	52.5 53.4	39.5 35.9

Abbreviations: RCT, randomized controlled trial; RCS, retrospective cohort series; NR, not reported; MIS, minimally invasive surgery; ACDF, anterior cervical discectomy and fusion; PCF, posterior cervical fusion.



**Figure 2.** A graphic representation of risk of bias for each included study.

**Table 2.** Comparison of Outcomes Following MIS-PCF and ACDF.

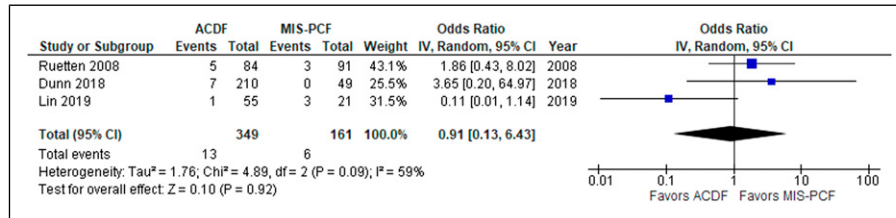
Study	Intervention (# of patients)	Mean operative time (minutes)	Mean postoperative length of stay (hours)	Complication rate (%)	Reoperation rate (%)
Ruetten et al, 2008 <sup>53</sup>	ACDF (84) MIS-PCF (91)	68* 28*	NR NR	6.0 3.3	4.7 6.7
Mansfield et al, 2014 <sup>54</sup>	ACDF (76) MIS-PCF (21)	NR NR	33.84* 13.68*	NR NR	1.32 0
Young et al, 2015 <sup>55</sup>	ACDF (268) MIS-PCF (112)	NR NR	NR NR	NR NR	2.6 2.7
Dunn et al, 2018 <sup>56</sup>	ACDF (210) MIS-PCF (49)	NR NR	NR NR	3.3 0	5.7 8.2
Lin et al, 2019 <sup>57</sup>	ACDF (55) MIS-PCF (21)	97.8 93.9	112.8 93.6	1.8* 14.3*	0* 14.3*

Abbreviations: NR, = not reported; MIS, minimally invasive surgery; ACDF, anterior cervical discectomy and fusion; PCF, posterior cervical fusion. \*Statistically significant difference ( $P < .05$ ).

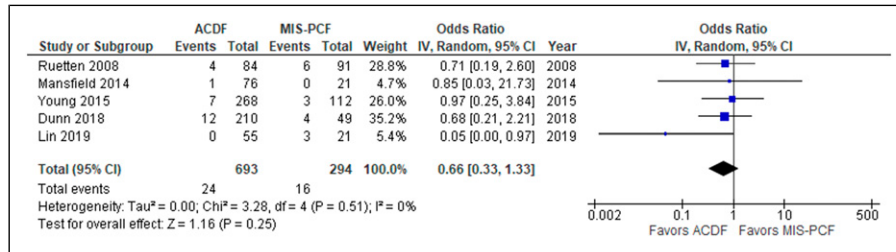
undergoing MIS-PCF and open PCF with one study finding the operative time to be significantly increased in the open group and one study finding the operative time to be significantly increased in the MIS group. Four previous studies have directly compared the rate of complications with MIS-PCF and open PCF and none of them have shown a significant difference. There have been no significant studies that directly compared the rate of reoperation.<sup>63</sup> There is, therefore, relative parity between open and MIS-PCF in terms of operative time, postoperative length of stay, and the rate of complications and reoperations. In this review, studies including open posterior foraminotomies within a treatment cohort were excluded. This

was done in an attempt to limit the heterogeneity of procedure types within the posterior cervical foraminotomy cohort.

The indications for MIS-PCF, ACDF, and TDA are not identical as ACDF and TDA can be used in the treatment of bilateral foraminal or central canal pathology. All three procedures, however, are indicated for the treatment of lateral disc and foraminal pathology. There has been a lack of studies directly comparing MIS-PCF techniques to ACDF and TDA and even fewer comprehensive systematic reviews and meta-analyses.<sup>64-66</sup> This study includes a systematic review of four studies that directly compare MIS-PCF to ACDF, one study that directly compares MIS-PCF to TDA, and one study that



**Figure 3.** Forest plot comparing complications after ACDF (anterior cervical discectomy and fusion) and MIS-PCF (minimally invasive posterior cervical foraminotomy); IV (inverse variance), CI (confidence interval), df (degrees of freedom).



**Figure 4.** Forest plot comparing reoperations after ACDF (anterior cervical discectomy and fusion) and MIS-PCF (minimally invasive posterior cervical foraminotomy); IV (inverse variance), CI (confidence interval), df (degrees of freedom).

compares MIS-PCF to both ACDF and TDA. There was significant heterogeneity in the minimally invasive method that was employed across included studies, however, given the rarity of studies directly comparing MIS-PCF to ACDF or TDA all minimally invasive techniques were grouped together. All studies that were included in analysis excluded patients with cervical myelopathy.

There is no clear superiority between MIS-PCF and ACDF/TDA in terms of operative time. Of the studies that met inclusion criteria, two compared mean operative time with MIS-PCF and ACDF and two compared operative time with MIS-PCF and TDA. Ruetten et al. and Kim et al. 2017 both found significantly decreased operative time in the MIS-PCF group as compared to ACDF and TDA, respectively.<sup>53,58</sup> Each study included a different MIS-PCF technique with Ruetten et al. favoring a percutaneous/full-endoscopic technique and Kim et al. favoring a microscopic tubular retractor technique. Mok et al.,<sup>67</sup> a 2019 study utilizing data from the National Surgical Quality Improvement Program (NSQIP) from 2010 to 2016, found posterior cervical foraminotomy to have a significantly decreased operative time when compared to TDA and ACDF. The study further showed that the average operative time for posterior cervical foraminotomy decreased over consecutive study intervals. Compared to the anterior approach for ACDF and TDA, MIS-PCF is a more recently developed surgical approach. Operative times may continue to decrease for MIS-PCF as surgeons become more comfortable with the technique.

This systematic review did not definitively show that patients following MIS-PCF have decreased postoperative length of stay. Two studies each compared postoperative length of stay with MIS-PCF and ACDF and with MIS-PCF and TDA. Mansfield et al. and Kim et al. 2017 both found the

relationship to be statistically significant with shorter postoperative stay after MIS-PCF.<sup>54,58</sup> There was significant variation in the postoperative length of stay after MIS-PCF as it ranged from 13.68 to 98.4 hours across all studies. There is a current trend to perform all three procedures in an outpatient setting in order to decrease costs associated with admission and inpatient care. Studies such as Helseth et al.<sup>52</sup> have shown that patients can be discharged on the day of surgery following MIS-PCF and ACDF without a compromise to safety. The concern of discharging a patient after an anterior neck procedure is higher than following a posterior procedure as anterior procedures have the risk of causing hematomas which can be slow to accumulate, however, acutely life threatening. As minimally invasive posterior cervical foraminotomy is already routinely performed in an outpatient setting with same day discharge the actual average postoperative length of stay is likely much shorter than in the above studies.<sup>68</sup> Inclusion of more patients across more centers would likely show a statistically significant decrease in the postoperative stay after MIS-PCF compared to TDA and ACDF. Witiw et al.,<sup>69</sup> a 2018 study using the MarketScan database (IBM, Armonk, NY), found patients following posterior cervical foraminotomy spent less time admitted to the hospital after surgery and were more likely to be discharged on the day of surgery compared to patients after ACDF.

By avoiding the anterior neck approach, MIS-PCF should limit the complications associated with ACDF and TDA, however, that was not shown by this systematic review and meta-analysis. Of the studies that met inclusion criteria, three compared complication rates between MIS-PCF and ACDF and two compared complication rates between MIS-PCF and TDA. Lin et al. found a statistically significant increase in the

**Table 3.** Studies Included in Quantitative Synthesis Directly Comparing MIS-PCF to TDA.

Study	Study type	Level of evidence	Intervention (# of patients)	Mean age (years)	Mean follow-up (months)
Kim et al, 2017 <sup>58</sup>	RCS	III	TDA (17) MIS-PCF (18)	42.1 42.8	82.5 84.1
Lin et al, 2019 <sup>57</sup>	RCS	III	TDA (21) MIS- PCF (21)	41.9* 53.4*	38.7 35.9

Abbreviations: RCS, retrospective cohort series; MIS, minimally invasive surgery; TDA, total disc arthroplasty; PCF, posterior cervical fusion.

\*Statistically significant difference ( $P < .05$ ).

**Table 4.** Comparison of Outcomes Following MIS-PCF and TDA.

Study	Intervention (# of patients)	Mean operative time (minutes)	Mean postoperative length of stay (hours)	Complication rate (%)	Reoperation rate (%)
Kim et al, 2017 <sup>58</sup>	TDA (17) MIS-PCF (18)	90.3* 77.4*	165.6* 98.4*	23.5* 0*	0 5.6
Lin et al, 2019 <sup>57</sup>	TDA (21) MIS- PCF (21)	106.7 93.9	103.2 93.6	28.6 14.3	4.8 14.3

Abbreviations: RCS, retrospective cohort series; MIS, minimally invasive surgery; TDA, total disc arthroplasty; PCF, posterior cervical fusion.

\*Statistically significant difference ( $P < .05$ ).

rate of complications after MIS-PCF as compared to ACDF, however, unlike the other included studies, did not include a description of what the complications were following MIS-PCF. Pooled analysis did not show a statistically significant difference in complication rates between the two procedures. As for MIS-PCF in comparison to TDA, one of two studies found a statistically significant increase in complication rate after MIS-PCF.<sup>58</sup> A meta-analysis was not performed as only two studies met inclusion criteria.

Two previous meta-analyses have shown similar results. Liu et al.<sup>65</sup> failed to find a statistically significant difference in complication rates comparing posterior cervical foraminotomy and ACDF. The study, however, did not exclusively compare minimally invasive posterior cervical foraminotomies and included multiple studies that were excluded from this meta-analysis. Sahai et al., a 2019 meta-analysis, used non-comparative case series to compare outcomes following MIS-PCF to historical ACDF controls and failed to find a statistical difference in the rate of complications. Sahai et al. was also limited by an open foraminotomy series, which was excluded from this study, being included in the minimally invasive group.<sup>36,56,66</sup>

Five studies compared the rate of reoperation after ACDF and MIS-PCF. Only one study, Lin et al. found the difference between the two to be statistically significant with an increased rate of reoperation after MIS-PCF. This was not demonstrated in pooled analysis. Two studies were included that compared reoperation after MIS-PCF and TDA with neither study finding a statistically significant difference.<sup>57,58</sup> Given small sample size, both studies were likely insufficiently powered to detect a significant difference in the rate of reoperation.

Given the minimally invasive and motion preserving nature of MIS-PCF one would expect for it to have a decreased risk of reoperation compared to ACDF. As expected, the proportion

of patients undergoing MIS-PCF who underwent reoperation were more likely to have revision at the index-level and less likely to have surgery at an adjacent level, whereas patients undergoing reoperation after ACDF were more likely to have surgery involving an adjacent level. Increased index-level reoperation after MIS-PCF may be related to poor decompression of the exiting nerve root at the time of initial surgery. As previously stated, MIS-PCF is a fairly new procedure with a significant learning curve; the rate of index-level reoperation may decrease as surgeons become more comfortable with the procedure. The failure to identify a statistically significant difference in the rate of reoperations is also likely related to the time course of this study. Only one study comparing outcomes following MIS-PCF and ACDF had follow-up greater than four years. ACDF case series with long follow-up have shown that rates of adjacent segment disease increase each year after surgery and can reach as high as 25% at 10 years.<sup>10,70-72</sup> A recent meta-analysis comparing outcomes following TDA and ACDF found that the superiority of TDA over ACDF in risk of adjacent-level surgery only became significant after 4 years of follow-up.<sup>11</sup> Future studies with longer follow-up intervals may show that MIS-PCF has a decreased reoperation rate compared to ACDF secondary to a decreased risk of adjacent-level operations.

### Limitations

There are several limitations to this study. Following systematic review only 6 studies were included that met inclusion/exclusion criteria. Although all studies were directly comparative in nature, outcomes of interest were not included in each study which greatly limited the ability to perform meta-analyses. Follow-up time and cohort size were additionally limited and decreased the ability to define several statistically

significant relationships. There was heterogeneity with regard to the MIS-PCF technique that was employed across studies. The majority of studies that were included in analysis were graded as class III in terms of level of evidence. All studies that compared ACDF to MIS-PCF were further characterized as having a high risk of bias. A further limitation of the study is that only four of the six studies exclusively included patients with lateral stenosis.

## Conclusions

This study, to the best of our knowledge, is the first systematic review and meta-analysis to analyze studies that directly compare MIS-PCF and ACDF and MIS-PCF and TDA. Based on the limited number of included studies, there is no clear superiority between MIS-PCF and ACDF/TDA in terms of operative time, postoperative length of stay, the rate of complications or the rate of reoperations. Further studies with increased follow-up intervals >48 months, and higher sample sizes are necessary to determine the true superiority of MIS-PCF and anterior neck approaches in treatment of lateral disc and foraminal pathology.

## Declaration of Conflicting Interests

The author(s) declared no potential conflicts of interest with respect to the research, authorship, and/or publication of this article.

## Funding

The author(s) received no financial support for the research, authorship, and/or publication of this article.

## Author's Note

Portions of this paper have been previously presented at AANS/CNS Joint Section Spine Summit, 2020, as an oral presentation, and will be presented at Global Spine Congress, 2021, as a poster presentation

## ORCID iD

Andrew Platt  <https://orcid.org/0000-0002-2514-2705>

## References

- Iyer S, Kim HJ. Cervical radiculopathy. *Curr Rev Musculoskelet Med.* 2016;9(3):272-280.
- Dodwad SJ, Dodwad SN, Prasarn ML, Savage JW, Patel AA, Hsu WK. Posterior cervical foraminotomy: indications, technique, and outcomes. *Clin Spine Surg.* 2016;29(5):177-185.
- Burke TG, Caputy A. Microendoscopic posterior cervical foraminotomy: a cadaveric model and clinical application for cervical radiculopathy. *J Neurosurg.* 2000;93(suppl 1):126-129.
- Roh SW, Kim DH, Cardoso AC, Fessler RG. Endoscopic foraminotomy using MED system in cadaveric specimens. *Spine.* 2000;25(2):260-264.
- Adamson TE. Microendoscopic posterior cervical laminoforaminotomy for unilateral radiculopathy: results of a new technique in 100 cases. *J Neurosurg.* 2001;95(suppl 1):51-57.
- Fessler RG, Khoo LT. Minimally invasive cervical microendoscopic foraminotomy: an initial clinical experience. *Neurosurgery.* 2002;51(suppl 2):S37-S45.
- Hilton DL Jr. Minimally invasive tubular access for posterior cervical foraminotomy with three-dimensional microscopic visualization and localization with anterior/posterior imaging. *Spine J: Official Journal of the North American Spine Society.* 2007;7(2):154-158.
- Ruetten S, Komp M, Merk H, Godolias G. A new full-endoscopic technique for cervical posterior foraminotomy in the treatment of lateral disc herniations using 6.9-mm endoscopes: prospective 2-year results of 87 patients. *Minimally invasive neurosurgery: MIN.* 2007;50(4):219-226.
- Foster MT, Carleton-Bland NP, Lee MK, Jackson R, Clark SR, Wilby MJ. Comparison of clinical outcomes in anterior cervical discectomy versus foraminotomy for brachialgia. *Br J Neurosurg.* 2019;33(1):3-7.
- Hilibrand AS, Carlson GD, Palumbo MA, Jones PK, Bohlman HH. Radiculopathy and myelopathy at segments adjacent to the site of a previous anterior cervical arthrodesis. *J Bone Jt Surg Am Vol.* 1999;81(4):519-528.
- Badhiwala JH, Platt A, Witiw CD, Traynelis VC. Cervical disc arthroplasty versus anterior cervical discectomy and fusion: a meta-analysis of rates of adjacent-level surgery to 7-year follow-up. *J Spine Surg.* 2020;6(1):217-232.
- Moher D, Liberati A, Tetzlaff J, Altman DG. Preferred reporting items for systematic reviews and meta-analyses: the PRISMA statement. *PLoS Med.* 2009;6(7):e1000097.
- NASS Authors. *Levels of Evidence for Primary Research Question as Adopted by the North American Spine Society North American Spine Society.* <https://www.spine.org/Portals/0/Assets/Downloads/ResearchClinicalCare/LevelsofEvidence.pdf>. Published 2005. Updated 2005. Accessed 10/24/2020, 2020.
- Lee U, Kim CH, Chung CK, et al. The recovery of motor strength after posterior percutaneous endoscopic cervical foraminotomy and discectomy. *World neurosurgery.* 2018;115:e532-e538.
- Youn MS, Shon MH, Seong YJ, Shin JK, Goh TS, Lee JS. Clinical and radiological outcomes of two-level endoscopic posterior cervical foraminotomy. *Eur Spine J.* 2017;26(9):2450-2458.
- Bydon M, Mathios D, Macki M, et al. Long-term patient outcomes after posterior cervical foraminotomy: an analysis of 151 cases. *J Neurosurg Spine.* 2014;21(5):727-731.
- Skovrlj B, Gologorsky Y, Haque R, Fessler RG, Qureshi SA. Complications, outcomes, and need for fusion after minimally invasive posterior cervical foraminotomy and microdiscectomy. *Spine J: Official Journal of the North American Spine Society.* 2014;14(10):2405-2411.
- Caglar YS, Bozkurt M, Kahilogullari G, et al. Keyhole approach for posterior cervical discectomy: experience on 84 patients. *Minimally invasive neurosurgery: MIN.* 2007;50(1):7-11.
- Holly LT, Moftakhar P, Khoo LT, Wang JC, Shamie N. Minimally invasive 2-level posterior cervical foraminotomy: preliminary clinical results. *J Spinal Disord Tech.* 2007;20(1):20-24.



20. Papavero L, Kothe R. Minimally invasive posterior cervical foraminotomy for treatment of radiculopathy: an effective, time-tested, and cost-efficient motion-preservation technique. *Oper Orthop Traumatol*. 2018;30(1):36-45.
21. Gerard CS, O'Toole JE. Current techniques in the management of cervical myelopathy and radiculopathy. *Neurosurg Clin N Am*. 2014;25(2):261-270.
22. Takebayashi T, Yoshimoto M, Ida K, Tsuda H, Terashima Y, Yamashita T. Minimum invasive posterior decompression for cervical spondylotic amyotrophy. *J Orthop Sci*. 2013;18(2):205-207.
23. Witzmann A, Hejazi N, Krasznai L. Posterior cervical foraminotomy. A follow-up study of 67 surgically treated patients with compressive radiculopathy. *Neurosurg Rev*. 2000;23(4):213-217.
24. Gu BS, Park JH, Seong HY, Jung SK, Roh SW. Feasibility of posterior cervical foraminotomy in cervical foraminal stenosis: prediction of surgical outcomes by the foraminal shape on preoperative computed tomography. *Spine*. 2017;42(5):E267-e271.
25. Bhatia S, Brooks NP. Posterior endoscopic cervical foraminotomy. *Neurosurg Clin*. 2020;31(1):9-16.
26. Won SJ, Kim CH, Chung CK, et al. Clinical outcomes of single-level posterior percutaneous endoscopic cervical foraminotomy for patients with less cervical lordosis. *J Minimally Invasive Spine Sur Tech*. 2016;1(1):11-17.
27. Lawton CD, Smith ZA, Lam SK, Habib A, Wong RH, Fessler RG. Clinical outcomes of microendoscopic foraminotomy and decompression in the cervical spine. *World neurosurgery*. 2014;81(2):422-427.
28. Kim KT, Kim YB. Comparison between open procedure and tubular retractor assisted procedure for cervical radiculopathy: results of a randomized controlled study. *J Korean Med Sci*. 2009;24(4):649-653.
29. Oertel JM, Philipps M, Burkhardt BW. Endoscopic posterior cervical foraminotomy as a treatment for osseous foraminal stenosis. *World neurosurgery*. 2016;91:50-57.
30. Burkhardt BW, Muller S, Oertel JM. Influence of prior cervical surgery on surgical outcome of endoscopic posterior cervical foraminotomy for osseous foraminal stenosis. *World neurosurgery*. 2016;95:14-21.
31. Kwon Y-J. Long-term clinical and radiologic outcomes of minimally invasive posterior cervical. *Foraminotomy*. 2014;56(3):224.
32. Kim CH, Kim KT, Chung CK, et al. Minimally invasive cervical foraminotomy and discectomy for laterally located soft disk herniation. *Euro Spine J*. 2015;24:3005-3012.
33. Peto I, Scheiwe C, Kogias E, Hubbe U. Minimally invasive posterior cervical foraminotomy: Freiburg experience with 34 patients. *Clin Spine Surg*. 2017;30(10):E1419-e1425.
34. Branch BC, Hilton DL Jr, Watts C. Minimally invasive tubular access for posterior cervical foraminotomy. *Surg Neurol Int*. 2015;6:81.
35. Clarke MJ, Ecker RD, Krauss WE, McClelland RL, Dekutoski MB. Same-segment and adjacent-segment disease following posterior cervical foraminotomy. *J Neurosurg Spine*. 2007;6(1):5-9.
36. Jagannathan J, Sherman JH, Szabo T, Shaffrey CI, Jane JA. The posterior cervical foraminotomy in the treatment of cervical disc/osteophyte disease: a single-surgeon experience with a minimum of 5 years' clinical and radiographic follow-up. *J Neurosurg Spine*. 2009;10(4):347-356.
37. Cho TG, Kim YB, Park SW. Long term effect on adjacent segment motion after posterior cervical foraminotomy. *Korean J Spine*. 2014;11(1):1-6.
38. Lubelski D, Healy AT, Silverstein MP, et al. Reoperation rates after anterior cervical discectomy and fusion versus posterior cervical foraminotomy: a propensity-matched analysis. *Spine J: Official Journal of the North American Spine Society*. 2015;15(6):1277-1283.
39. Selvanathan SK, Beagrie C, Thomson S, et al. Anterior cervical discectomy and fusion versus posterior cervical foraminotomy in the treatment of brachialgia: the Leeds spinal unit experience (2008-2013). *Acta neurochirurgica*. 2015;157(9):1595-1600.
40. Alvin MD, Lubelski D, Abdullah KG, Whitmore RG, Benz EC, Mroz TE. Cost-utility analysis of anterior cervical discectomy and fusion with plating (acdfp) versus posterior cervical foraminotomy (pcf) for patients with single-level cervical radiculopathy at 1-year follow-up. *Clin Spine Surg*. 2016;29(2):E67-E72.
41. Ross DA, Ross MN. Diagnosis and treatment of c4 radiculopathy. *Spine*. 2016;41(23):1790-1794.
42. Bhaganagare AS, Nagesh SA, Shrihari BG, Naik V, Nagarjun MN, Pai BS. Management of cervical monoradiculopathy due to prolapsed intervertebral disc, an institutional experience. *J Craniovertebr Junction Spine*. 2017;8(2):132-135.
43. Mai HT, Chun DS, Schneider AD, Hecht AC, Maroon JC, Hsu WK. The difference in clinical outcomes after anterior cervical fusion, disk replacement, and foraminotomy in professional athletes. *Clin Spine Surg*. 2018;31(1):E80-e84.
44. Siller S, Kasem R, Witt TN, Tonn JC, Zausinger S. Painless motor radiculopathy of the cervical spine: clinical and radiological characteristics and long-term outcomes after operative decompression. *J Neurosurg Spine*. 2018;28(6):621-629.
45. Macdowall A, Heary RF, Holy M, Lindhagen L, Olerud C. Posterior foraminotomy versus anterior decompression and fusion in patients with cervical degenerative disc disease with radiculopathy: up to 5 years of outcome from the national Swedish Spine Register. *J Neurosurg Spine*. 2019:1-9.
46. Wirth FP, Dowd GC, Sanders HF, Wirth C. Cervical discectomy. A prospective analysis of three operative techniques. *Surg Neurol*. 2000;53(4):340-346; discussion 346-348.
47. Herkowitz HN, Kurz LT, Overholt DP. Surgical management of cervical soft disc herniation. A comparison between the anterior and posterior approach. *Spine*. 1990;15(10):1026-1030.
48. Tumialan LM, Ponton RP, Gluf WM. Management of unilateral cervical radiculopathy in the military: the cost effectiveness of posterior cervical foraminotomy compared with anterior cervical discectomy and fusion. *Neurosurg Focus*. 2010;28(5):E17.

49. Scholz T, Geiger MF, Mainz V, et al. Anterior cervical decompression and fusion or posterior foraminotomy for cervical radiculopathy: results of a single-center series. *J Neurol Surg Cent Eur Neurosurg*. 2018;79(3):211-217.
50. Korinth MC, Kruger A, Oertel MF, Gilsbach JM. Posterior foraminotomy or anterior discectomy with polymethyl methacrylate interbody stabilization for cervical soft disc disease: results in 292 patients with monoradiculopathy. *Spine*. 2006; 31(11):1207-1214; discussion 1215-1206.
51. Kim CH, Park TH, Chung CK, Kim KT, Choi YH, Chung SW. Changes in cervical motion after cervical spinal motion preservation surgery. *Acta neurochirurgica*. 2018;160(2):397-404.
52. Helseth O, Lied B, Heskestad B, Ekseth K, Helseth E. Retrospective single-centre series of 1300 consecutive cases of outpatient cervical spine surgery: complications, hospital readmissions, and reoperations. *Br J Neurosurg*. 2019;33(6):613-619.
53. Ruetten S, Komp M, Merk H, Godolias G. Full-endoscopic cervical posterior foraminotomy for the operation of lateral disc herniations using 5.9-mm endoscopes: a prospective, randomized, controlled study. *Spine*. 2008;33(9):940-948.
54. Mansfield HE, Canar WJ, Gerard CS, O'Toole JE. Single-level anterior cervical discectomy and fusion versus minimally invasive posterior cervical foraminotomy for patients with cervical radiculopathy: a cost analysis. *Neurosurg Focus*. 2014;37(5):E9.
55. Young RM, Leiphart JW, Shields DC, Caputy AJ. Anterior cervical fusion versus minimally invasive posterior keyhole decompression for cervical radiculopathy. 2015;2(4):169-176.
56. Dunn C, Moore J, Sahai N, et al. Minimally invasive posterior cervical foraminotomy with tubes to prevent undesired fusion: a long-term follow-up study. *J Neurosurg Spine*. 2018;29(4): 358-364.
57. Lin GX, Rui G, Sharma S, Kotheeranurak V, Suen TK, Kim JS. Does the neck pain, function, or range of motion differ after anterior cervical fusion, cervical disc replacement, and posterior cervical foraminotomy? *World neurosurgery*. 2019;129:e485-e493.
58. Kim KT, Cho DC, Sung JK, Kim YB, Kim DH. Comparative analysis between total disc replacement and posterior foraminotomy for posterolateral soft disc herniation with unilateral radiculopathy: clinical and biomechanical results of a minimum 5 years follow-up. *J Korean Neurosurg Soc*. 2017;60(1):30-39.
59. Andrew Platt JEOT. *Personal Communication between Andrew Platt*. John E. O'Toole.; 2020.
60. Winder MJ, Thomas KC. Minimally invasive versus open approach for cervical laminoforaminotomy. *Can J Neurol Sci*. 2011;38(2):262-267.
61. Uehara M, Takahashi J, Kuraishi S, et al. Mini open foraminotomy for cervical radiculopathy: a comparison of large tubular and trimline retractors. *Asian spine journal*. 2015;9(4):548.
62. Eicker SO, Steiger HJ, El-Kathib M. A transtubular microsurgical approach to treat lateral cervical disc herniation. *World neurosurgery*. 2016;88:503-509.
63. Platt A, Gerard CS, O'Toole JE. Comparison of outcomes following minimally invasive and open posterior cervical foraminotomy: description of minimally invasive technique and review of literature. *J Spine Surg*. 2020;6(1):243-251.
64. Dohrmann GJ, Hsieh JC. Long-term results of anterior versus posterior operations for herniated cervical discs: analysis of 6,000 patients. *Med Princ Pract*. 2014;23(1):70-73.
65. Liu WJ, Hu L, Chou PH, Wang JW, Kan WS. Comparison of anterior cervical discectomy and fusion versus posterior cervical foraminotomy in the treatment of cervical radiculopathy: a systematic review. *Orthop Surg*. 2016;8(4):425-431.
66. Sahai N, Changoor S, Dunn CJ, et al. Minimally invasive posterior cervical foraminotomy as an alternative to anterior cervical discectomy and fusion for unilateral cervical radiculopathy: a systematic review and meta-analysis. *Spine*. 2019; 44(24):1731-1739.
67. Mok JK, Sheha ED, Samuel AM, et al. Evaluation of current trends in treatment of single-level cervical radiculopathy. *Clin Spine Surg*. 2019;32(5):E241-e245.
68. Gerard CS, O'Toole JE. Current techniques in the management of cervical myelopathy and radiculopathy. *Neurosurg Clin*. 2014;25(2):261-270.
69. Witiw CD, Smielliaskas F, O'Toole JE, Fehlings MG, Fessler RG. Comparison of anterior cervical discectomy and fusion to posterior cervical foraminotomy for cervical radiculopathy: utilization, costs, and adverse events 2003 to 2014. *Neurosurgery*. 2019;84(2):413-420.
70. Hilibrand AS, Robbins M. Adjacent segment degeneration and adjacent segment disease: the consequences of spinal fusion?. *Spine J: Official Journal of the North American Spine Society*. 2004;4(suppl 6):190s-194s.
71. Bohlman HH, Emery SE, Goodfellow DB, Jones PK. Robinson anterior cervical discectomy and arthrodesis for cervical radiculopathy. Long-term follow-up of one hundred and twenty-two patients. *J Bone Jt Surg Am Vol*. 1993;75(9): 1298-1307.
72. Gore DR, Sepic SB. Anterior cervical fusion for degenerated or protruded discs. A review of one hundred forty-six patients. *Spine*. 1984;9(7):667-671.